

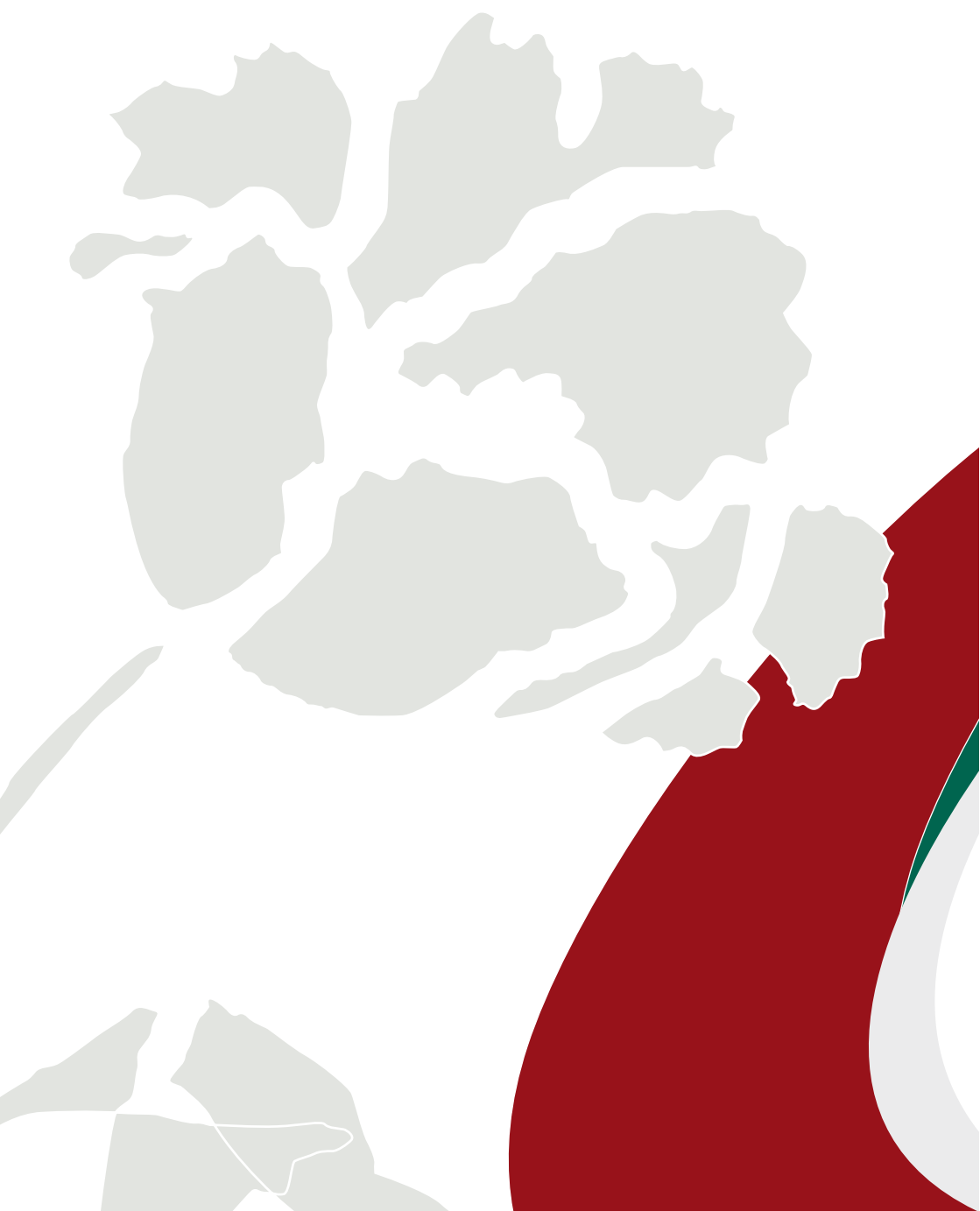

**EUPO 2009**

June 12-13, 2009 • Amsterdam, The Netherlands

**CORNEA, CONJUNCTIVA  
and REFRACTIVE SURGERY**

Course book

[www.eupo.eu](http://www.eupo.eu)



# **EUPO 2009**

June 12-13, 2009 • Amsterdam, The Netherlands

## **CORNEA, CONJUNCTIVA and REFRACTIVE SURGERY**

Course book

Course directors: Prof. Dr T.Hoang-Xuan  
Prof. Dr F.E. Kruse  
Prof. Dr G. van Rij  
Prof. Dr B. Seitz



## EUPO Board



**Gabriel van Rij**  
President



**Werner Spileers**  
Secretary General  
Treasurer

**EUPO Office: [www.eupo.eu](http://www.eupo.eu)**

# Welcome address

*Gabriel van Rij*

---

It is my pleasure to welcome you to the 2009 annual Course of the European Professors of Ophthalmology (EUPO) on Cornea, Conjunctiva and Refractive Surgery. We are delighted that so many distinguished speakers, who are leaders in their field, accepted our invitation.

These invited lecturers come from Europe and from around the world.

The course follows a tradition established in 1988.

In 1988 the very first EUPO Course for residents was organized by Professor Deutman in Nijmegen.

After this course it was decided to organize a course once a year in different places in Europe.

Later it was decided that in the year of a congress of the European Society of Ophthalmology (SOE), the course would be part of the congress.

Most of the ophthalmology curriculum should be covered within a 4 year period in order to permit the residents to have an overview of theoretical knowledge during their residency period.

No EUPO Course would be complete without a great EUPO Party for participants and speakers, which traditionally reflects the flavor of the host city.

I welcome you to Amsterdam and thank you for making the EUPO Course 2009 a memorable event.

Gabriel van Rij, MD, PhD

President of EUPO



available on  
[www.eupo.eu](http://www.eupo.eu)

2006	2007	2008
Retina	Uveitis	Neuro-Ophthalmology and Strabismus

## The sequence of the EUPO courses

---

2009	Amsterdam (SOE)	Cornea, Conjunctiva and Refractive surgery
2008	Geneva	Neuro-ophthalmology and strabismus
2007	Vienna (SOE)	Glaucoma and uveitis
2006	Ghent	Retina
2005	Berlin (SOE)	Cornea
2004	Nijmegen	Neuro-ophthalmology and strabismus
2003	Madrid (SOE)	Glaucoma and uveitis
2002	Erlangen	Retina
2001	Istanbul (SOE)	Cornea
2000	Leuven	Neuro-ophthalmology and strabismus
1999	Stockholm (SOE)	Glaucoma and uveitis
1998	Amsterdam (ICO)	Chorioretina
1997	Budapest (SOE)	Cornea, conjunctiva, lids, orbit
1996	Athens	Neuro-ophthalmology and strabismus
1995	Milano (SOE)	Uveitis, lens, glaucoma
1994	Montpellier	Retina
1993	Santiago de Compostella	The external eye
1992	Brussels (SOE)	Neuro-ophthalmology and strabismus
1991	Torino	Uveitis, lens, glaucoma
1990	Bonn	Chorioretina
1989	Leuven	The external eye and orbit
1988	Nijmegen	

## EUPO Party

**Venue:** Strand Zuid Beach,  
located on the harbour  
side of the RAI,  
congress venue.

All participants attending the party  
will receive a ticket upon registration  
that they need to bring to the party  
in order to attend.



- 18:15 Welcome drink  
BBQ Buffet
- 20:30 DJ starts to play
- 22:15 Free Beverage assortment  
ends - bar open
- 23:30 Background music is played
- 24.00 Evening Ends



# PROGRAMME

**FRIDAY, June 12, 2009**

09:25 **Introduction**

G. van Rij - President & EUPO 2009 Course organizer

## **First morning session: morphology, anomalies and dystrophies**

---

Moderators: Berthold Seitz - Gabriel van Rij	Course	Page
09:30 <b>Corneal morphology</b> Luc Missotten, Belgium	1	13
10:00 <b>Corneal disorders in children and congenital anomalies of the cornea</b> Joaquim Murta, Portugal	2	17
10:30 <b>Landmarks and DD of differential diagnosis of corneal dystrophies</b> Walter Lisch, Germany	3	21
11:00 <b>Break</b>		

## **Second morning session: examination and inflammation**

---

Moderators: Friedrich Kruse - Thanh Hoang-Xuan	Course	Page
11:30 <b>Corneal examination techniques: pachymetry, OCT, topography and wavefront</b> Jack Holladay, USA	4	27
12:00 <b>Non inflammatory corneal pathology, Salzmann, Terrien</b> Murat Irkeç, Turkey	5	33
12:30 <b>Amniotic membrane and stem cell transplantation and its role in surface reconstruction</b> Friedrich Kruse, Germany	6	41
13:00 <b>Lunch</b>		



## FRIDAY, June 12, 2009

### First afternoon session: keratoplasty and keratoprosthesis

---

Moderators: Berthold Seitz - Friedrich Kruse	Course	Page
14:30 <b>Corneal transplantation: penetrating and lamellar keratoplasty</b> Berthold Seitz, Germany	7	45
15:00 <b>Corneal transplantation: immunology and angiogenesis</b> Claus Cursiefen, Germany	8	63
15:30 <b>Keratoprosthesis</b> Chris Liu, UK	9	95
16:00 <b>Break</b>		

### Second afternoon session: allergy, eye-lids, keratoconus

---

Moderators: John Dart - Thanh Hoang-Xuan	Course	Page
16:30 <b>Ocular allergy, AKC, Vernal and GPC</b> John Dart, UK	10	113
17:00 <b>Meibomian gland dysfunction, ocular rosacea</b> Thanh Hoang-Xuan, France	11	121
17:30 <b>Keratoconus and pellucid marginal degeneration: diagnosis and treatment including crosslinking</b> François Malecaze, France	12	123

**18:15 EUPO Party**

## SATURDAY, June 13, 2009

### Morning session: bacterial, viral and fungal keratitis

---

Moderators: Philippe Kesteleyn - Thanh Hoang-Xuan	Course	Page
08:15 <b>Bacterial keratitis</b> Joseph Frucht - Pery, Israel	13	125
08:45 <b>Herpes simplex infections and herpes zoster of the cornea</b> Lies Remeyer, The Netherlands	14	127
09:15 <b>Fungal and chlamydial infections</b> Philippe Kesteleyn, Belgium	15	139
09:45 <b>Break</b>		

### 10:15 Opening ceremony of the SOE Congress

11:45 <b>Break</b>		
13:15 <b>Keynote Lecture of European Congress of Ophthalmology</b> Marie José Tassignon		
14:00 <b>Break</b>		

### First afternoon session: inflammation, tumors, dry eye

---

Moderators: Reza Dana - Thanh Hoang-Xuan	Course	Page
14:30 <b>Role of inflammation in ocular surface disease</b> Reza Dana, USA	16	151
15:00 <b>Tumors of conjunctiva and cornea</b> Stefan Seregard, Sweden	17	153
15:30 <b>Dry eye and clinical disease of tear film, diagnosis and management</b> Christoffe Baudouin, France	18	157
16:00 <b>Break and exhibition visit</b>		

## SATURDAY, June 13, 2009

### Second afternoon session: Refractive surgery

---

	Moderators: Dimitri Azar - Joseph Frucht-Pery	Course	Page
16:30	<b>Present role of surface ablation &amp; PTK</b> Timo Tervo, Finland	19	159
17:00	<b>LASIK &amp; Microkeratome</b> Thomas Kohnen, Germany	20	167
17:30	<b>Quality of vision after refractive surgery</b> Dimitri Azar, USA	21	171



# Morphology of the cornea

| Luc Missotten, Belgium |

---

## Corneal epithelium

The basal cells of the epithelium originate in the stem cells near the limbus and migrate slowly over the basal lamina towards the centre of the corneal. They do not all migrate at the same speed. Fastest are those migrating downwards, second are those coming from the inferior limbus. Those coming from left and right are slowest. This may be due to a difference in temperature. The lines seen in cornea verticillata are high-water marks where the oldest cells end and shed the debris they accumulated during their journey.

While migrating the basal cells multiply, and the resulting daughter cells are pushed outwards and become wing cells. These flatten progressively and lose much of their organelles to become pancake-like superficial cells. These cells maintain on their surface the ridges and microvilli, which may have a function in stabilising the mucus in the tear film.

All corneal cells are firmly linked together by numerous interdigitations and tight junctions. They form an impermeable layer protecting the stroma from dehydration by water from the tear film. The basal cells adhere to the basal lamina covering the stroma, by means of hemidesmosomes. These are more sensitive to alcohol than desmosomes, this enables the Lasek surgeon to lose the epithelium from its base while the epithelial cells still cling together.

The superficial layers of the epithelium are under tension, pulling the surface flat and smoothing small irregularities of the stroma.

Numerous naked nerve endings penetrate from the stroma in the epithelium and meander between the basal and wing cells. There must be a constant rearrangement between the sessile nerves and the migrating epithelial cells.

## Corneal stroma

Its main components are collagen fibrils and a proteoglycan matrix. Collagen molecules, each about 1/3 the of a micron long, spontaneously aggregate in fibrils. In the cornea these collagen fibrils all have the same thickness: about 30 nanometers

or 1/30 the of a micron. This due to the influence of decorin and lumican, two proteoglycans of the corneal matrix. The apparent thickness as seen in electron-micrographs and other methods differs depending the fixation and observation methods used. Collagen fibrils are arranged in ribbons (called lamellae) of a few thousand fibrils, all parallel and stretching from limbus to limbus.

The fibrils are kept equidistant by the proteoglycan matrix. In electron micro graphs this matrix is usually not visible. Specific staining reveals rather unordered strands between the collagen fibrils. However one has to keep in mind that during fixation and embedding the cornea loses its perfect transparency. It is likely that the proteoglycan matrix in a normal cornea is better structured than it appears in histological section.

The difference in refracting index between collagen fibrils and the interfibrillar matrix (1,411 and 1,365) poses a problem. One would expect that Interference of the two components should result in translucent tissue such as the sclera, not a transparent cornea. Maurice proposed in 1957 that the transparency results from the uniform and small calibre of the fibrils and of their regular quasi crystalline spacing. Recent research suggests that the short-range spatial order seen in EM is sufficient to reduce the light scattering to normal transparency.

The superficial collagen fibrils are less orderly arranged but woven like a felt: Bowman's layer.

Between the collagen ribbons stromal cells can be found. They seem dormant, but they react to stimuli. For example abrasion of the epithelium provokes their disappearance in the superficial third of the stroma under the abraded area.

**The endothelium** is a monolayer of hexagonal cells 4 to 6 micron in height. At birth these cells have a diameter of about 20 micron and number about 2500 per mm<sup>2</sup>. In man they do not multiply. When a cell dies , the neighbouring cells become larger and fill the gap. In this way endothelial cells during life become larger and less numerous.

A cross-section shows that the lateral walls of the endothelial cells are extremely tortuous, so that the length of the intercellular path may be 10 times longer than the height of the cells. At the apical portion of the cells, facing the anterior chamber numerous tight junctions form an incomplete seal around the cells. This results in a leaky barrier separating the corneal stroma from the anterior chamber. An active mechanism transports water out of the cornea to keep it partially dehydrated and transparent, the leak provides metabolites to the corneal stroma.

**Descemet's membrane** is a secretion of the basal side of the endothelium. At birth it is about 3 micron thick and grows till about 10 micron in adulthood. In contrast to Bowman's layer, Descemet's membrane is not strongly attached to the stroma, and may be peeled off by trauma or surgery.

The curvature of the surface of the cornea is aspherical, the centre of a normal cornea has the steepest curvature, an important feature to reduce the spherical aberration of the optics of the eye.

*Luc Missotten*

*luc.missotten@uz.kuleuven.ac.be*





# Corneal disorders in children and congenital anomalies of the cornea

| Joaquim Murta, Portugal |

---

Corneal disease is still today the most common cause of blindness in the world. Diseases affecting the cornea and anterior segment in children differ little from diseases in adult with the exception of congenital and development abnormalities.

The initial 6 weeks, until the closure of the embryonic fissure, are the most critical period for ocular development. Arrest of development during this period leads to severe ocular anomalies and greatly impaired visual acuity (anophthalmia, congenital cystic eye, congenital aphakia, typical colobomas, ...).

**The congenital anomalies of the anterior segment** are present at birth, usually bilateral, but often asymmetrical. The etiology can be genetic, infectious, inflammatory, traumatic, toxic or a combination of these factors, which most often affect the normal ocular development between the sixth and sixteenth weeks of gestation, when differentiation of the anterior segment occurs. Different structures in the anterior segment are subject to common influences, so that development abnormalities of one component are often accompanied by abnormalities of others. The development anomalies of the anterior segment are often difficult to classify and new classifications were proposed.

However precise diagnosis is necessary in order to predict the natural history of the disease, to look for associated ocular and systemic abnormalities, to give genetic counselling and to initiate appropriate treatment. **Abnormalities in corneal size and shape:** Microcornea, Megalocornea, Keratoglobus, Cornea Plana; **Abnormalities in corneal development leading to a visually opaque cornea:** Sclerocornea, Peripheral Anterior Chamber Cleavage Abnormalities (Axenfeld's Anomaly, Axenfeld's Syndrome, Rieger's Anomaly, Rieger's Syndrome), Central Anterior Chamber Cleavage Abnormalities (Central posterior Keratoconus, Peters Anomaly), **Inborn Errors of Metabolism, Corneal Dystrophies** present at or shortly after birth (Congenital Hereditary Endothelial Dystrophy, Posterior Polymorphous Dystrophy, Congenital Hereditary Stromal Dystrophy, Posterior Amorphous Corneal Dystrophy), **Congenital Glaucoma** and **Epibulbar Tumors** (Dermoid, Osseous Choristomas) will be briefly described.

**Corneal manifestations of systemic diseases** (diseases of abnormal carbohydrate metabolism, diseases of abnormal protein metabolism, diseases of abnormal lipid

metabolism, avitaminosis, interstitial keratitis secondary to syphilis, tuberculosis and virus, Wilson's disease, Refsum's syndrome) and different forms of **atopic and vernal keratoconjunctivitis**, will be also showed.

**Keratoconus**, the most common ectatic corneal disease, appears in the early adolescent years and can progress in the late teens into the twenties. It may seen with other conditions as allergic disease, retinitis pigmentosa, Down, Alport or Marfan syndromes.

**Pediatric microbial keratitis** is a rare but potentially devastating disease. The condition is similar to adult but is often characterized by a more severe inflammatory response; herpes simplex and bacteria (*pseudomonas aeruginosa*, *staphylococcus aureus* and  $\alpha$ -hemolytic *streptococci*) are more common and fungi being less frequent.

**Ocular trauma**, second only to cataracts as the most common cause of visual impairment and the most frequent cause of unilateral blindness among children, and **child abuse** will be discussed.

The management of infants corneal opacities (team approach, preoperative examination and indications for keratoplasty) will be also discussed. Penetrating keratoplasty is indicated in children who have significant unilateral or bilateral corneal opacities that prevent visual development. Otherwise they would develop dense amblyopia. In cases of congenital corneal opacities, surgery should be performed within the first 3 months of life to reduce the degree of amblyopia. Poor prognostic factors include bilateral disease, concomitant infantile glaucoma, lensectomy and vitrectomy at the time of the surgery, previous graft failure, extensive goniosynechia and corneal vascularisation.

## **References:**

1. Stretton S, Gopinathan U and Willcox MD. Corneal ulceration in pediatric patients. A brief overview of progress in topical treatment. *Pediatr Drugs* 2002, 4(2):95-110.
2. Nischal KK. Congenital corneal opacities – a surgical approach to nomenclature and classification. *Eye* 2007, 21:1326-1337.
3. Peter RL, Rapuano CJ. Diseases of the cornea. In: Nelson LB (ed): *Harley's Pediatric Ophthalmology*, 4<sup>th</sup> Ed. WB Saunders Co, 1998; 215-257.
4. Velasquez A, Kim T. Development corneal anomalies of size and shape. In: Krachmer JH, Mannis MJ, Holland EJ, eds. *Cornea*. 2nd ed. Vol 1. Philadelphia: Elsevier Mosby; 2005:727-737.

5. *Clinical aspects of congenital anomalies of the cornea and sclera. In. External Disease and Cornea. Ed American Academy Ophthalmology 2007-2008: 285-302*
6. *Bonini S, Sacchetti M, Mantelli F and Lambiase A. Clinical grading of vernal keratoconjunctivitis review). Curr Opin Allergy Clin Immunol 2007, 7:436-441*
7. *Brophy M, Sinclair S, Hostetler SG and Xiang H. Pediatric eye injury-related hospitalizations in the United States. Pediatrics 2006, 117:e1263-e1271*
8. *Block RW, Palusci VJ. Child abuse pediatrics: a new pediatric subspecialty. J Pediatr 2006, 148:711-712.*
9. *Reidy J. Penetrating keratoplasty in infancy and early childhood. Cur Opinion Ophthalmol 2001, 12:258-261*
10. *Colby K. Changing times for pediatric keratoplasty. J AAPOS 2008, 12(3):223-224.*
11. *Chan AS, Colby K. Update on pediatric keratoplasty. Int Ophthalmol Clin 2008, 48 (2):25-33.*

**Joaquim Neto Murta, MD, PhD**  
**University Hospital Coimbra, Coimbra, Portugal**  
**[jmurta@netcabo.pt](mailto:jmurta@netcabo.pt)**



# Landmarks and DD of differential diagnosis of corneal dystrophies (CD)

| Walter Lisch, Germany |

---

The ophthalmologist is the first to examine and to diagnose a new patient with a probable CD at the slit-lamp. The presented table of landmarks is supposed to be a “bridge” for the ophthalmologist to precisely define the corneal opacities of a presumed CD. After this definition it’s possible to diagnose a solitary CD patient and to perform DD against systemic metabolic disorders with corneal involvement in more than 90% of cases. First we have some questions and statements:

## ***Why a CD patient consults an ophthalmological office?***

1. Vision
2. Pain, red eye, epiphora due to CD induced epithelial defects
3. Routine check
4. Refractive problems (myopia)
5. Familiar examination

## ***List of CD with the possibility of CD induced epithelial defects masquerading as bacterial or viral keratitis***

1. Epithelial basement CD
2. Subepithelial mucinous CD
3. Meesmann CD
4. Reis-Bücklers CD
5. Thiel-Behnke CD
6. Lattice CD
7. Granular CD, type I and II
8. Macular CD
9. Schnyder CD
10. Gelatinous drop-like CD
11. Fuchs CD

***Special questions to the patient and additional examinations to include or exclude CD***

1. Familiar hint of CD?
  - Visual impairment in the family?
  - Ocular pain in the family?
  - Eye or corneal disorders in the family?
2. Recurrent uni or bilateral pain attacks of the eye, often combined with “Red eye” + epiphora representing a strong hint for CD!
3. Slow, continuous visual impairment uni or bilateral?
4. Changing vision which is worse in the morning and becomes better during the day; hint for Fuchs CD
5. Macroscopic examination of the facial skin
  - red color
  - dry, thin skin
  - teleangiectasies (nose)
  - hints for atopy and rosacea?
6. Examination of the eye lid margins
  - thickening?
  - rarefication of the lid margin
  - chronical blepharitis
  - turn back the upper lid
  - hints for rosacea or atopy?
7. Examination for “dysfunctional tear syndrome”
  - hint for disturbance of the lipid layer of the tear film (chronical blepharitis?)

## Landmarks of CD (direct and indirect illumination)

A. epithelial	1. Maps	
	Dots	Epithelial basement
	Fingerprints	membrane CD
	Blebs	
	DD: Hypertrophic nerves	
	2. a/ Diffuse grey opacities (directly)	Meesmann CD
	b/ Multiple solitary clear microcysts (retro)	
	3. a/ Diffuse grey opacities (directly)	
	b/ Multiple crowded clear microcysts (retro)	Lisch CD
	DD: Morbus Fabry	
B. subepithelial/ stromal	4. Geographical opacity	Reis-Bücklers CD
	5. Honeycomb opacity	Thiel-Behnke CD
	6. a/ Diffuse central opacity	Lattice CD
	b/ paracentral lattice lines	
	DD: Homozygote type Meretoja Syndrome	
	7. Central disk consisting of multiple granules	Granular CD type 1
	DD: Homozygote type	
	8. Central disk consisting of some stars and rings	Granular CD type 2 ("Avellino")
	DD: Homozygote type	
	9. Some flecks (until Descemet) diffuse stromal opacity	Macular CD

	10. Central disk or ring consisting of crowded comma-shaped crystals (often arcus lipoides)	Schnyder CD
	DD: Bietti Cystinosis Paraproteinemia	
	11. Central disk or ring without crystals (often arcus lipoides)	Schnyder CD
	DD: LCAT deficiency Fish eye disease Benign Gammopathy Mucopolysaccharidoses Fuchs CD	
	12. Central posterior crocodile chagrin	Central cloudy CD (François)
	13. Subepithelial band keratopathy	a/ Gelatinous drop-like CD (without endothelial alterations)
		b/ Endothelial CD (combination of subepithelial band keratopathy + endothelial changes) - XECD (in) - CHED (rare) - PPCD (rare)
	DD: non hereditary forms of subepithelial band keratopathy	



C. Endothelial/ stromal	14. Cornea guttata + stromal edema + epithelial bullae	Fuchs CD
	DD: Moon crater-like endothelial changes	
	15. Moon-crater-like changes	XECD
	DD: Cornea guttata	CHED PPCD
	16. Diffuse milky-glass corneal opacification	CHED XECD (rare)
	DD: Congenital glaucoma Mucopolysaccharidoses	PPCD (rare)

## References

1. JS Weiss, HU Moller, W Lisch, et al. The IC3D classification of the corneal dystrophies. *Cornea* 2008; 27 (Suppl 2): 1 – 42.
2. W. Lisch, B. Seitz. New International classification of corneal dystrophies and clinical landmarks. *Klin Monatsbl Augenheilk* 2008; 225: 616-622

**Walter Lisch**  
**[lisch.hanau@t-online.de](mailto:lisch.hanau@t-online.de)**



# Corneal examination techniques: pachymetry, OCT, topography and wavefront

| Jack Holladay, United States |

**Corneal Imaging:  
Topography Tomography  
OCT**

Jack T. Holladay MD, MSEE, FACS  
Clinical Professor of Ophthalmology  
Baylor College of Medicine  
Houston, Texas

2/16/2009 JTH 1


**Consultant**

- AMO, Inc.
- NIDEK, Inc.
- Oculus, Inc.
- Zeiss Meditec, Inc.

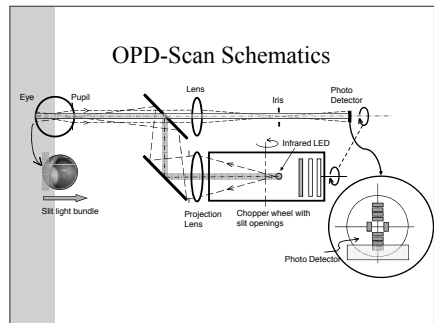
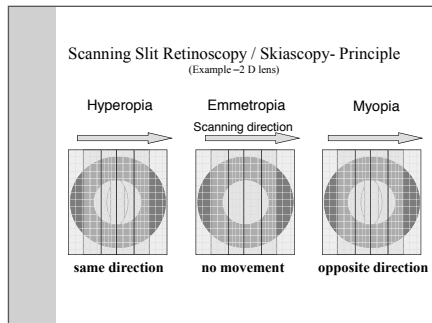
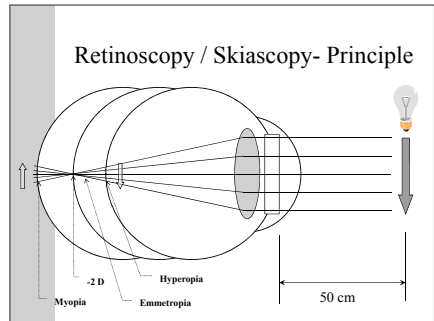
2/16/2009 JTH 4

**OPD-Scan™** Refractive Power/Corneal Analyzer  
NIDEK Optical Path Difference Scanning System

Autorefractometer  
Keratometer  
+  
Topographer  
+  
Pupillometer  
+  
Aberrometer



2/16/2009 JTH 1



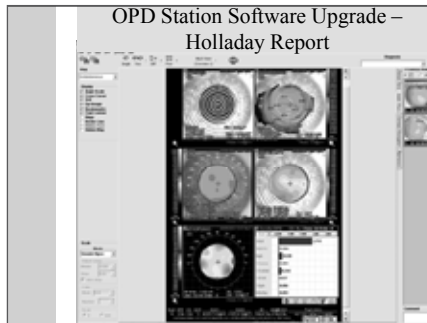
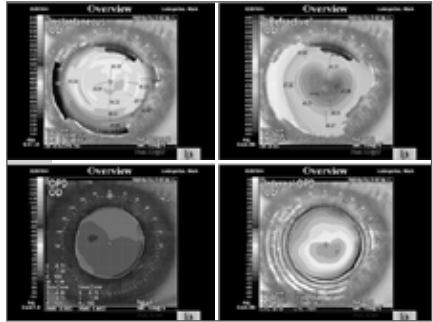
Anterior segment imaging: topography, tomography & OCT

## Internal Aberration

*'The Integration of Topography und Aberrometry in one unit makes it possible to calculate and display Internal Aberrations'*

"Internal" = "Ocular" - "Corneal"  
 (or "Total")

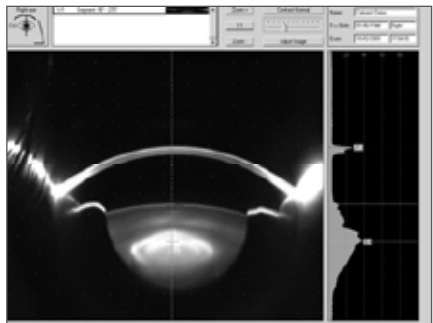
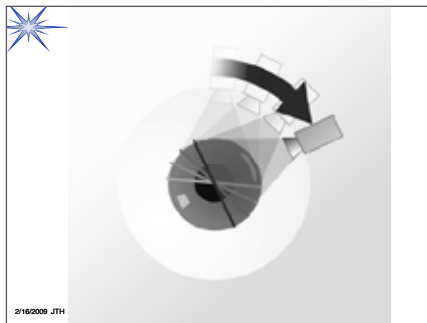
(20%)	(100%)	(80%)
Calculation	Aberrometer	Topography



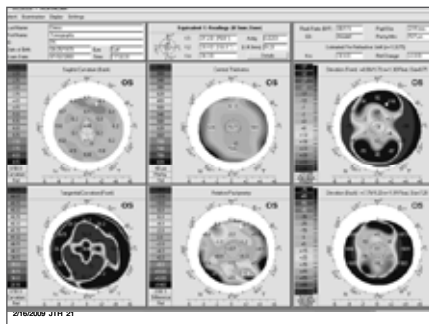

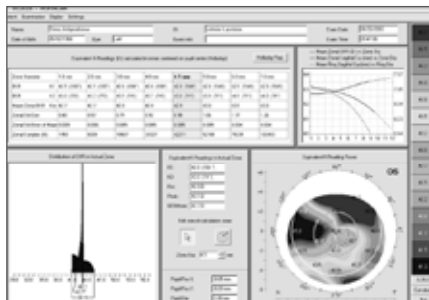
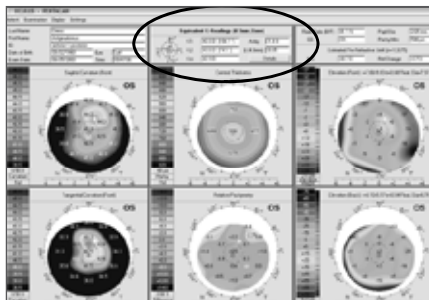
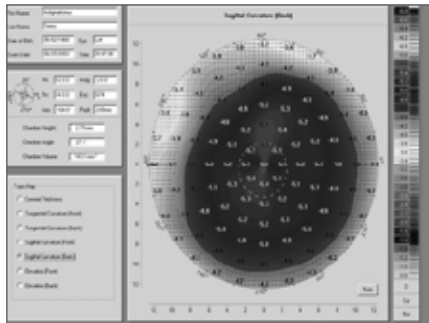
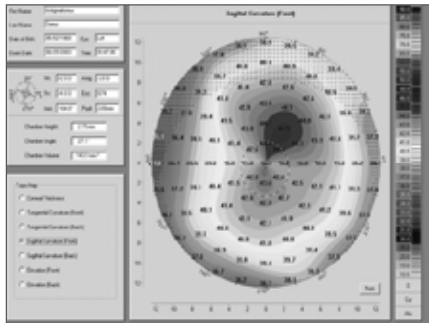
## Tomography

**Oculus**  
**Pentacam**

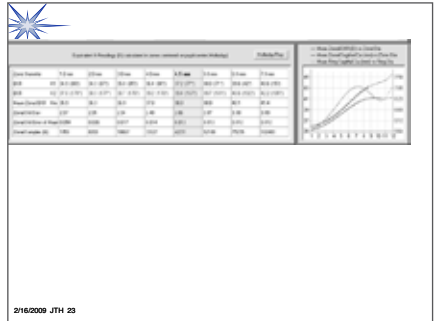
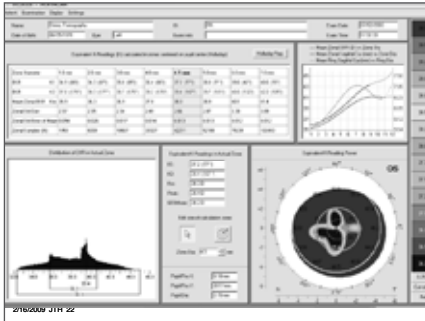
**Measuring Corneal Power**  
**Post Corneal Refractive Surgery**



Anterior segment imaging: topography, tomography & OCT



Anterior segment imaging: topography, tomography & OCT



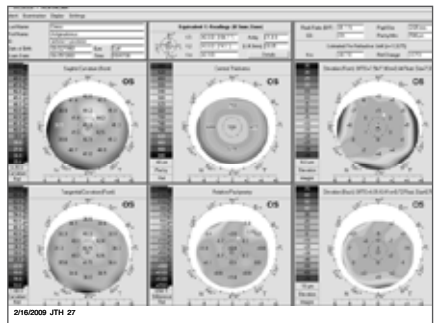
## Accuracy of EKR

Prior Sx	STD 4.5 (D)
LASIK	0.42
RK	0.94
ALL	0.54

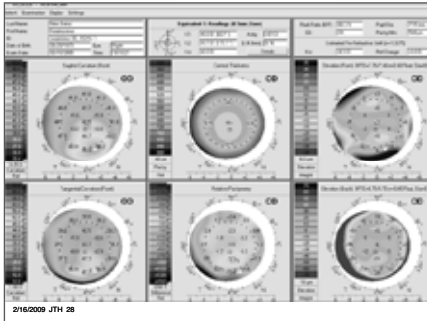
2162009 JTH 24

- ## Summary
- Optimal Zone
    - LASIK: 4.5 mm
    - RK: 5.0 mm
    - Customize for small/large pupils
  - Accuracy
    - LASIK:  $\pm 0.42$  D
    - RK:  $\pm 0.94$  D
  - Error on MYOPIC side
- 2162009 JTH 25

- ## Corneal Ectasia
- By definition is a “thinning” with anterior movement
  - **K-conus: posterior surface 1<sup>st</sup> detectable move**, because epithelium thins and “masks” anterior movement of Bowman’s Membrane
  - **Posterior surface float is more sensitive IF ACCURATE ... NOT ARTIFACT!**
  - **Most prior reports are artifact due to Posterior Surface is VIRTUAL IMAGE seen through Anterior Surface and is distorted by Refractive Surgery ... oblate, blend zone, etc.**
- 2162009 JTH 26



Anterior segment imaging: topography, tomography & OCT

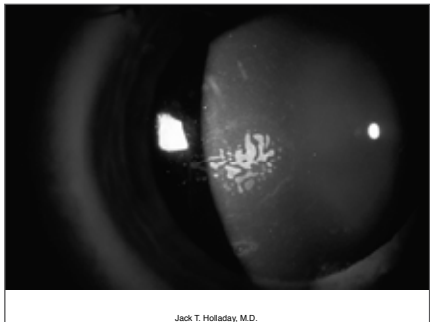
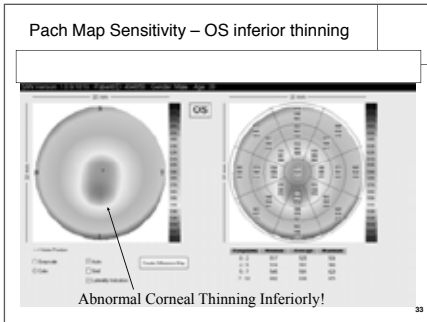
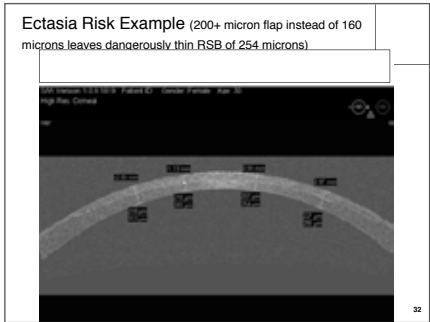


- ### Conclusion
- Pentacam Scheimpflug very sensitive detection of thinning disorders (Cone, Pellucid), if use ...
  - Tangential (local radius) Map to determine “nipple” on front
  - **Toric Ellipsoid Float** (not BFS) with **Elevation Maps** to determine location of protrusions in back and front surface
  - **RELATIVE Pachymetry Map** to determine Thinnest Relative Point

## Visante OCT in Refractive Surgery

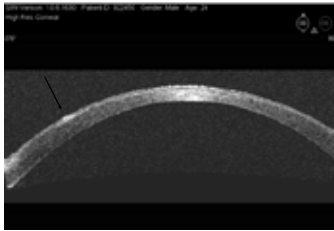
Corneal laser refractive surgery  
 Corneal refractive implants  
 Phakic IOLs

Jack T. Holladay MD, MSEE, FACS  
 Clinical Professor of Ophthalmology  
 Baylor College of Medicine  
 Houston, Texas

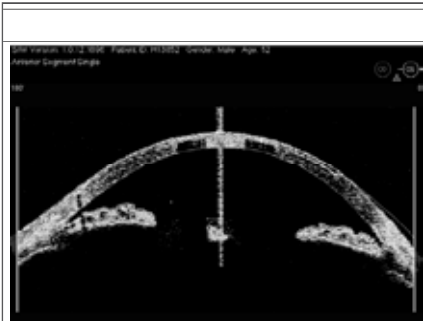
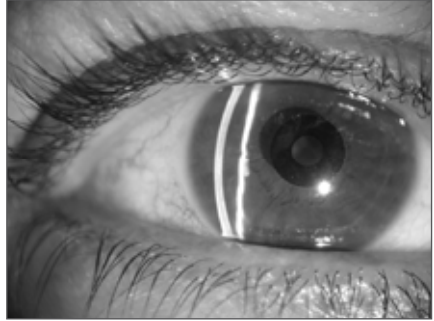


Anterior segment imaging: topography, tomography & OCT

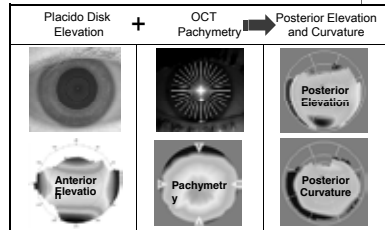
Visante OCT Applications  
Post Op – LASIK Epithelial Ingrowth



32

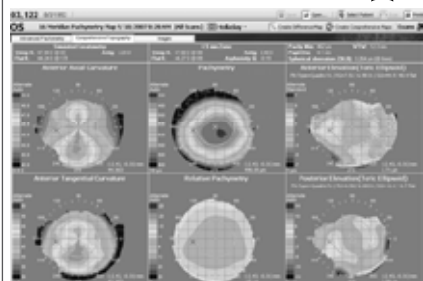


V-Trac™ Alignment System

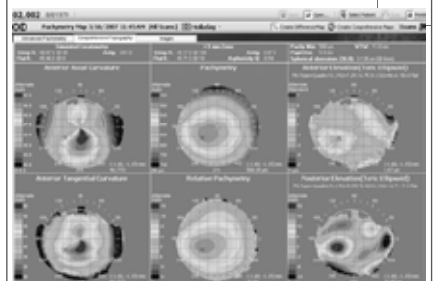


38

Case 6: Normal Cornea



Case 7: Suspect Keratoconus



Anterior segment imaging: topography, tomography & OCT

**Jack T. Holladay, MD, MSEE, FACS**  
**Clinical Professor of Ophthalmology**  
**Baylor College of Medicine**  
**Houston, Texas**  
**[holladay@docholladay.com](mailto:holladay@docholladay.com)**



# Non inflammatory corneal pathology

| Murat Irkeç, Turkey |




**NON-INFLAMMATORY  
CORNEAL PATHOLOGY**

Prof.Dr.Murat Irkeç, MD  
Director, Corneal Service and Research Unit  
Department of Ophthalmology  
Hacettepe University Faculty of Medicine  
Ankara - Turkey

**Degeneration** : deterioration and decrease in *function*

Degenerations may be :

- Unilateral or bilateral
- Often asymmetric
- An inheritance pattern usually not found
- Many occur later in life (normal aging)
- Secondary to systemic or pathological process
- Often eccentric or peripheral
- Relation to vascularity



**Classification of corneal degenerations**

**A. Primary**

- Iron lines
- White limbal girdle of Vogt
- Cornea farinata
- Ant. and post. crocodile shagreen
- Corneal arcus (arcus senilis)
- Hassal-Henle bodies

**Classification of corneal degenerations**

- Pinguecula
- Pterygium
- Spheroid degeneration
- Salzmann s nodular degeneration
- Terrien s marginal degeneration

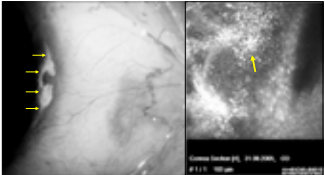
**B.Secondary**

- Corneal amyloid
- Lipid degeneration
- Coat s white ring
- Band keratopathy
- Neurotrophic keratopathy
- Exposure keratopathy
- Recurrent erosion syndrome

**WHITE LIMBAL GIRDLE OF VOGT**

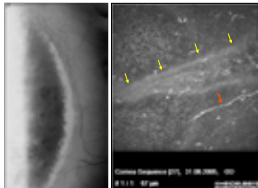
- White, crescentic, peripheral corneal opacities in the interpalpebral area
- Two clinical forms
- Type 1:** rare, *early band keratopathy*, clear zone from limbus
- Type 2:** common, 100% after 80 years of age, more common at the nasal limbus, no peripheral clear zone from limbus
- Histology: subepithelial *hyaline* and *elastotic changes* Bowman s membrane and superficial stroma replaced by basophilic granular deposits

**VOGT's LIMBAL GIRDLE TYPE 1**



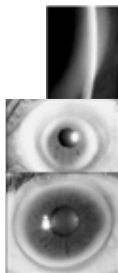- Early calcific band keratopathy
- Narrow lucent area from the limbus
- White band contains holes (*Swiss cheese*)
- Destruction and calcification of Bowman s layer

### VOGT's LIMBAL GIRDLE TYPE 2



- Asymptomatic and incidental
- Lesion is **subepithelial**
- **Elastotic degeneration** and calcium at the level of Bowman's layer

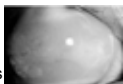### CORNEAL ARCUS



- Gerontoxon in the aged (**Arcus senilis**)
- Ant. embryotoxon in the young (**A. juvenilis**)
- Lipid deposition in the peripheral cornea
- Cholesterol, cholesterol esters, phospholipids, neutral glycerides
- Lipid is extracellular
- Lipids are of vascular origin
- Men affected more than women
- Increased risk of CAD (<40 years)
- Hyperlipoproteinemia type 2 and 3

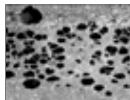
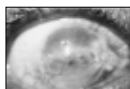
### IRON LINES

- Iron deposition in the epithelium
- Several types due to different causes
- Hudson-Stahli lines (Fleischer, Ferry & Stocker)
- Prevalence and intensity increase with age
- Source of iron unknown
- May be physiological (young people)
- No sex predilection
- Asymptomatic and require no treatment

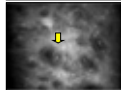
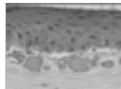


### SPHEROID DEGENERATION

- Climatic droplet keratopathy
- More than one form
  - Primary age-related
  - Secondary form
    - Traumatic corneal scars
    - Herpetic keratitis
    - Chronic corneal edema
    - Lattice dystrophy
    - Chronic open-angle glaucoma
- Conjunctival degeneration
  - Pinguecula

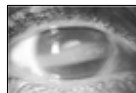

### SPHEROID DEGENERATION



- Prevalence related to geography
- Males affected more than females
- Usually bilateral, may be unilateral
- Clinically yellow-gold subepithelial droplets
- Advance from periphery to the center
- Foreign body sensation irritation, VA decrease possible
- EC proteinaceous material at Bowman's membrane level and anterior stroma
- Treatment: PTK, lamellar KP, lamellar keratectomy

### BAND KERATOPATHY



- Common secondary degeneration
- Calcium phosphate deposition in the anterior cornea
- Caused by local or systemic factors
- Calcium deposition :
  - Intracellular in systemic Ca metabolism abnormalities
  - Extracellular in local ocular disease

**BAND KERATOPATHY**

**Classification**

*Chronic ocular diseases*

- Uveitis (juvenile chronic arthritis)
- Glaucoma
- Corneal edema
- Interstitial keratitis
- Phthisis

*Ocular trauma*

- Climatic exposure
- Mercurial containing preservatives

**BAND KERATOPATHY**

**Classification**


*Systemic abnormalities*

- Hypercalcemia
- Hyperphosphatemia

*Heredity*

- Norrie's disease
- Autosomal recessive band keratopathy


**BAND KERATOPATHY**



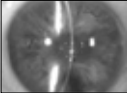
- Confined to the interpalpebral fissure
- Peripheral clear zone at the limbus
- Begins nasally and temporally
- Swiss cheese appearance (corneal nerves)

*Histology:*

- Epithelial BM- basophilic staining
- Bowman's layer /ant. stromal lamellae - Ca<sup>++</sup> deposition and fragmentation
- Subepithelial fibrous pannus
- Scarring



**BAND KERATOPATHY**

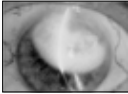


- Ulceration of the corneal epithelium → discomfort
- Reduced vision (visual axial involvement)

*Treatment:*


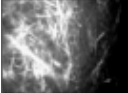

- Epithelial removal → chelation with Na<sub>2</sub>EDTA
- → mechanical debridement with a blade or burr

**LIPID DEGENERATION**



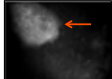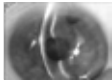
- Accumulation of cholesterol and fatty acid deposits
- **Primary form** - rare, usually bilateral no stromal vascularization
- **Secondary form** - more common, leakage from stromal vessels

**LIPID DEGENERATION**

- Deposits around an area of vessels:
  - Crystalline or diffuse
  - Yellow or cream
  - Discrete or fan-like
- Sudden appearance from NV + VA ↓
- Causes of corneal NV in lipid degeneration:
  - Corneal trauma
  - Infectious keratitis (HSV or HZV)
  - Interstitial keratitis
- Spontaneous regression (occasionally)
- *Treatment:*
  - Argon laser to the feeding vessel
  - Penetrating keratoplasty

## SALZMANN'S NODULAR DEGENERATION

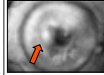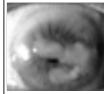


- First reported in 1925
- Rare, noninflammatory, slowly progressive
- Degeneration characterized by bluish white nodules elevated above corneal surface (forming circular array)
- Irregular astigmatism
- Hyperopic refractive shift
- Foreign-body sensation
- Corneal scarring and decreased VA
- Glare

## SALZMANN'S NODULAR DEGENERATION


### Etiology

#### Late sequelae of previous corneal inflammation



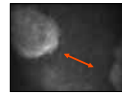
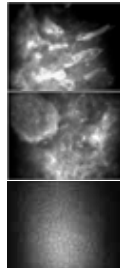
- Phlyctenular keratitis (common)
- Trachoma (common)
- Vernal disease (common)
- Exposure keratopathy
- Interstitial keratitis
- Chronic keratitis
- Idiopathic (rare)
- Following contact lens wear
- Postcorneal surgery
- Epithelial basement membrane dystrophy

## SALZMANN'S NODULAR DEGENERATION



- A fibrillar, hyaline degeneration of collagen-cellular debris.
- The number of fibrocytes in the affected areas can vary (numerous cells that are active to scarce degenerating cells)

## SALZMANN'S NODULAR DEGENERATION



- Clear area between the nodules
- Thinning of the overlying epithelium
- Basal epithelial cell degeneration
- Replacement of Bowman's layer by (eosinophilic) material

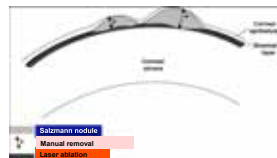
## SALZMANN'S NODULAR DEGENERATION

### Treatment Modalities

- Manual removal
- PTK with or without MMC
- Lamellar/penetrating keratoplasty

All Salzmann cases are individual in their appearance and experience is needed to reach optimal surgical technique

Bowers Jr PJ et al. J Cataract Refract Surg 2003  
Marcon AS, Rapuano CJ Cornea 2002

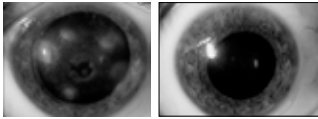


### Schematic drawing of the surgical procedure

- Tissue removal with a surgical knife
- Laser ablation to smooth the surface
- Masking fluid employed several times

From: Sujata D et al. J. Cataract Refract Surg 2005

**SALZMANN'S NODULAR DEGENERATION**



Before Treatment                      After Treatment

PTK appears to be an effective and safe procedure for treatment of Salzmann's nodular degeneration

From: Sujata D et al. J Cataract Refract Surg 2005

**SALZMANN'S NODULAR DEGENERATION**

*Please keep in mind*

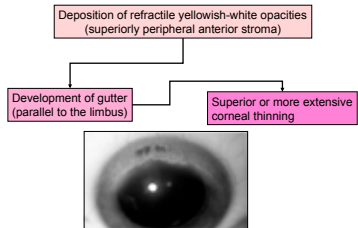
- Certain lesions cannot be removed by a blade only
- Lamellar or penetrating keratoplasty require donor material and are more invasive
- PK rarely recommended due to good endothelium
- Lamellar grafting is useful when PTK is not successful
- Interface haze is a problem in lamellar keratoplasty
- Mitomycine-C may prevent recurrence, but is toxic

**TERRIEN'S MARGINAL DEGENERATION**

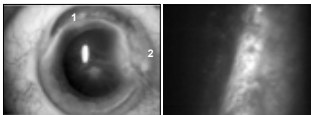


- Slowly progressive thinning of peripheral cornea
- Most common in men (3:1)
- Patient age: **10-70 years**
- Most cases are bilateral ( $\pm$  asymmetry)
- Early stages generally asymptomatic
- Sometimes mild irritation in early stages
- Induced **against- the -rule astigmatism** (late stages)
- Spontaneous or traumatic corneal rupture (rare)

**TERRIEN'S MARGINAL DEGENERATION**

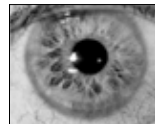


**TERRIEN'S MARGINAL DEGENERATION**



- Gutter is steep centrally, shallow peripherally <sup>(1)</sup>
- Gutter is 1-2 mm in width
- The epithelium remains intact
- Superficial vessels fill the gutter to the central edge
- Deposition of lipid at the central edge
- Pseudoptygium development <sup>(2)</sup>

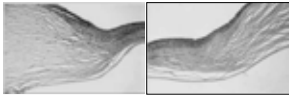
**TERRIEN'S MARGINAL DEGENERATION**



- Most cases are non-inflammatory
- Rare cases with corneal and conjunctival vascular congestion (**with moderate to severe pain**)
- Mixed lymphocytic and neutrophil reaction (stroma)
- Relatively young patients

### TERRIEN'S MARGINAL DEGENERATION

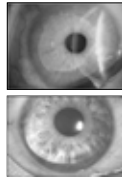
#### Pathology



- Stromal thinning
- Thickened epithelium
- Loss of Bowman's layer
- <25% of the resident cells express MHC Class II antigens
- CD<sub>4</sub>/CD<sub>8</sub> cell ratio  $\pm$  1:1
- <5% of the infiltrating cells CD<sub>22</sub>(+) (B cells)

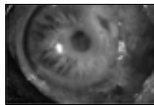
### TERRIEN'S MARGINAL DEGENERATION

#### Differential Diagnosis



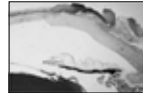
- Arcus senilis (early)
- Mooren's ulcer
- Furrow degeneration
- Marginal pellucid degeneration
- Inflammatory peripheral keratitis
- Peripheral corneal melting (autoimmune)

### MOOREN'S ULCER



- Chronic, painful corneal ulceration
- Two different clinical types:
  - Benign- usually unilateral, older patients
  - Progressive type- 25% of all cases, young patients
- Starts in the peripheral cornea  $\rightarrow$  circumferential spread  
sclera  $\leftarrow$  centrally  $\rightarrow$

### MOOREN'S ULCER



- Inappropriate immunologic responses
- Cornea infiltrated by lymphocytes and plasma cells
- 75% to 100% of the resident cells express MHC class II antigens
- CD<sub>4</sub>/CD<sub>8</sub> cell ratio  $\pm$  2.4:1
- 25% to 50% of the infiltrating cells CD<sub>22</sub>(+)  $\pm$  B cells

### TERRIEN'S MARGINAL DEGENERATION

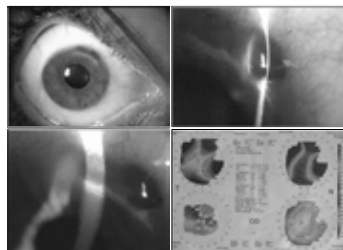
#### Treatment

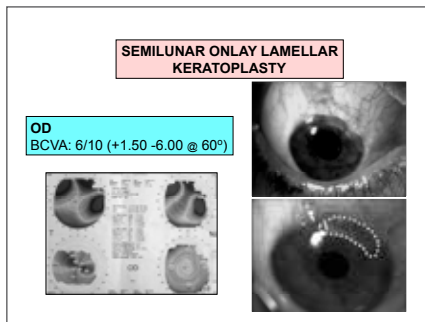
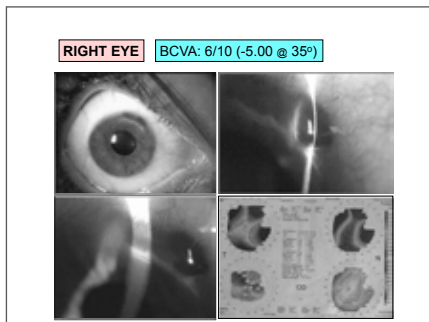
- Observation
- Astigmatic control with spectacles or contact lenses
- Surgical treatment:
  - Excision of ectatic tissue and direct closure
  - Eccentric penetrating keratoplasty
  - Crescentic onlay lamellar keratoplasty



Cheng CL et al. Ophthalmology 2005

RIGHT EYE BCVA: 6/10 (-5.00 @ 35°)





*Prof. Dr. Murat Irkec, MD*  
*Director, Corneal Service and Research Unit*  
*Department of Ophthalmology*  
*Hacettepe University Faculty of Medicine*  
*Ankara, Turkey*  
*mirkec@isnet.net.tr*





# Amniotic membrane and stem cell transplantation and its role in surface reconstruction

| Friedrich Kruse, Germany |

---

6

## A. Amniotic membrane

The use of amniotic membrane in modern ophthalmology was first described by Tseng and co-workers, who also published the preparation technique <sup>(1)</sup>. Most commonly cryo-preserved amniotic membrane is used and surgeons who want to use amniotic membrane have to observe national and EU laws regulating the preparation technique. Freezing amniotic membrane in glycerol kills cells within the membrane but preserves bioactive components <sup>(2)</sup>. Primarily the membrane acts to provide a new basement membrane while being incorporated in the ocular surface <sup>(3)</sup>, promotes epithelial cell migration and calms down inflammation.

There are three major types how amniotic membrane is used:

1. Amniotic membrane transplantation
2. Amniotic membrane patch
3. Amniotic membrane bandage (lens)

Amniotic membrane **transplantation** was first described as using a single layer for non-healing defects of the cornea <sup>(4)</sup>. Most commonly the epithelial side is facing upwards and the membrane is attached to the stroma with interrupted 10-0 nylon sutures <sup>(4)</sup>. Since most corneal ulcers tend to be deeper more than one layer are used in the multilayer approach <sup>(5)</sup>. There are numerous indications for amniotic membrane transplantation and the results vary greatly depending on the underlying pathology <sup>(6)</sup>. It should be noted that transplantation should not be performed in eyes with severe inflammatory disease which can not be controlled by conservative treatment.

Amniotic membrane **patch** is performed by suturing the membrane onto the surface of the eye thereby covering the respective pathology. By this approach, amniotic membrane serves as growth promoting and anti inflammatory agent for a limited time (about a week) after which the membrane detaches from the surface.

Amniotic membrane patch is a very valuable tool for treating severe surface inflammation and injury such as in the case of chemical/thermal burns and Stevens Johnson syndrome <sup>(6)</sup>.

Amniotic membrane bandage is a special mode of application which is suitable for patients with recurrent defects where transplantation is not wanted <sup>(7)</sup>. Indications are persistent defects following corneal transplantation, epithelial defects in the presence of stem cell disease as well as poor compliance.

## **B. Stem cell transplantation**

The ocular surface epithelia are constantly renewed via a proliferate cascade originating in undifferentiated stem cells. Corneal epithelial stem cells are localized at the limbus <sup>(8)</sup>. Loss of stem cells by e.g. injury or inflammation leads to the disease entity of limbal stem cell disease characterized by the presence of goblet cells on the ocular surface <sup>(9)</sup>.

Therapy of limbal stem cell disease belongs to the most challenging problems in ophthalmology. There are two options: transplantation of limbal tissue and transplantation of cultured cells (ex vivo expansion).

### **1) Limbal transplantation**

Surgical reconstruction of limbal stem cell disease started 20 years ago with performing limbal autografts in patients with unilateral pathology <sup>(10)</sup>. This approach is very successful and allows reconstruction in about 90% of patients when the timing of surgery (low inflammation), surgical approach (enough tissue) and underlying pathology are chosen in the right combination. Since this approach is only good for unilateral cases numerous techniques have been used to transplant cadaveric or living related tissue onto patients with bilateral involvement <sup>(11)</sup>. Although some authors have reported favourable outcomes under continuous systemic immunosuppression <sup>(for review see 12,13)</sup> most conventional allografts fail over time

### **2) Ex vivo expansion**

In order to circumvent possible harmful effects of limbal transplantation from donor eyes and to utilize small samples of non ocular tissue ocular surface reconstruction, ex vivo expansion was described <sup>(14)</sup>. Here small samples of cells are harvested and expanded in the laboratory prior to grafting the resultant cell sheet onto the ocular surface. The two major substrates currently used are amniotic membrane

<sup>(15)</sup> and fibrin <sup>(16)</sup>. For unilateral disease, especially results of fibrin based expansion with clonal selection are most encouraging <sup>(16)</sup>. Bilateral limbal stem cell disease requires the use of non ocular cells such as e.g. oral mucosa. Initial results with expansion of mucosal cells on various substrates are promising <sup>(17)</sup>. For further development of current cell based strategies specific knowledge concerning the delicate parameters controlling the limbal microenvironment is needed in order to modify progenitor cells and to ensure longevity of corneal epithelial stem cells on the surface of the eye <sup>(18)</sup>.

## References

1. Kim JC, Tseng SC. - Transplantation of preserved human amniotic membrane for surface reconstruction in severely damaged rabbit corneas *Cornea*. 1995 Sep;14(5):473-84.
2. Kruse FE, Jousseaume AM, Rohrschneider K, You L, Sinn B, Baumann J, Völcker HE. Cryopreserved human amniotic membrane for ocular surface reconstruction. *Graefes Arch Clin Exp Ophthalmol*. 2000 Jan;238(1):68-75
3. Seitz B, Resch MD, Schlötzer-Schrehardt U, Hofmann-Rummelt C, Sauer R, Kruse FE - Histopathology and ultrastructure of human corneas after amniotic membrane transplantation. *Arch Ophthalmol*. 2006 Oct;124(10):1487-90.
4. S.H. Lee and S.C.G. Tseng, Amniotic membrane transplantation for persistent epithelial defects with ulceration. *Am J Ophthalmol* 1997, 123: 303–312.
5. Kruse FE, Rohrschneider K, Völcker HE. - Multilayer amniotic membrane transplantation for reconstruction of deep corneal ulcers. *Ophthalmology*. 1999 Aug;106(8):1504-10; discussion 1511.
6. Dua HS, Gomes JA, King AJ, Maharajan VS. - The amniotic membrane in ophthalmology. *Surv Ophthalmol*. 2004 Jan-Feb;49(1):51-77.
7. Cursiefen C, Rummelt C, Beckmann MW, Kruse FE. - Amniotic membrane-covered bio-onlays for treatment of ocular surface disease. *Br J Ophthalmol*. 2007 Jun;91(6):841-2.
8. Schlötzer-Schrehardt U, Kruse FE - Identification and characterization of limbal stem cells. *Exp Eye Res*. 2005 Sep;81(3):247-64.
9. Tseng S.C.G. - Concept and application of limbal stem cells, *Eye* 1989, 3: 141–157.
10. Kenyon KR, Tseng SC. - Limbal autograft transplantation for ocular surface disorders. *Ophthalmology*. 1989 May;96(5):709-22; discussion 722-3.
11. E.J. Holland and G.S. Schwartz, The evolution of epithelial transplantation for severe ocular surface disease and a proposed classification system, *Cornea* 1996, 15: 549–556
12. H.S. Dua and A. Azuara-Blanco, Limbal stem cells of the corneal epithelium, *Surv. Ophthalmol*. 2000,; 44. 415–425

13. Cauchi PA, Ang GS, Azuara-Blanco A, Burr JM - A systematic literature review of surgical interventions for limbal stem cell deficiency in humans. *Am J Ophthalmol.* 2008 Aug;146(2):251-259.
14. G. Pellegrini, C.E. Traverso, A.T. Franzi, M. Zingirian, R. Cancedda and M. de Luca, Long-term restoration of damaged corneal surface with autologous cultivated corneal epithelium, *Lancet* 1997, 349:990–993
15. Tsai RJ, Li LM, Chen JK - Reconstruction of damaged corneas by transplantation of autologous limbal epithelial cells. *N Engl J Med.* 2000 Jul 13;343(2):86-93.
16. Rama P, Bonini S, Lambiase A, Golisano O, Paterna P, De Luca M, Pellegrini G. Autologous fibrin-cultured limbal stem cells permanently restore the corneal surface of patients with total limbal stem cell deficiency. *Transplantation.* 2001 Nov 15;72(9):1478-85.
17. Nishida K, Yamato M, Hayashida Y, Watanabe K, Yamamoto K, Adachi E, Nagai S, Kikuchi A, Maeda N, Watanabe H, Okano T, Tano Y. Corneal reconstruction with tissue-engineered cell sheets composed of autologous oral mucosal epithelium. *N Engl J Med.* 2004 Sep 16;351(12):1187-96.
18. Schlötzer-Schrehardt U, Dietrich T, Saito K, Sorokin L, Sasaki T, Paulsson M, Kruse FE. - Characterization of extracellular matrix components in the limbal epithelial stem cell compartment. *Exp Eye Res.* 2007 Dec;85(6):845-60. *Epub* 2007 Sep 2.

**Prof. Dr. med Friedrich Kruse,  
Dept. of Ophthalmology, University of Erlangen, Germany  
Friedrich.Kruse@uk-erlangen.de**

# Corneal transplantation: penetrating and lamellar keratoplasty

| Berthold Seitz, Germany |

---

Berthold Seitz MD, Achim Langenbucher PhD and Gottfried O.H. Naumann M

## 1. Ten precautions during corneal graft surgery

1. Donor topography should be attempted for exclusion of previous refractive surgery, keratoconus/high astigmatism, and “harmonization” of donor and recipient topography [16, 56, 59].
2. Donor and recipient trephination should be performed from the epithelial side with the same system, which - from our point of view - is the predisposition for congruent cut surfaces and angles in donor and recipient. For this purpose an artificial anterior chamber is used for donor trephination although the whole globe would yield even better results [27].
3. Orientation structures in donor and host facilitate the correct placement of the first four cardinal sutures to avoid horizontal torsion [2].
4. A measurable improvement seems to be possible, using the Krumeich Guided Trephine System (GTS) [4], the second generation Hanna trephine [81] and our technique of nonmechanical trephination with the excimer laser [58, 66].
5. Horizontal positioning of head and limbal plane are indispensable for state-of-the-art PKP surgery in order to avoid decentration, vertical tilt and horizontal torsion [59].
6. Graft size should be adjusted individually (“as large as possible, as small as necessary”) [60, 62].
7. Limbal centration should be preferred over pupil centration (especially in keratoconus) [31].
8. Excessive graft over- or undersize should be avoided to prevent stretching or compression of peripheral donor tissue [19, 47, 82].
9. As long as Bowman’s layer is intact a double running cross-stitch suture (according to HOFFMANN [17]) is preferred since it result in higher topographic regularity, earlier visual rehabilitation and less suture loosening requiring only rarely suture replacement.
10. Intraoperative keratoscopy should be applied after removal of lid specula and fixation sutures. Instable donor epithelium should better be removed to allow for reproducible results. Adjustment of double running sutures or replacement of single sutures may be indicated [3].

## 2. Trephination techniques

Principal indications for keratoplasty include optical, curative and tectonic. Overlaps between different categories may occur. But corneal transplants may also be classified according to the type of donor material, the vertical shape of graft, the horizontal shape of graft and the location of the graft within the host [40].

A few general technical details concerning PKP need to be addressed [40, 42]:

1. **General anesthesia** has advantages over local anesthesia. The arterial blood pressure should be kept low as the eye is opened (“controlled arterial hypotension”).
2. To protect the crystalline lens in phakic keratoplasty, usually the **pupil is constricted**.
3. Before recipient trephination, a stab-like **paracentesis at the limbus** is performed.
4. The **limbal plane** must be **horizontal** during trephination.
5. An **iridotomy** prevents pupillary block and acute angle closure glaucoma (so-called Urrets-Zavalía syndrome in case of dilated pupil with iris sphincter necrosis [43]).
6. The **second cardinal suture** is crucial for graft alignment.

### 2. 1. Principal considerations

#### 2.1.1. Donor trephination

From a 16-mm corneoscleral button as provided by the eye bank the transplant can be created in two principal ways:

1. In earlier days, the donor button has been punched from the endothelial side against a firm surface (such as a paraffin or teflon block) using special trephines (“Lochpfeifentrepan”) [6, 80]. Care must be taken to ensure a proper alignment when cutting since a beveled cut will result if the blade is not perpendicular to the cutting block. This risk might be decreased by the use of “guided donor trephine” systems (e.g. “guillotins”). On histological evaluation, the cut surfaces without consideration of the cut angles seem to be almost „perfect“. However, deviation of the cut direction outwards result in *convergent cut angles* due to a smaller diameter at the level of Descemet’s membrane and a larger diameter at the level of Bowman’s layer (“*undercut*”) [76].

2. Since the development of “*artificial anterior chambers*“ [23] microsurgeons have the opportunity to accomplish donor trephination from the epithelial side, which is the same direction as in the host. If pressure in the artificial anterior chamber is kept normal (e.g. 22 mmHg) advantages concerning cut angles are obvious [55]. However, fixing the corneoscleral button in an artificial anterior chamber may induce a considerable amount of astigmatism. This problem can be overcome by using an artificial anterior chamber with a larger central opening, leaving the limbus untouched during fixation for trephination from the epithelial side. In this setting the corneoscleral limbus seems to have a protective effect concerning the central corneal topography of the fixated cornea [27].

### 2.1.2. Recipient trephination

For recipient trephination the horizontal position of the head and especially the limbal plane is indispensable. To increase overview and reduce vis à tergo the Lieberman speculum is preferred. Any viscoelastic agent may be used to stabilize the anterior chamber during trephination. A Flieringa ring is not necessary for PKP only and the triple procedure. It is helpful in cases of aphakic eyes, especially if a secondary sclera-fixated IOL should be inserted. The ring can be sutured temporarily onto the globe using 6-0 Vicryl sutures through conjunctiva and episclera.

Investigations of VAN RIJ and WARING demonstrated that in recipient trephination all trephine systems result in an opening larger than the trephine size. In addition, the diameter is larger at the level of Descemet’s membrane resulting in *divergent cut angles* [76]. This can be explained by the “ballooning” of the cornea to be excised into the trephine opening due to the pressure executed. The higher the intraocular pressure is, the more divergent are the angles to be expected [55]. This phenomenon of “ballooning” is one of the major drawbacks of a mechanical trephine and can be prohibited - at least in part - by the use of an “obturator”. However, KAUFMAN stresses that the use of an obturator in keratoconus may result in other than round host openings such as pear-shaped holes [21].

The combination of a donor punched from the endothelial side with convergent cut angles and a host opening with divergent cut angles will result in a triangular-shaped tissue defect at the level of Descemet’s membrane that has to be compensated for with increased suture tension and - consequently - vertical tilt.

### 2.1.3. Graft size and “oversize”

#### Graft size

In a quantitative study we found that the corneal diameter of keratoconus patients was larger than that of Fuchs' patients (mean horizontal diameter of 11.8 mm in keratoconus patients and 11.3 mm in Fuchs' patients) <sup>[60]</sup>. *In general, a good optical performance requires a larger graft whereas a low rate of immunologic graft reactions is favored by a smaller graft.* Therefore, the graft should be “as large as possible, but as small as necessary”. For many eyes with keratoconus a 8.0 mm diameter and in many eyes with Fuchs' dystrophy a 7.5 mm diameter proved to be a good option as a preset for the communication with the eye bank. Today, graft diameters of 5.5 mm to 7.0 mm are only rarely required and justified.

It has been supposed that smaller grafts might be associated with a higher postkeratoplasty astigmatism. In a recent study we found <sup>[62]</sup>:

1. a flatter curvature with smaller grafts,
2. a higher topographic irregularity with smaller grafts,
3. a higher proportion of not measurable keratometry mires with smaller grafts,
4. a tendency towards regularization of topography after suture removal, and
5. no difference concerning the amount of net astigmatism between different graft sizes neither with nor without sutures.

The major reason for the flatter and more irregular graft with smaller diameters seems to be the closer position of the proximal suture ends in relation to the optical center of the graft. This will be pronounced in particular with wider suture bites. After suture removal the potentially topography disturbing circular scar at the graft-host-junction is located closer to the line of sight with smaller grafts. This may explain that overall the regularity of graft topography increases with suture removal but that principal differences between various graft sizes do persist.

Larger sizes may be considered for eccentric tectonic corneoscleral grafts (e.g., after the block excision of tumors of the anterior uvea or cystic epithelial down-growth <sup>[44]</sup>) and in buphthalmos <sup>[73]</sup>. But we do not recommend graft sizes over 8.5 mm in buphthalmos for immunological reasons <sup>[52]</sup>.

Recent studies indicate that the rate of chronic endothelial cell loss after PKP, depends on the initial diagnosis <sup>[32, 53]</sup>. Endothelial migration from donor to recipient in pseudophakic bullous keratopathy along a density gradient is thought to be the reason for this phenomenon. Therefore, eyes with bullous keratopathy



may require a larger graft not just to improve the optical performance but even more to transplant as many endothelial cells as possible. Nevertheless, *graft size has to be judged by the surgeon individually in every single case before recipient trephination* to achieve the best compromise between immunological purposes and optical quality [59, 60]. A slit lamp with measuring device (scale), e.g. Haag-Streit slit lamp, or calipers for intraoperative application may be helpful. Removal of vascularized pannus (in contrast to vascularized stromal scars) may render a larger “individual optimal graft size” possible for transplantation of more endothelial cells and better graft topography.

### Graft “oversize”

In mechanical trephination, the diameter of the recipient bed tends to be larger and the diameter of the donor button, punched from the endothelial side, tends to be smaller than the trephine diameter which may affect the resulting spherical equivalent [76]. Thus, “oversizing” the donor button by 0.25 to 0.50 mm is commonly done to compensate for refractive effects and to reduce crowding of the chamber angle and therefore postoperative “glaucoma” [47]. An oversize of 0.25 mm compared to one of 0 mm or 0.5 mm may account for a difference in keratometric readings of 1.5 diopters after suture removal. JAVADI et al. found no difference in astigmatism comparing 0.25 mm and 0.50 mm graft oversize [19]. However, PERL et al. stressed that oversizing the graft by 0.5 mm (punched from the endothelial side) may result in significantly increased corneal astigmatism [47]. In keratoconus same size donors were found to reduce resulting myopia. We do not recommend undersizing of a graft!

In contrast, with guided trephines and laser trephination (donor from the epithelial side) attempted diameters are indeed achieved with congruent cut angles. Thus, donor oversize is not necessary.

## 2.1.4. Pupil versus limbal centration

Centration is crucial with respect to immunologic graft reaction and post-PKP astigmatism. Typically a compromise between limbal and pupil centration is attempted in case of non-traumatized pupils. However, limbal centration is preferred especially in keratoconus, scars after trauma or irregular astigmatism of other origin. In such eyes the center of the visible (“entrance”) pupil may be dislocated from that of the real anatomical pupil [31].

An eight-line radial keratotomy marker may be used to ensure centration. An additional central dot-like mark may be helpful for certain trephine systems (e.g. Hessburg-Baron).

If the broadening of the superior limbus due a vascularized pannus is neglected intra-operatively, an inferior decentration may be recognized the next day at the slit-lamp.

### **2.1.5. The vascularized cornea**

Excessive bleeding after trephination of vascularized corneas with blood clots left in the anterior chamber may result in increased risk of immunologic graft reaction and peripheral anterior synechiae due to contraction. Thus, the following precautions can be taken:

Before trephination the microsurgeon has to differentiate between vascularized pannus tissue (“PLUS”) and vascularized scars (“MINUS”). Vascularized fibrous tissue between epithelium and Bowman’s layer or the superficial stroma in case of defective Bowman’s layer can be removed easily with a hockey knife. Typically, bleeding stops after a few minutes without additional means. In contrast, distinct “feeder vessels” of vascularized scars may be incised with a pointed scalpel at the limbus. PILLAI et al have proposed sophisticated kauterization techniques for coagulation of afferent and efferent vessels [50]. In case of diffusely capillarized scars, ice cold balanced salt solution (BSS) or topical alpha-mimetic vasoconstricting drops (such as naphazolin-nitrate) may help to reduce bleeding during trephination.

### **2.1.6. Keratoconus and disabling high astigmatism of a graft**

In keratoconus, a central round PKP is indicated as soon as hard contact lenses are no longer tolerated. Excessively steep corneas before surgery do not have less favorable outcome than less deformed corneas after PKP using the excimer laser for nonmechanical trephination [83].

Keratoconus eyes have larger corneas than normal eyes and other dystrophies allowing for larger graft diameters (typically 8.0 mm) [60]. A larger graft diameter in keratoconus patients may help to preserve a sufficiently thick cornea at the trephination margin in the patient since the “cone” can be excised almost completely. Kauterization of the cone has been suggested to avoid divergent cut angles but its effect may not be reproducible. Thus, we do NOT advocate kauterization of the cone. KAUFMAN has suggested not to use obturators in case of keratoconus to prevent unintended creation of elliptical or pear-shaped openings [21].

We do NOT advocate centering the trephination on the cone thereby typically de-centering the trephination with respect to the limbus. In addition, pupil centration may be misleading due to optical distortions of the visible pupil because of irregular refraction of incoming rays of light by the irregularly curved corneal surface in keratoconus [31]. We do NOT advocate undersizing of the donor to reduce myopia, since irregular astigmatism is to be expected.

Due to inhomogeneous corneal thickness an early perforation at the site of thinned cornea is to be expected. This has to be taken into account with conventional trephines to avoid inadvertent injury of the iris or even the lens.

*Peripheral thinning* of the host cornea, e.g. with keratokeratosis (= pellucid marginal degeneration) or Fuchs-Terrien marginal degeneration are very rare but difficult to treat. Treatment options include an eccentric semilunar lamellar/penetrating graft or an over dimensioned preferably elliptical eccentric through-and-through graft.

Eyes with high disabling astigmatism after PKP are often - but not always - associated with small and/or decentered grafts. The re-graft should be well centered and big enough to entirely cut out the previous graft. However, in some cases the previous graft-host junction can not be excised in toto leaving a “wedge” of the first donor tissue in situ. After second suture removal, astigmatism may increase again and may be no longer significantly different in comparison to the preoperative values [70].

Own results suggest a potentially important role of the remaining second running suture in keeping corneal astigmatism values low and topographic regularity high after repeat PKP in patients with high and/or irregular postkeratoplasty astigmatism. After removal of the last suture the curvature may change in an unpredictable and often unfavorable manner. The presumed original instability of the host rim, which on final suture removal may be transferred to the center of the graft (“memory effect”), is probably responsible for the increase in astigmatism and the increase in irregularity of the corneal surface. In addition, the host rim instability may be exacerbated by incomplete excision of the previous graft-host junction in severely decentered first grafts. However, the exact role of any such residual tissue has yet to be clarified.

The long-term value of so-called “intracorneal rings” inside the graft-host junction with respect to stabilization of the topography in such eyes has yet to be determined [13, 24].

## 2.1.7. The instable cornea

### “Instable“ corneas include

1. corneal perforations or descemtoceles typically arising from ulcerative necrotizing stromal keratitis of herpetic or bacterial origin and
2. eyes after unfavorable keratorefractive surgery such as after radial keratotomy and iatrogenic keratectasia after laser-in-situ-keratomileusis (LASIK).

In the “open eye” situation mechanical trephines may lead to compression and distortion of the cornea although a high-viscosity viscoelastic agent is used to stabilize the anterior chamber. Especially with large perforations the trephine can only be used to mark the excision, the keratotomy has to be deepened with a diamond knife and the excision is completed with scissors. Nonmechanical laser trephination has been advocated since it may allow non-contact round and elliptical trephinations [25]. It has been suggested to insert a trimmed part of a soft contact lens via large paracentesis unrolling it inside the anterior chamber and thus achieve a stable eye for trephination after pressurizing the globe by insertion of viscoelastic agent via paracentesis (“valve”). Larger than usual graft oversize (e.g. 0.5 mm) is recommended to avoid peripheral synechiae in eccentric or even peripheral grafts.

In case of excisions involving the limbus, the *scleral spur* has to be preserved during (partly lamellar) trephination. In case of peripheral small perforations an eccentric mini-keratoplasty may have immunological advantages. Wide limbus-parallel perforations - typical of rheumatoid origin - may best be treated with a crescent graft. For this partly “free-hand” procedure, an outer segmental trephination with a smaller diameter (e.g. 10 mm) is combined with an inner segmental trephination with a larger diameter (e.g. 16 mm). Adequate preparation of the slightly oversized graft is best achieved from an intact donor globe but is quite difficult using a corneoscleral button from the eye bank (protection of endothelium!).

After excessive *radial keratotomies* resulting in irregular astigmatism and glare/halos due to scars in the optical field, deep epithelial plugs are typically present inside the original radial cuts over years. Instability leads to opening of these plugs during mechanical trephination. Certain types of circular sutures have been proposed before trephination. However, non-contact laser trephination seems to be the method of choice for such eyes. In analogy, iatrogenic keratectasia after LASIK is prone to opening of the lamellar interface between stromal bed and flap during conventional contact trephination. This may result in oval host wounds and different sizes of the excised button at the flap and bed levels [64]. Again, non-contact laser trephination seems to be the method of choice for such eyes the incidence of which is supposed to increase over the next decades.

### 2.1.8. The triple procedure

Since the introduction of the TRIPLE procedure (= simultaneous penetrating keratoplasty (PKP), extracapsular cataract extraction and implantation of a posterior chamber intraocular lens (PCIOL) in the mid-seventies, there is an ongoing discussion among corneal microsurgeons concerning the best approach (*simultaneous or sequential*) for combined corneal disease and cataract [65]. For the refractive results after TRIPLE some intraoperative details are crucial: Trephination of recipient and donor from the epithelial side without major oversize (Guided Trephine System or Nonmechanical Excimer Laser Trephination) should preserve the preoperative corneal curvature. Graft and the PCIOL placed in the bag after large continuous curvilinear capsulorhexis should be centered along the optical axis. If possible, performing the capsulorhexis under controlled intraocular pressure conditions prior to trephination may help to minimize the risk of capsular ruptures. In case of excessive corneal clouding a capsulorhexis forceps is used via 'open sky'. Delivery of the nucleus is achieved via 'open sky' by means of manual irrigation, removal of the lens cortex by automated irrigation-aspiration.

The major advantage of the TRIPLE is the faster visual rehabilitation and less efforts for the mostly elderly patients. In contrast, sequential cataract surgery has the potential of a simultaneous reduction of corneal astigmatism (appropriate location of the incision, simultaneous refractive keratotomies or implantation of a toric PCIOL). Disadvantages may include the loss of graft endothelial cells and the theoretically increased risk of immunologic allograft reactions. After TRIPLE, major deviations from target refraction have been reported. However, individual multiple regression analysis may help to minimize this problem with appropriate methods of trephination [77]. Since suture removal after PK may result in major individual changes of the corneal curvature, IOL power calculation for the sequential approach requires all sutures to be removed at the time of cataract surgery. However, even after complete suture removal the abnormal proportions between anterior and posterior curvatures and/or the irregular topographies after PKP may be responsible for marked IOL power miscalculations in the individual eye [65].

### 2.1.9. Impact of trephination on suturing

The trephination modality may have a major impact on the correct placement of the first four or eight cardinal sutures. The predominant purpose of the *cardinal sutures* is (1) symmetrical horizontal distribution of donor tissue in the recipient bed, (2) good adaptation of graft and host on Bowman's level (external steps are to be avoided, internal steps may be tolerated in case of thin recipient corneas such as

in pellucid marginal degeneration or herpetic scars), (3) stabilization of the anterior chamber for homogenous further suturing.

Unintentionally other than round host opening may create a challenge even for the experienced PKP surgeon concerning the correct placement of the *second cardinal suture*. After removal of the cardinal sutures the quality of the trephination and graft positioning are major determinants for water-tight wound closure. The better the trephination the smaller is the final suture tension required for water-tight wound closure after removal of the cardinal sutures. The smaller the final suture tension, the better is the visual acuity as long as the sutures are in place. Generally, in cases where Bowman's layer is intact, a 16-bite double running diagonal cross-stitch suture (10-0 Nylon) according to HOFFMANN is preferred. The more rapid visual rehabilitation with these sutures in place in contrast to single sutures is due to a more regular corneal topography avoiding cornea plana.

## 2. 2. Conventional mechanical trephines

In 1886 it was Arthur von Hippel who used the first mechanical clock-watch driven trephine for transplantation of a lamellar corneal graft from a rabbit to a human [79]. The same trephine was used by Eduard Zirm for his first successful PKP in a patient in 1905 [84].

Conventional mechanical trephination is associated with *deformation* of corneal tissue including a distortion of the cut margin with rough cut edges as a consequence of *axial and radial forces* induced by the trephine. The cut angle deviates from the perpendicular and it may be different in donor and recipient, especially if the donor trephination is undertaken from the endothelial side. The fitting of the donor tissue into the malleable recipient cornea is extremely difficult to achieve in a perfectly symmetrical fashion. After suturing the incongruent cut edges in order to achieve water-tight wound closure, wound healing may cause marked distortion of the surface topography after suture removal due to this "vertical tilt". In addition, asymmetric cardinal suture placement may result in unequal donor tissue distribution in the host wound, particularly if the second cardinal suture is not placed exactly opposite to the first ("horizontal torsion") [42].

A questionnaire was sent to all German keratoplasty surgeons asking for their preferred technique of trephination in the year 2002. For recipient trephination most surgeons use the GTS (34.3%), the hand-held trephine (17.8%) or the Hessburg-Barron trephine (16.3%). Motor trephines are used more rarely and the laser

trephination has still not entered many operating theaters because it is bulky and expensive. As much as 12% of all procedures were performed with different trephine systems for donor and recipient! [5]

## 2. 3. Nonmechanical laser trephination

Hypothesizing that the properties of the wound bed are much more important for the final “all-suture-out” astigmatism and the final optical performance of the graft than various types of suture techniques or methods of suture adjustment we have developed and optimized the technique of *nonmechanical* corneal trephination since 1986. Since 1989 more than human 1750 eyes have been treated successfully with the Meditec MEL60® excimer laser. Keratoconus has been by far the leading indication (around 37%) for PKP with this non-contact technique. For donor trephination from the epithelial side an artificial anterior chamber is used [41, 42, 58, 66].

The main advantage of this novel laser cutting technique performed from the epithelial side in donor and recipient is the avoidance of mechanical distortion during trephination, resulting in smooth cut edges which are congruent in donor and patient potentially reducing “vertical tilt” [33]. Such cut edges in combination with “orientation teeth” at the graft margin [2] and corresponding notches at the recipient margin for symmetric positioning of the eight cardinal sutures minimizes “horizontal torsion”, thus potentially improving the optical performance after transplantation [42]. Furthermore, recipient and donor decentration may be reduced [30, 61]. The use of metal masks allows for arbitrary shapes of the trephination [28].

These favorable impacts on major intraoperative determinants of postkeratoplasty astigmatism result in lower keratometric astigmatism, higher topographic regularity and better visual acuity after suture removal. After sequential removal of a double running suture keratometric astigmatism increased in 80% of eyes with conventional trephination, but further decreased in 52% of eyes with laser trephination [58]. Besides less blood-aqueous barrier breakdown during the early postoperative time course after PK [26], laser trephination does induce neither cataract formation nor higher endothelial cell loss of the graft. Likewise, the rates of immunologic graft rejection and secondary ocular hypertension are comparable using either technique. In addition, trephination of an instable cornea, such as in (pre-) perforated corneal ulcers or after RK or LASIK is facilitated [64].

## References:

1. Behrens A, Kühle M, Seitz B, Langenbacher A, Kus MM, Amann T, Schlötzer-Schrehardt U, Rummelt C, Naumann GOH (1998) Stromal thermal effects induced by nonmechanical (2.94  $\mu\text{m}$ ) Er:YAG laser corneal trephination. *Arch Ophthalmol* 116: 1342-1348
2. Behrens A, Seitz B, Kühle M, Langenbacher A, Kus MM, Amann T, Rummelt C, Naumann GOH (1999) "Orientation teeth" in nonmechanical laser corneal trephination: 2.94- $\mu\text{m}$  Er:YAG laser vs. 193-nm ArF excimer laser. *Br J Ophthalmol* 83:1008-1012
3. Belmont SC, Troutman RC, Buzard KA (1993) Control of astigmatism aided by intraoperative keratometry. *Cornea* 12:397-400
4. Belmont SC, Zimm JL, Storch RL, Draga A, Troutman RC (1993) Astigmatism after penetrating keratoplasty using the Krumeich Guided Trephine System. *Refract Corneal Surg* 9:250-254
5. Blüthner K, Seitz B (2004) *Verwendete Trepensysteme bei der perforierenden Keratoplastik - ein Bericht aus dem Deutschen Keratoplastikregister 2002*. 102. Tagung der Deutschen Ophthalmologischen Gesellschaft (Vortrag), Berlin [Ophthalmologie submitted]
6. Brightbill FS (ed): *Corneal Surgery. Theory, Technique and Tissue*. St. Louis: Mosby, 1993
7. Busin M (2003) A new lamellar wound configuration for penetrating keratoplasty surgery. *Arch Ophthalmol* 121:260-265
8. Cohen KL, Tripoli NK, Pellom AC, Kupper LL, Fryczkowski AW (1984) Effect of tissue fit on corneal shape after transplantation. *Invest Ophthalmol Vis Sci* 25:1226-1231
9. Cohen KL, Holman RE, Tripoli NK, Kupper LL (1986) Effect of trephine tilt on corneal button dimensions. *Am J Ophthalmol* 101:722-725
10. Dave AS, McCulley JP (1994) Demonstration of feasibility of application of a portable keratometer to cadaveric donor corneas. *Cornea* 13:379-382
11. Davis EA, Azar DT, Jakobs FM, Stark WJ (1998) Refractive and keratometric results after the triple procedure. Experiences with early and late suture removal. *Ophthalmology* 105:624-630
12. Duffin M, Olson RJ, Ohrloff C (1984) Analysis of the Hessburg-Barron vacuum trephine. *Ophthalmic Surg* 15:51-54
13. Ehrich D, Duncker GI (2004) [The use of intracorneal rings in penetrating keratoplasty.] *Klin Monatsbl Augenheilkd* 221:92-95
14. Filatov V, Alexandrakis G, Talamo JH, Steinert RF (1996) Comparison of suture-in and suture-out postkeratoplasty astigmatism with single running suture or combined running and interrupted sutures. *Am J Ophthalmol* 122:696-700



15. Greenfield DS, Jivanjee SQ, Raizman MB (1995) The effect of trephination on corneal topography. *Ophthalmic Surg Lasers* 26:560-567
16. Grütters G, Reichelt JA, Nölle B (2001) [Astigmatism-oriented perforating keratoplasty. A possibility for minimizing postoperative astigmatism?] *Ophthalmologie* 98:397-401
17. Hoffmann F (1976) [Suture technique for perforating keratoplasty.] *Klin Monatsbl Augenheilkd* 169:584-590
18. Hoppenreijts VPT, Van Rij G, Beekhuis WH, Rijnveld WJ, Rinkel-Van Driel E (1993) Causes of high astigmatism after penetrating keratoplasty. *Doc Ophthalmol* 85:21-34
19. Javadi MA, Mohammadi MJ, Mirdehghan SA, Sajjadi SH (1993) A comparison between donor-recipient corneal size and its effect on the ultimate refractive error induced in keratoconus. *Cornea* 12:401-405
20. Judge D, Gordon L, Van der Zwaag R, Wood TO (1990) Refractive versus keratometric astigmatism postkeratoplasty. *Refract Corneal Surg* 6:174-178
21. Kaufman HE, McDonald MB, Barron BA, Wilson SE (1992) *Corneal and Refractive Surgery*. Philadelphia: J.B. Lippincott
22. Krumeich J, Binder PS, Knülle A (1988) The theoretical effect of trephine tilt on postkeratoplasty astigmatism. *CLAO J* 14:213-219
23. Krumeich JH, Grasl MM, Binder PS, Knülle A (1990) Geführtes Trepensystem für perforierende Keratoplastiken. In: Freyler H, Skorpik C, Grasl M (eds.): 3. Kongreß der Deutschen Gesellschaft für Intraokularlinsenimplantation. Wien: Springer, pp 450-456
24. Krumeich JH, Daniel J (1999) Perforating keratoplasty with an intracorneal ring. *Cornea* 18:277-281
25. Kückle M, Nguyen NX, Seitz B, Langenbacher A, Naumann GOH (1998) Blood-aqueous barrier after mechanical or nonmechanical excimer laser trephination in penetrating keratoplasty. *Am J Ophthalmol* 125: 177-181
26. Kückle M, Seitz B, Langenbacher A, Naumann GOH (1999) Nonmechanical excimer laser penetrating keratoplasty for perforated or predecemetal corneal ulcers. *Ophthalmology* 106:2203-2209
27. Kus MM, Seitz B, Langenbacher A, Naumann GOH (1995) The effects of scleral and limbal fixation on the topography of corneoscleral buttons in an artificial anterior chamber. *Invest Ophthalmol Vis Sci* 36(4, Suppl.):S980
28. Lang GK, Naumann GOH, Koch JW (1990) A new elliptical excision for corneal transplantation using an excimer laser. *Arch Ophthalmol* 108:914-915
29. Langenbacher A, Seitz B, Kus MM, Vilchis E, Naumann GOH (1996) [Regularity of corneal topography after penetrating keratoplasty – comparison between non-mechanical (excimer laser 193 nm) and mechanical trephination.] *Klin Monatsbl Augenheilkd* 208:450-458

30. Langenbucher A, Seitz B, Kus MM, Vilchis E, Naumann GOH (1998) Graft decentration in penetrating keratoplasty - Nonmechanical trephination with the excimer laser (193 nm) versus the motor trephine. *Ophthalmic Surg Lasers* 29:106-113
31. Langenbucher A, Kus MM, Neumann J, Seitz B (1999) [Calculating the localization and dimension of the real pupil in keratoconus with ray tracing of corneal topography data.] *Klin Monatsbl Augenheilkd* 215:163-168
32. Langenbucher A, Seitz B, Nguyen NX, Naumann GOH (2002) Graft endothelial cell loss after nonmechanical penetrating keratoplasty depends on diagnosis: a regression analysis. *Graefes Arch Clin Exp Ophthalmol* 240:387-392
33. Langenbucher A, Seitz B, Kus MM, Naumann GOH (1998) [Transplant vertical tilt after perforating keratoplasty - comparison between non-mechanical trepanation with excimer laser and motor trepanation.] *Klin Monatsbl Augenheilkd* 212:129-140
34. Lieberman DM, Troutman RC (1992) The theory of "other than round" cornea transplantation. *Refract Corneal Surg* 8:97-100
35. Lin DT, Wilson SE, Reidy JJ, Klyce SD, McDonald MB, Insler MS, Kaufman HE (1990) Topographic changes that occur with 10-0 running suture removal following penetrating keratoplasty. *Refract Corneal Surg* 6:21-25
36. Mader TH, Yuan R, Lynn MJ, Stulting RD, Wilson LA, Waring II GO (1993) Change in keratometric astigmatism after suture removal more than one year after penetrating keratoplasty. *Ophthalmology* 100:119-127
37. Melles GR, Eggink FA, Lander F, Pels E, Rietveld FJ, Beekhuis WH, Binder PS (1998) A surgical technique for posterior lamellar keratoplasty. *Cornea* 17:618-626
38. Musch DC, Meyer RF, Sugar A (1988) The effect of removing running sutures on astigmatism after penetrating keratoplasty. *Arch Ophthalmol* 106:488-492
39. Naumann GOH (1972) [Simple keratoplasty trephine to be used under the operating microscope.] *Klin Monatsbl Augenheilkd* 161:708
40. Naumann GOH, Sautter H: Surgical procedures on the cornea. In: Blodi FC, Mackensen G, Neubauer H (eds) *Surgical Ophthalmology* 1. Berlin: Springer; 1991:433-497.
41. Naumann GOH, Seitz B, Lang GK, Langenbucher A, Kus MM (1993) [193 excimer laser trepanation in perforating keratoplasty. Report of 70 patients.] *Klin Monatsbl Augenheilkd* 203: 252-261
42. Naumann GOH (1995) The Bowman Lecture (Number 56) 1994. Part II: Corneal transplantation in anterior segment diseases. *Eye* 9:395-421
43. Naumann GOH (1995) Iris ischaemia following penetrating keratoplasty for keratoconus (Urrets-Zavalía syndrome). *Cornea* 14:618
44. Naumann GOH, Rummelt V (1996) Block excision of tumors of the anterior uvea. *Ophthalmology* 103:2017-2028
45. Olson RJ (1983) Modulation of postkeratoplasty astigmatism by surgical and suturing techniques. *Int Ophthalmol Clinics* 23(4):137-151

46. Pallikaris I (1980) [Preoperative Placido photography in keratoconus and its meaning in conjunction with postoperative astigmatism.] *Albrecht v. Graefes Arch klin exp Ophthalmol* 213:87-99
47. Perl T, Charlton KH, Binder PS (1981) Disparate diameter grafting. Astigmatism, intraocular pressure and visual acuity. *Ophthalmology* 88:774-780
48. Perlman EM (1981) An analysis and interpretation of refractive errors after penetrating keratoplasty. *Ophthalmology* 88:39-45
49. Pfister RR, Breaud S (1983) Aphakic refractive penetrating keratoplasty using newborn donor corneas. A preliminary report on an alternative approach to refractive correction. *Ophthalmology* 90:1207-1212
50. Pillai CT, Dua HS, Hossain P (2000) Fine needle diathermy occlusion of corneal vessels. *Invest Ophthalmol Vis Sci* 41:2148-2153
51. Pflugfelder SC, Roussel TJ, Denham D, Feuer W, Mandelbaum S, Parel JM (1992) Photogrammetric analysis of corneal trephination. *Arch Ophthalmol* 110:1160-1166
52. Price FW Jr, Whitson WE, Johns S, Gonzales JS (1996) Risk factors for corneal graft failure. *J Refract Surg* 12:134-143
53. Reinhard T, Böhringer D, Hüschen D, Sundmacher R (2002). [Chronic endothelial cell loss of the graft after penetrating keratoplasty: influence of endothelial cell migration from graft to host.] *Klin Monatsbl Augenheilkd* 219:410-416
54. Sarhan AR, Dua HS, Beach M (2000) Effect of disagreement between refractive, keratometric, and topographic determination of astigmatic axis on suture removal after penetrating keratoplasty. *Br J Ophthalmol* 84:837-841
55. Sauer R, Seitz B, Mardin C, Langenbacher A, Hofmann-Rummelt C, Viestenz A, Kühle M, Naumann GOH (2003) [Impact of intracameral pressure on donor cut angles in nonmechanical Er:YAG laser trephination for penetrating keratoplasty.] *Klin Monatsbl Augenheilkd* 220:396-403.
56. Seitz B, Langenbacher A, Kus MM, Naumann GOH (1994) Consideration of donor and recipient corneal topography improves graft alignment in penetrating keratoplasty. *Invest Ophthalmol Vis Sci* 35(4, Suppl.):1879
57. Seitz B, Behrens A, Langenbacher A, Kus MM, Naumann GOH (1998) Experimental 193-nm excimer laser trephination with divergent cut angles in penetrating keratoplasty. *Cornea* 17: 410-416
58. Seitz B, Langenbacher A, Kus MM, Kühle M, Naumann GOH (1999) Nonmechanical corneal trephination with the excimer laser improves outcome after penetrating keratoplasty. *Ophthalmology* 106:1156-1165
59. Seitz B, Langenbacher A, Naumann GOH (2000) Astigmatismus bei Keratoplastik. In: Seiler T (ed.): *Refraktive Chirurgie*. Enke, Stuttgart, pp 197-252
60. Seitz B, Langenbacher A, Zagrada D, Budde W, Kus MM (2000) [Corneal dimensions in various types of corneal dystrophies and their effect on penetrating keratoplasty.] *Klin Monatsbl Augenheilkd* 217:152-158

61. Seitz B, Langenbucher A, Meiller R, Kus MM (2000) [Decentration of donor cornea in mechanical and excimer laser trephination for penetrating keratoplasty.] *Klin Monatsbl Augenheilkd* 217:144-151
62. Seitz B, Langenbucher A, KÜchle M, Naumann GOH (2003) Impact of graft diameter on corneal power and the regularity of postkeratoplasty astigmatism before and after suture removal. *Ophthalmology* 110:2162-2167
63. Seitz B, Langenbucher A, Hofmann-Rummelt C, Schlötzer-Schrehardt U, Naumann GOH (2003) Nonmechanical posterior lamellar keratoplasty using the femtosecond laser (femto-PLAK) for corneal endothelial decompensation. *Am J Ophthalmol* 136:769-772
64. Seitz B, Rozsival P, Feuermannova A, Langenbucher A, Naumann GOH (2003) Penetrating keratoplasty for iatrogenic keratoconus after repeat myopic laser in situ keratomileusis: histologic findings and literature review. *J Cataract Refract Surg* 29:2217-2224
65. Seitz B, Langenbucher A, Viestenz A, Dietrich T, KÜchle M, Naumann GOH (2003) [Cataract and keratoplasty - simultaneous or sequential surgery?] *Klin Monatsbl Augenheilkd* 220:326-329
66. Seitz B, Langenbucher A, Nguyen NX, Kus MM, KÜchle M, Naumann GOH (2004) [Results of the first 1000 consecutive elective nonmechanical keratoplasties with the excimer laser - A prospective study over more than 12 years.] *Ophthalmologie* 101:478-488
67. Seitz B, Brünner H, Viestenz A, Hofmann-Rummelt C, Schlötzer-Schrehardt U, Naumann GOH, Langenbucher A (2005) Inverse mushroom-shaped nonmechanical penetrating keratoplasty using a femtosecond laser. *Am J Ophthalmol* 139:941-944
68. Stojkovic M, KÜchle M, Seitz B, Langenbucher A, Viestenz A, Viestenz A, Hofmann-Rummelt C, Schlötzer-Schrehardt U, Naumann GOH (2003) Nonmechanical Q-switched Erbium:YAG laser trephination for penetrating keratoplasty: Experimental study on human donor corneas. *Arch Ophthalmol* 110:2162-2167
69. Stojkovic M, Seitz B, KÜchle M, Langenbucher A, Viestenz A, Viestenz A, Hofmann-Rummelt C, Naumann GOH (2003) Corneal shrinkage induced by nonmechanical Q-switched erbium:YAG laser trephination for penetrating keratoplasty. *Graefe's Arch Clin Exp Ophthalmol* 241:667-672
70. Szentmáry N, Seitz B, Langenbucher A, Naumann GOH (2005) Repeat keratoplasty for correction of high or irregular postkeratoplasty astigmatism in clear corneal grafts. *Am J Ophthalmol* 139:826-830
71. Terry AM, Ousley PJ (2001) Endothelial replacement without surface corneal incisions or sutures: topography of the deep lamellar endothelial keratoplasty procedure. *Cornea* 20:14-18

72. Tilanus M, van Rij G (1987) *An experimental comparison of three methods for trephination of the cornea and the consequent variations in the configurations of the trephine openings.* Graefe's Arch Clin Exp Ophthalmol 225:50-52
73. Toker E, Seitz B, Langenbucher A, Dietrich T, Naumann GOH (2003) *Penetrating keratoplasty for endothelial decompensation in eyes with buphthalmos.* Cornea 22:198-204
74. Troutman RC, Buzard KA (1992) *Corneal Astigmatism: etiology, prevention, and management.* St. Louis, Mosby-Year Book, pp 349-451
75. Van Rij G, Cornell FM, Waring III GO, Wilson LA, Beekhuis H (1985) *Postoperative astigmatism after central vs eccentric penetrating keratoplasties.* Am J Ophthalmol 99:317-320
76. Van Rij G, Waring GO III (1988) *Configuration of corneal trephine opening using five different trephines in human donor eyes.* Arch Ophthalmol 106:1228-1233
77. Viestenz A, Seitz B, Langenbucher A (2005) *IOL power prediction for TRIPLE procedures in Fuchs' dystrophy using multiple regression analysis.* Acta Ophthalmol Scand 83:312-315
78. Villacriz E, Rife L, Smith RE (1987) *Oval host wounds and postkeratoplasty astigmatism.* Cornea 6:181-184
79. Von Hippel A (1886) *Über Transplantationen der Kornea.* Ber Ophthalmol Ges Heidelberg 18:54
80. Waring GO III, Hanna KD (1989) *The Hanna suction punch block and trephine system for penetrating keratoplasty.* Arch Ophthalmol 107:1536-1539
81. Wilbanks GA, Cohen S, Chipman M, Rootman DS (1996) *Clinical outcomes following penetrating keratoplasty using the Barron-Hessburg and Hanna corneal trephination systems.* Cornea 15:589-598
82. Wilson SE, Bourne WM (1989) *Effect of recipient-donor trephine size disparity on refractive error in keratoconus.* Ophthalmology 96:299-305
83. Yi Liu, Seitz B, Langenbucher A, Nguyen NX, Naumann GOH (2003) *Impact of preoperative corneal curvature on the outcome of penetrating keratoplasty in keratoconus.* Cornea 22:409-412
84. Zirm E (1906) *Eine erfolgreiche totale Keratoplastik.* Albrecht von Graefes Arch Klin Exp Ophthalmol 64:580-593

**Berthold Seitz, MD, FEBO**

**Professor and chairman**

**Department of Ophthalmology, University of Saarland**

**Kirrbergerstraße 1, D-66421 Homburg/Saar, Germany**

**berthold.seitz@uks.eu**

**www.uniklinikum-saarland.org**



# Corneal transplantation: immunology and angiogenesis

| Claus Cursiefen, Germany |

---

## Corneal (Lymph)angiogenesis - From bedside to bench and back: a tribute to Judah Folkman

Birgit Regenfuss Dipl.-Biol.<sup>1</sup>, Felix Bock Ph.D.<sup>1</sup>, Anand Parthasarathy, M.D.<sup>2</sup>, and Claus Cursiefen, M.D.<sup>1</sup>

<sup>1</sup> Department of Ophthalmology and Interdisciplinary Center for Clinical Research (IZKF), Friedrich-Alexander University Erlangen-Nürnberg, Erlangen, Germany.

<sup>2</sup> Corneal Service, Singapore National Eye Center, Singapore, Singapore.

This research is supported by the Interdisciplinary Center for Clinical Research (IZKF), Erlangen, Germany, the International Council of Ophthalmology (ICO), and the German Research Foundation (DFG; SFB 649, B10).

8

### Abstract

The normal cornea, the transparent “windscreen” of the eye, is devoid of both blood and lymphatic vessels. Nevertheless, both hem- and lymphangiogenesis can occur in response to severe corneal inflammation and can lead to blindness. Judah Folkman and co-workers exceedingly used the normally avascular cornea as the *in vivo* model system to study the mechanisms of angiogenesis and to test activators and inhibitors of angiogenesis in the last 3 decades. Recently, the cornea also became a successful model to study especially inflammatory lymphangiogenesis. As the last step in the circle from bedside to bench and back, we now are seeing the first (usually off-label) use of specific novel angiogenesis inhibitors in the diseased and pathologically vascularized human cornea to treat sight-threatening corneal angiogenesis and to promote graft survival after corneal transplantation by inhibiting lymphangiogenesis.

### Introduction

THE CORNEA, THE TRANSPARENT “WINDSCREEN” OF THE EYE, is one of the few avascular tissues of the human body (Fig. 1).<sup>1</sup> The cornea actively sustains its avascularity to maintain transparency and good visual acuity. This so-called “angiogenic privilege” of the cornea is therefore evolutionary highly conserved and supported by multiple redundant molecular mechanisms.<sup>1-4</sup>

Nonetheless, the human cornea can be invaded by blood and—as we could recently demonstrate—also by clinically invisible lymphatic vessels (hem- and lymphangiogenesis; Fig. 2).<sup>5</sup> This leads to reduced corneal transparency and blindness and also affects the survival of subsequent corneal transplants. Therefore, clinical ophthalmology has dealt with the phenomenon and problem of sight-threatening corneal neovascularization for over 100 years. Already in the 1940's, Michaelson hypothesized, based on observations made on pathologically neovascularized corneas, that a “diffusible factor X” is responsible for corneal neovascularization.<sup>6</sup>

But it was not until Judah Folkman and co-workers went from “bedside to bench” to analyze the mechanisms of angiogenesis, that our understanding of angiogenesis has dramatically increased.<sup>7–10</sup> To do that, he and others heavily used the cornea as an *in vivo* model system to study angiogenesis, for which the cornea due to its avascular nature is perfectly suited.

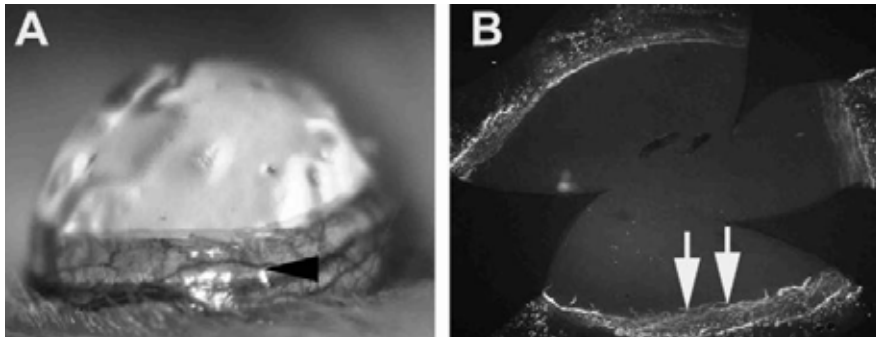
In addition to angiogenesis research, the long-neglected area of lymphangiogenesis research got new momentum and also started to use the cornea as a model (Fig. 3)<sup>11</sup> after the identification of the first lymphatic endothelial “specific” marker and mediator (the VEGF receptor 3) by Kari Alitalo's group in the late 1990's.<sup>11–13</sup> Folkman mentioned that at that time he also got fellows interested in the long disregarded and “unpopular” lymphangiogenesis projects. That resulted, amongst other findings, in the identification of bFGF as a potent lymphangiogenic growth factor.<sup>14</sup> We and others have also relied highly on the cornea as a new model system to study the processes of lymphangiogenesis and its importance in transplant immunology, using the murine model of corneal transplantation.<sup>3,15,16</sup>

We are now at the point to continue the circle from “bedside to bench” back to the bedside, that is, to use the novel insights into angiogenesis and lymphangiogenesis gained in the cornea as a “model system” in the human cornea as a “clinical setting”. The long-term quest for specific antiangiogenic drugs has powerfully moved into clinical medicine in recent years, not only in oncology, but also, for example, in ophthalmology. Drugs such as Bevacizumab (Avastin<sup>®</sup>), Ranibizumab (Lucentis<sup>®</sup>), and Pegaptanib (Macugen<sup>®</sup>) are now mainstay for treatment of age-related maculopathy, the most common form of adult blindness in industrialized countries.

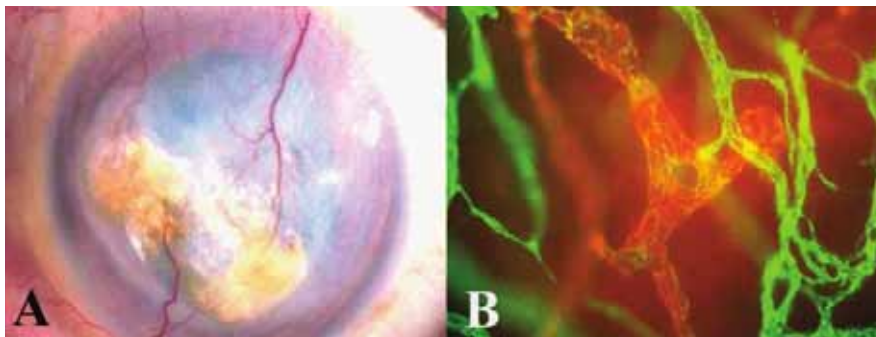
There are no licensed antiangiogenic drugs available for use against human corneal neovascularization yet, so to finally close the circle from the *cornea as an in vivo model* to the *cornea as a place of angiogenic diseases*, we can at least use novel antiangiogenic drugs off-label in patients with sight-threatening corneal angiogenesis. We can now also try to promote corneal graft survival by novel antihem- and especially antilymphangiogenic drugs.<sup>17–19</sup>



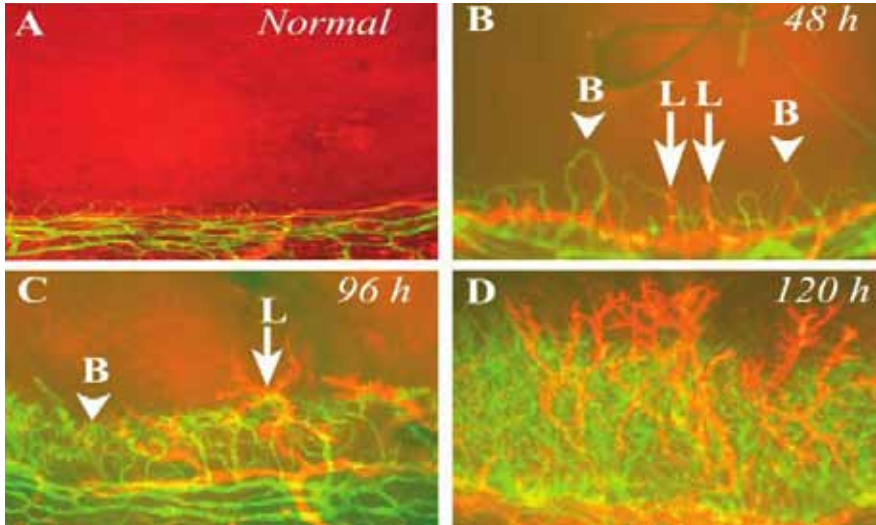
The aim of this review therefore is to (a) highlight the important contributions to angiogenesis research made by Judah Folkman and co-workers, using *the cornea as an in vivo model system*, (b) to outline the progress in lymphangiogenesis research that has been made, again using *the cornea as an in vivo model*, and (c) finally closing the loop to discuss how this progress in research done at the cornea as a model can be used at *the cornea as a place for clinically relevant and sight-threatening neovascular diseases*, using, for example, Bevacizumab (Avastin®) eye drops. In our opinion, this is a perfect example for a successful translational research story, started by Judah Folkman more than 30 years ago, that now slowly comes back from bench to bedside to treat patients with sight-threatening corneal neovascularization and to promote corneal transplant survival.



**FIG. 1.** The normal cornea, the transparent “windscreen” of the eye, is devoid of both blood and lymphatic vessels and therefore is an ideal model system to study the mechanisms of hemangiogenesis and lymphangiogenesis (A). There is a sharp transition from physiologically vascularized conjunctiva to avascular cornea (arrowhead in A and arrows in B). (B) Corneal flatmount stained with CD31 (Ref. 1. Reproduced with permission. © 2006, National Academy of Sciences).



**FIG. 2.** Pathologic, clinically invisible corneal lymphangiogenesis associated with pathologic, clinically visible angiogenesis (A) in a vascularized human cornea, as detected by novel specific immunohistochemical markers for lymphatic endothelium such as LYVE-1 (B). Lymphatic vessels stained in red, blood vessels stained in green with CD31.



**FIG. 3.** Concurrent induction of inflammatory hemangiogenesis (B: blood vessels; stained in green: CD31) and lymphangiogenesis (L: lymphatic vessels; stained in red: LYVE-1) in a murine model of corneal inflammatory neovascularization (A–D) (Ref. 55. Reproduced with permission. © 2004, American Society for Clinical Investigations). Central, normally avascular cornea is at the top, physiologically vascularized conjunctiva at the bottom of each picture (segment of murine corneal flatmount).

**The cornea as the *In Vivo* model system to study the mechanisms of angiogenesis**

Judah Folkman established the basis for research into angiogenesis, not only for tumor angiogenesis, but by using the cornea as a model system also for corneal angiogenesis already in the early 1970’s. Since then, the corneal angiogenesis assay has been one of the best *in vivo* assays for the evaluation of factors influencing angiogenesis.<sup>20</sup> One reason that makes the cornea an ideal object for observing neovascularization is its normal lack of vascularity, maintained by different molecular mechanisms (Fig. 1). New vessels can easily be identified and quantified with the help of computerized image analysis programs (Fig. 4). Therefore, the cornea offers a good possibility for studying corneal hemangiogenesis and recently also lymphangiogenesis *in vivo*. During the last 30 years, Folkman and others achieved many results by the help of a corneal angiogenesis assay.

In 1971, Judah Folkman published a paper in the *New England Journal of Medicine*, where he proposed that, by implanting a tumor into the corneal stroma, tumor growth is depending on angiogenesis.<sup>9</sup> He hypothesized that a tumor can only grow beyond a certain size if it gets connected to the blood system by neo-

vascularization.<sup>9</sup> For this hypothesis, he had to face a lot of skepticism at this time, but over the years Folkman and his co-workers supplied evidence for the theory that now is widely accepted.

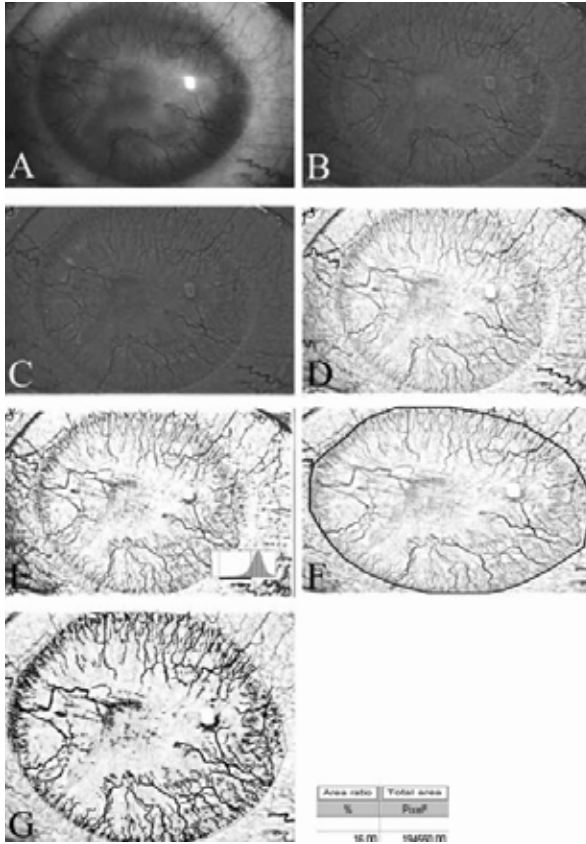
In 1972, Michael Gimbrone and Folkman presented new data collected with the rabbit eye *in vivo* model to support the theory. They demonstrated that small tumor fragments implanted in the anterior chamber did not become vascularized and remained at a small size, whereas fragments, implanted directly on the surface of the iris, introduced neovascularization and tumor size increased exponentially.<sup>21</sup> Based on these data, they considered the possibility to control tumor growth by preventing tumor-induced angiogenesis.

In 1974, Gimbrone *et al.* reported a new experimental model using the rabbit cornea, supporting again that tumor growth is angiogenesis dependent. After intrastromal tumor implantation in the avascular cornea, the tumor size primarily increased at a linear rate. But once the tumor got vascularized, tumor growth was exponential.<sup>22</sup> Using this model, several substances isolated from neonatal scapular cartilage,<sup>8</sup> shark cartilage,<sup>10</sup> and the vitreous<sup>7</sup> were found to have inhibitory effects on the growth of new blood vessels, thereby restricting tumor growth. Similar effects could be shown for medroxyprogesterone, dexamethasone, or cortisone locally applied in sustained release polymer to rabbit V2 carcinoma that was implanted in the rabbit cornea.<sup>23</sup>

The model of implanted intrastromal tumors yielded a good neovascular response, but had deficits in reproducing and quantifying the results because of the inconsistent tumor growth after tumor vascularization.<sup>24</sup>

In 1976, Langer, at that time a postdoctoral trainee in Folkman's laboratory, presented a method of sustained release of biochemically active substances from implanted polymers without the side effect of inflammation.<sup>25</sup> This technique could be combined with the micropocket assay and made it possible to get a reproducible neovascularization response depending on the direct stimulation of blood vessels via different growth factors without the inflammatory stimulus.<sup>26,27</sup>

Briefly, uniformly sized pellets are made of the slow-release polymer Hydron with a certain concentration of growth factors. After pellet implantation in a corneal micropocket, the neovascular response at desired time points can easily be measured and quantified. The corneal micropocket assay, first reported in rabbits,<sup>28</sup> was adapted to mice<sup>29,30</sup> and later on to rats.<sup>31</sup>



**FIG. 4.** Using the cornea to analyze pharmacologic effects of antiangiogenic and antilymphangiogenic drugs is enabled by precise, stepwise morphometry in the normally avascular cornea with absent vascular background “noise” (A–G).

In the last 30 years, the corneal angiogenesis assay provided insights in various fields of angiogenic research: It was used to study angiogenic agents *in vivo* including angiogenin,<sup>32</sup> chondrosarcoma-derived growth factor,<sup>33</sup> adipose tissue<sup>34</sup> and vascular endothelial growth factor VEGF-A,<sup>35</sup> VEGF-C,<sup>36</sup> and -D.<sup>37</sup> It is also a reliable tool for the investigation of angiogenesis inhibitors such as protamine,<sup>38</sup> angiostatin,<sup>39</sup> interleukin<sup>12,40</sup> PEDF,<sup>41</sup> thalidomide,<sup>42,43</sup> and AGM-1470.<sup>44,45</sup> The cornea model was obviously also used to study mechanisms: for example, in 2000, Rohan and coworkers published a paper about the genetic heterogeneity of angiogenesis in mice in which they examined the response to growth factor stimulated angiogenesis in different strains of inbred mice. With the cornea micropocket assay and the *in vitro* aortic ring assay, they could demonstrate a genetic heterogeneity between the different strains that influences angiogenesis.<sup>46</sup> Recently, the corneal neovascularization assay helped to provide an insight into the potential role of platelets for angiogenesis *in vivo*.<sup>47</sup>

Today, more than 50 angiogenesis inhibitors are tested in clinical trials. Some of them have already received Food and Drug Administration (FDA) approval for cancer treatment and macular degeneration (AMD), an eye disease where angiogenesis plays a decisive role. A very successful drug in cancer therapy, Avastin (Bevacizumab®), a monoclonal antibody against vascular endothelial growth factor (VEGF), was approved by the FDA in 2004 for the treatment of metastatic colorectal cancer together with standard chemotherapy and is now widely used off-label for the treatment of AMD and corneal neovascularization.

Although these corneal *in vivo* assays provide a reliable model to study potential angiogenesis stimulators and inhibitors, one should keep in mind that normally the cornea is an avascular tissue and therefore an atypical site for angiogenesis.<sup>20,48,49</sup> This fact suggests that the cornea is an additional model to identify angiogenic and lymphangiogenic inhibitors.<sup>50</sup>

### **The cornea as a new *In Vivo* model to study lymphangiogenesis**

In his last years, Judah Folkman was also active in the upcoming field of lymphangiogenesis research. He and coworkers were able to induce lymphangiogenesis selectively by low concentrations of FGF-2 and were additionally able to inhibit lymphangiogenesis by celecoxib and rofecoxib.<sup>14,51</sup> More recently, he requested that the identification of angiogenesis inhibitors which can also inhibit lymphangiogenesis, or of pure lymphangiogenesis inhibitors, should be investigated for new therapies for the treatment of lymphatic disorders.<sup>52</sup>

Judah Folkman *et al.* demonstrated in 2004 that vascular endothelial growth factor receptor VEGFR3 is essential for the outgrowth of lymphatic vessels in the cornea under noninflammatory conditions.<sup>14</sup>

Based on these initial studies and the finding that LYVE-1<sup>+</sup> lymphatic vessels can be found in pathologically vascularized human corneas,<sup>5</sup> we and others were interested to study the mechanisms of inflammatory corneal lymphangiogenesis and its importance for (corneal) transplant immunology, again using the cornea as a model.

Therefore, it could be shown that besides the classic lymphangiogenic growth factors VEGF-C and -D,<sup>53,54</sup> also the “hemangiogenic” growth factor VEGF-A exerts lymphangiogenic effects *in vivo*.<sup>55</sup> That lymphangiogenic effect was shown to be indirect in nature, predominantly via VEGF-A mediated recruitment of macrophages, which in turn release lymphangiogenic growth factors such as VEGF-C and -D.<sup>55</sup>

Cytokine traps against VEGF-A, as well as selective depletion of macrophages, could completely abrogate an inflammation-induced hem- and lymphangiogenic response in the cornea.<sup>55</sup>

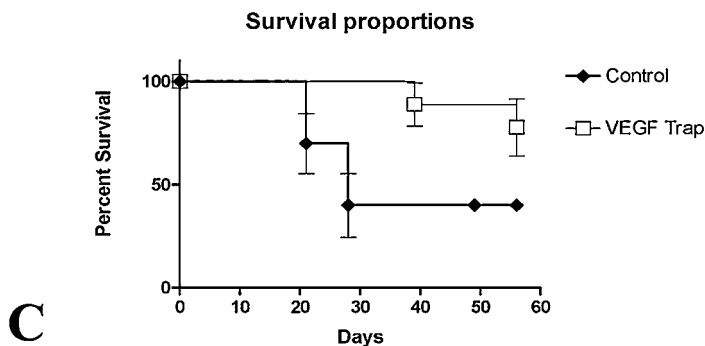
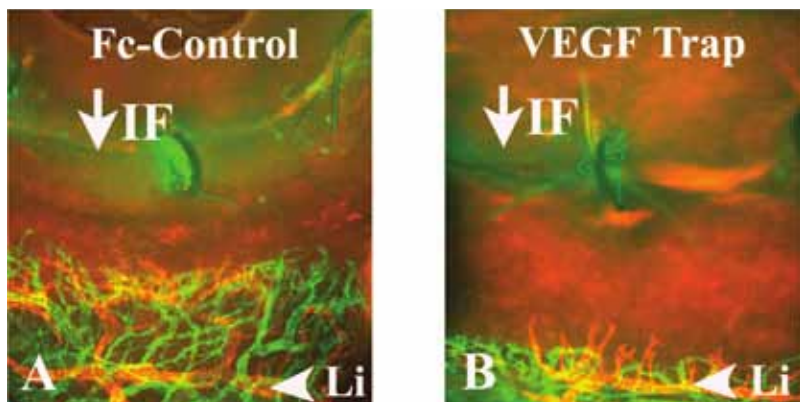
Based on the availability of novel and specific anti(lymph)angiogenic agents, we and others tried to define the interaction between inflammatory lymphangiogenesis and immune responses, especially after transplantation. Using the murine model of corneal transplantation, it could be shown that by inhibiting hem- and even more so lymphangiogenesis, immune reactions after transplantation could be modulated. The new therapeutic concept of immunomodulation by anti(lymph)angiogenic therapy could promote graft survival both in the low-risk as well as in the high-risk model of murine corneal transplantation (Fig. 5).<sup>15,56,57</sup>

Using different tools to specifically inhibit lymphangiogenesis in the cornea (i.e., the VEGFR-3 blocking antibody mF4-31C1<sup>17</sup> and integrin alpha 5-inhibiting small molecules)<sup>58</sup> we were recently able to demonstrate that predominantly lymphatic vessels (i.e., the afferent arm of a so-called immune reflex arc) determine the high-risk status of a prevascularized recipient bed in the cornea. Therefore, the selective blockade of lymphangiogenesis prior to transplantation increased the graft survival nearly up to normal risk graft survival.

Again using the cornea as a model, endogenous and exogenous inhibitors of lymphangiogenesis could be identified: We analyzed, for example, whether the blocking anti- VEGFR3 antibody mF4-31C1 is able to inhibit the outgrowth of pathologic new lymphatic vessels in a mouse model of suture- induced, inflammatory corneal neovascularization. The mF4-31C1 antibody-treated mice displayed nearly complete inhibition of lymphangiogenesis as compared with IgG controls. In contrast, there was no significant inhibitory effect observed with respect to blood vessel growth.<sup>48</sup>

Using the cornea to test a potential antilymphangiogenic effect of a known exogenous angiogenesis inhibitor, it was analyzed whether Bevacizumab can, in addition to inflammatory corneal angiogenesis, also inhibit lymphangiogenesis. The systemic and topical application of Bevacizumab significantly inhibited the outgrowth of blood and lymphatic vessels.<sup>17</sup> Although the binding affinity for murine VEGF is very low, significant binding could be detected by Western blot analysis, ELISA, and a surface plasmon resonance assay.<sup>17</sup> Based on these *in vivo* results, Avastin eye drops, now in use off-label in patients with progressive corneal angiogenesis, should also inhibit human corneal lymphangiogenesis.

The cornea proved also to be very helpful in defining general mechanisms of inflammatory lymphangiogenesis. Maruyama and colleagues could identify a novel mechanism whereby inflammatory lymphangiogenesis takes place, which also adds to the important role macrophages play in inflammatory lymphangiogenesis: Macrophages not only release a whole cocktail of lymphangiogenic growth factors,<sup>55</sup> but also physically integrate into newly formed lymphatic vessels.<sup>16</sup>



**FIG. 5.** Inhibition of hemangiogenesis and lymphangiogenesis promotes graft survival after low-risk corneal transplantation (Ref. 57. Reproduced and modified with permission. © 2004, IOVS). Inhibition of postoperative hemangiogenesis (green: CD31) and lymphangiogenesis (red: LYVE-1) using a VEGF-A cytokine trap significantly promotes graft survival in a murine model of corneal transplantation. (A) Control. (B) VEGF trap. (C) Survival proportions.

## Translation of anti- and antilymphangiogenic therapies into clinical use against corneal neovascularization

As outlined above, tremendous progress has been made in recent years in understanding the basic mechanisms of corneal angiogenesis, and very recently also corneal lymphangiogenesis. In parallel, great efforts have been made to translate the discoveries in angiogenesis research into clinical medicine, primarily in the field of oncology, but also in ophthalmology. VEGF inhibitors such as Bevacizumab (Avastin®), Ranibizumab (Lucentis®), and Pegaptanib (Macugen®) are now the mainstay for treating neovascular forms of age-related maculopathy. They are also widely used off-label for treating diabetic retinopathy, retinal venous occlusions, and neovascular glaucoma.

What about inhibiting corneal neovascularization in the clinic? What about translating antiangiogenesis from the prime *in vivo* model (i.e., the cornea) into clinical therapy? Angiogenesis inhibition at the anterior segment obviously lags behind antiangiogenesis at the posterior pole of the eye, primarily because of industry support for treatment of age-related maculopathy and the burden of blinding retinal disease for an aging society (age-related maculopathy now is the most common blinding disease in the elderly in industrialized countries). Nonetheless, there are numerous indications for antiangiogenic therapy at the anterior segment, and some have already been addressed in clinical trials or using the above mentioned anti-VEGF inhibitors off-label.

Indications for antiangiogenesis at the anterior segment include:

1. Inhibition of corneal neovascularization (either being sight-threatening or being harmful for corneal graft survival),
2. Inhibition of aggressive corneal neovascularization in recurrent pterygia,
3. Inhibition of corneal conjunctivalization in patients with limbal stem cell deficiency (e.g., after chemical burns, or after limbal stem cell transplantation),
4. Modulation of neovascularization and wound healing after filtering surgery for glaucoma patients, and
5. Inhibition of iris neovascularization causing neovascular glaucoma.

In the following, we will focus on current options and future perspectives of angiogenesis inhibition at the cornea. As outlined above, the normal cornea is devoid of both blood and lymphatic vessels and actively maintains that avascularity against a plethora of minor angiogenic stimuli that the cornea, due to its exposed anatomic position, is constantly exposed.<sup>1</sup> This so-called “angiogenic privilege” of the cornea is, for example, responsible for the surprising fact that corneal refractive surgery never causes corneal angiogenesis.

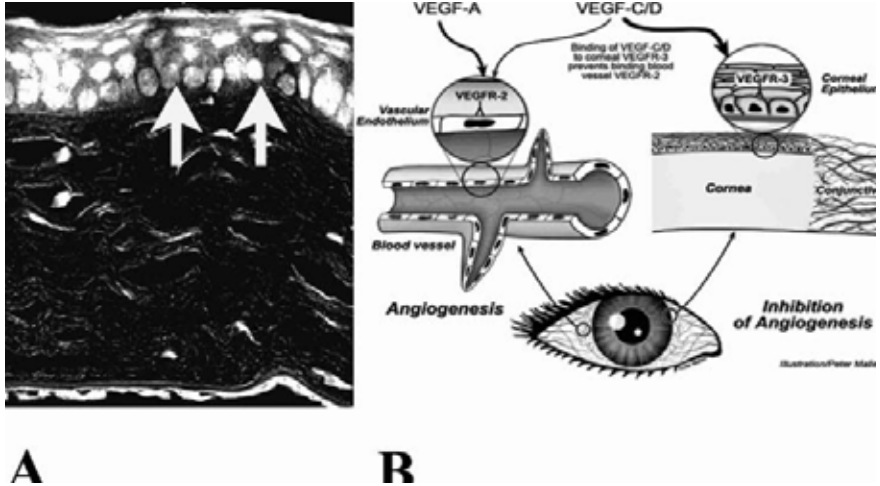


The mechanisms of this corneal angiogenic privilege are redundantly organized and very elaborate, an indication how important evolutionary corneal avascularity was. There are several lines of defense against corneal neovascularization:

- a. Endogenous inhibitors of angiogenesis are located at the inner and outer borders of the cornea. These include inhibitors such as angiostatin, endostatin, thrombospondins, and PEDF, and there are certainly more inhibitors to be identified.<sup>59,60</sup>
- b. Several highly sophisticated receptor decoy mechanisms contribute to corneal avascularity: there is an endogenous natural “trap” for VEGF-C and -D (i.e., the ectopically expressed VEGF receptor 3 in the corneal epithelium) (Fig. 6).<sup>1</sup> Complementary to that trap there is a soluble form of VEGFR1 also expressed in corneal epithelium which neutralizes VEGF-A.<sup>2</sup> In addition, there is a corneal Interleukin 1 receptor antagonist.<sup>61</sup>
- c. The cornea actively tries to prevent hypoxia-driven upregulation of VEGF, first by low if any expression of HIF 1 alpha, and second by expression of IPAS, an inhibitor of hypoxia-driven HIF 1 alpha-signaling.<sup>62</sup>

Nonetheless, several corneal diseases can lead to pathological corneal neovascularization. These can be grouped into diseases causing corneal inflammation (e.g., bacterial and viral forms of keratitis), diseases interfering with the limbal barrier between normally avascular cornea and physiologically vascularized conjunctiva (Fig. 1; e.g., chemical burns or inherited forms of limbal deficiency) and finally diseases presumably leading to corneal hypoxia (i.e., contact lenses with low oxygen penetration).<sup>19</sup> Corneal neovascularization is associated with the second most common cause of blindness worldwide (trachoma) and also with the most common form of corneal blindness in industrialized countries (herpetic keratitis). In fact, corneal neovascularization does not only seem to be a sequel of certain inflammatory corneal diseases, but also may be causative for autoimmune forms of herpetic keratitis.<sup>19</sup>

The clinical sequelae of corneal angiogenesis are several fold: blood vessels growing into the normally avascular cornea reduce corneal transparency and thereby visual acuity. Blood vessels do not only cause blindness by themselves, but also by secondary changes caused by immature corneal blood vessels, that is, lipid deposition in the cornea (lipid keratopathy, Fig. 2), corneal edema and bleeding into the cornea.<sup>19</sup> Furthermore, pathologic blood, and especially lymphatic vessels growing into the cornea, significantly impair the prognosis of a corneal transplantation performed into such a cornea afterwards.<sup>3,4,57</sup> Whereas non-HLA-matched grafts placed into an avascular, so-called low-risk recipient bed enjoy a 5-year survival of around 90%, the survival rate in pathologically prevascularized, so-called high-risk recipient corneas drops to below 50%. Several of these high-risk eyes are not even operated on because of the poor prognosis.<sup>3,4,57</sup>



**A** **R**  
**FIG. 6.** Ectopically expressed VEGF receptor 3 in the corneal epithelium (A) (arrows) acts as a natural sink for angiogenic growth factors VEGF-C and -D and maintains corneal avascularity by preventing the ligation of these factors to their natural receptors on vascular endothelium in the adjacent conjunctiva (B) (Ref. 1. Reproduced and modified with permission. © 2006, National Academy of Sciences); B: with friendly permission from Peter Mallen, Schepens Eye Research Institute, Boston).

Recently, in addition to corneal hemangiogenesis, we could demonstrate the presence of pathological and clinically nonvisible corneal lymphatic vessels in human vascularized high-risk corneas.<sup>5</sup> Immunologically, these lymphatic vessels act as the afferent arc of the immune reflex circle and enable direct access of donor-derived antigen-presenting cells and antigenic material to the regional lymph node, where an immune responses is mounted. Consequently, pre-existing pathologic blood (and clinically invisible lymphatic vessels) constitute the strongest predictor for immune rejections *after* keratoplasty. In addition, we could recently demonstrate that also corneal hem- and lymphangiogenesis occurring only after keratoplasty (both in the low-risk as well as in the high-risk setting) significantly increase the risk of immune rejections.<sup>56,57</sup> Consequently, novel anti-hem-/anti-lymphangiogenic therapies could significantly promote the survival of corneal grafts, both in the murine model of low-and highrisk keratoplasty.<sup>15,57,56</sup> This proved the general feasibility of the new therapeutic concept of immunomodulation by anti(lymph)angiogenic therapy.

Therefore, we and others have focused on how to target pathologic corneal hem- and especially lymphangiogenesis, both causing blindness as well as deteriorating corneal graft survival (both pre-and post corneal transplantation). For the latter purpose, specific inhibitors of lymphangiogenesis are desirable, since these

would probably not interfere with corneal wound healing. Because especially in the context of corneal inflammation, hem- and lymphangiogenesis are closely interrelated,<sup>55</sup> it was so far difficult to specifically target lymphangiogenesis without affecting hemangiogenesis. As outlined above, we and others have recently described several new pharmacological approaches to (relatively) specifically target inflammatory corneal lymphangiogenesis.

These approaches include:

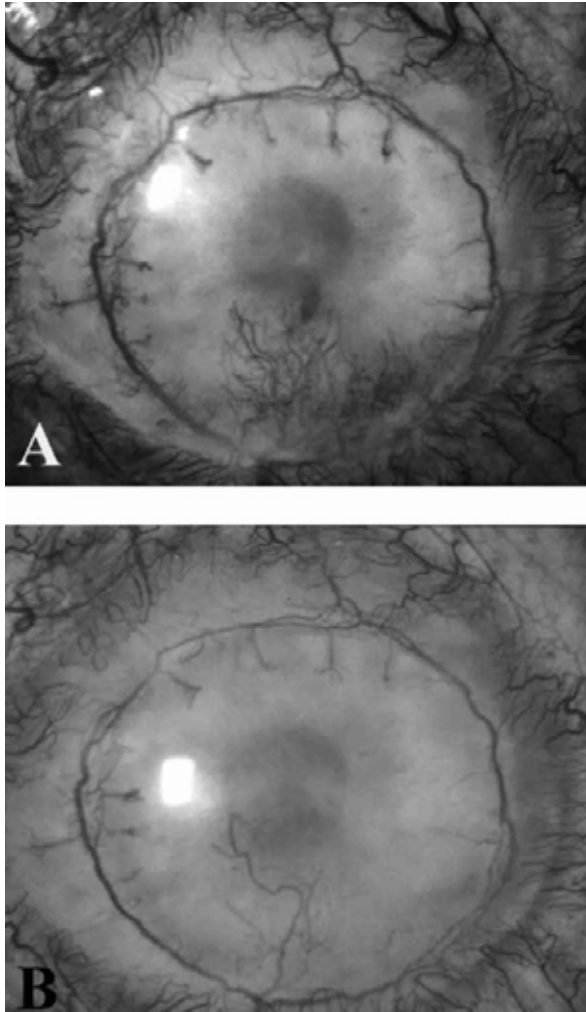
- a. Blocking peptides against integrins expressed on lymphatic vascular endothelial cells.<sup>58</sup> We could show that blocking peptides against integrin alpha 5, being expressed on lymphatic vascular endothelium *in vivo*, at certain concentrations relatively specifically block lymphangiogenesis without affecting hemangiogenesis.<sup>58</sup>
- b. Blocking antibodies against the lymphatic vascular endothelial specific VEGF receptor 3 also have been shown to relatively specifically block inflammatory lymphangiogenesis without affecting hemangiogenesis.<sup>48</sup>

None of these approaches have yet entered clinical trials for use in patients, but they are promising tools for a (relative) specific blockade of lymphangiogenesis in the context of corneal transplantation to promote graft survival.

The current options for corneal angiogenesis inhibition in the clinic primarily include indirect antiangiogenic agents such as anti-inflammatory steroids and cyclosporine A. The only specific antiangiogenic treatment options available are:

- a. The off-label use of anti-VEGF agents such as Bevacizumab (Avastin®), Ranibizumab (Lucentis®), and Pegaptanib (Macugen®), which have been licensed for either anticancer and/or intravitreal use against age-related maculopathy, and
- a. The use of antisense oligonucleotide eye drops against insulin receptor substrate 1 (IRS-1) in the framework of a European multicenter study.

In direct continuation of Folkman and colleagues' experimental studies on the role of VEGF in corneal neovascularization, anti-VEGF pharmacological strategies such as Bevacizumab (Avastin®) translate that concept into clinical application. Indeed, initial experimental studies using several animal models do support an important inhibitory effect of Bevacizumab, Lucentis, and Macugen on corneal neovascularization (Fig. 7).<sup>63-70</sup> Avastin eye drops and Lucentis eye drops in addition have been shown to inhibit corneal lymphangiogenesis in animal models.<sup>17,70</sup>



**FIG. 7.** Avastin (Bevacizumab) eye drops potently stop progressive corneal angiogenesis, lead to partial regression of immature blood vessels and reduced perfusion of mature blood vessels (Ref. 10. Reproduced with permission. © 2007, Springer Verlag). (A) prior to and (B) 4 weeks after additional therapy with Avastin eye drops five times a day in a patient with progressive corneal neovascularization after limbal stem cell deficiency.

The initial clinical experience of using Avastin eye drops or subconjunctival injections also suggests that approach to be a promising tool to target pathologic corneal neovascularization in the clinic.<sup>18,71–74</sup> Our initial patients being treated with Avastin eye drops off-label for pathologic corneal neovascularization unresponsive to conventional therapy showed a significant, but also very variable, response to additional Avastin eye drops when neovascularization was analyzed morphometrically on standardized digitized slit-lamp pictures.<sup>18</sup> All other published case reports or small

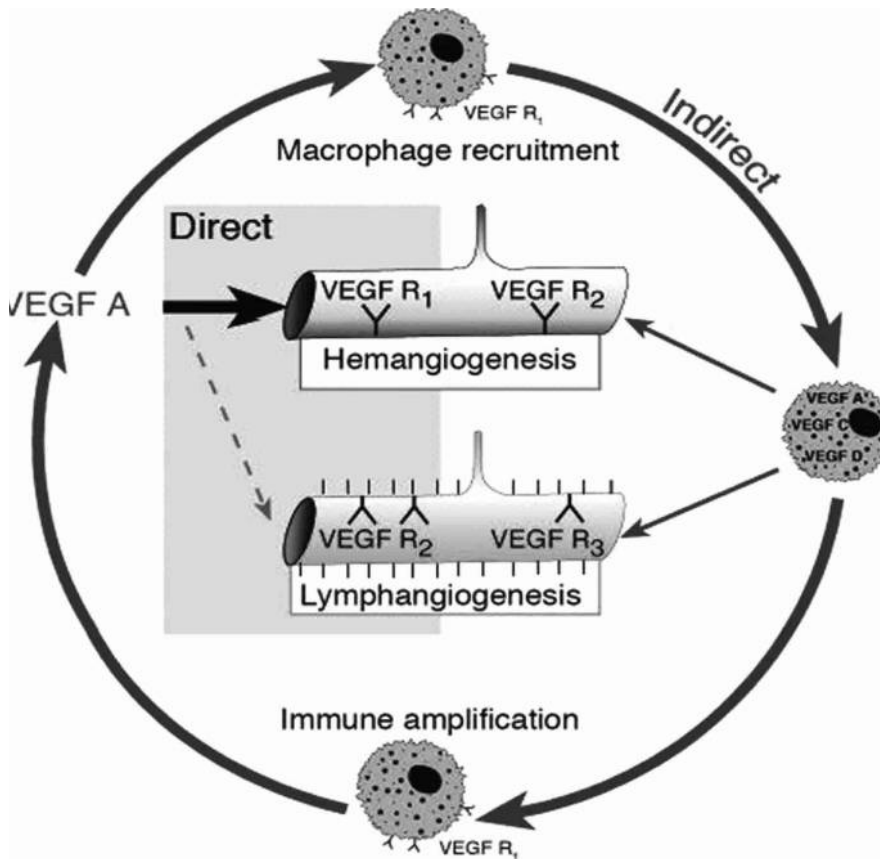
case series support the concept of Avastin eye drops or subconjunctival applications being relatively effective (no controlled trials available yet) and relatively safe (no proper safety studies available yet).<sup>48,71-74</sup> Therefore, prospective randomized studies are necessary to define indications, safety, and effectiveness of that approach in inhibiting corneal neovascularization.

For the other two off-label available anti-VEGF agents, there is much less known about their effect on human corneal neovascularization. Preclinical data show both of them being active against corneal neovascularization, with Ranibizumab, as said above, also being active against corneal lymphangiogenesis.<sup>70</sup> A prospective, multicenter, randomized European phase IIIb study at the moment is investigating the efficacy and tolerability of an antiangiogenic antisense oligonucleotide against IRS-1 applied as eye drops twice daily. Initial interim results suggest the compound to be safe and effective.

What about the safety of topical neutralization of VEGF at the ocular surface? Although the limited evidence from published off-label clinical use of anti-VEGF therapies (primarily Bevacizumab)<sup>18,48,71-74</sup> as well as from *in vivo* and *in vitro* safety studies suggest this specific antiangiogenic approach to be safe, several potential complications have to be kept in mind and observed thoroughly in future studies. If one deducts potential side effects from the known physiological functions of VEGF in the cornea or in the anterior segment of the eye, several potential side effects come into play, especially given the “nonangiogenic” effects of VEGF, that is, its neurotrophic effect, its role in wound healing and inflammation:

- a. Neurotrophic keratopathy: the cornea is one of the most densely innervated tissues of the human body and we know now that VEGF is a potent neurotrophic growth factor.<sup>75</sup> Physiologically, there are trace amounts of VEGF found in normal avascular corneas, so that VEGF in that avascular cornea also might have a neurotrophic effect. Therefore it is quite possible that a long-term anti-VEGF strategy at the cornea may reduce corneal innervation, thus leading to neurotrophic keratopathy or impaired corneal nerve regeneration.<sup>76</sup>
- b. Altered immune responses: VEGF is a known potent chemoattractant for inflammatory cells and an essential component of the “immune amplification cascade” leading to a robust inflammatory response in the cornea.<sup>55</sup> Anti-VEGF strategies may alter that ability to mount an effective immune response (Fig. 8).
- c. Wound healing problems are a well known side-effect of angiogenesis inhibitors in vascularized tissues. But even in the avascular cornea, VEGF may play a role in wound healing. Corneal epithelium (e.g., expresses VEGFR3), which besides neutralizing VEGF-C and -D and thus maintaining

corneal angiogenic privilege, may also have an effect on epithelial proliferation.<sup>1</sup> In addition, VEGFs' known effect on recruitment of inflammatory cells, especially macrophages, may alter corneal stromal wound healing.<sup>55</sup>



**FIG. 8.** Essential role of VEGF-A in immune amplification as evidenced from inflammatory corneal neovascularization models (Ref. 55. Reproduced with permission. © 2004, American Society for Clinical Investigation). Early depletion of either VEGF-A or macrophages completely stops the immune-amplification cascade, leading to inflammatory corneal hemand lymphangiogenesis. VEGF-A has an indirect lymphangiogenic effect via macrophage recruitment.

In summary, in direct continuation of Judah Folkman's initial experimental studies on corneal neovascularization, we now see a late but promising translation of antiangiogenic, primarily anti-VEGF therapies against corneal neovascularization.

Since most of these approaches are yet offlabel uses, we hope that continued research efforts and support from pharmaceutical industry will allow for use of licensed antiangiogenic drugs at the cornea, the prime and long-time in vivo model of angiogenesis, in the near future. That would be a perfect translational research success story from mice to men. And a posthumous salute to Dr. Folkman' research efforts in the field of (corneal) angiogenesis research.

### Disclosure statement

No competing financial interests exist.

### References

1. Cursiefen C, Chen L, Saint-Geniez M, Hamrah P, Jin Y, Rashid S, Pytowski B, Persaud K, Wu Y, Strellein JW, Dana R. Nonvascular VEGF receptor 3 expression by corneal epithelium maintains avascularity and vision. *Proc Natl Acad Sci USA* 2006;103:11405–11410.
2. Ambati BK, Nozaki M, Singh N, Takeda A, Jani PD, Suthar T, Albuquerque RJ, Richter E, Sakurai E, Newcomb MT, Kleinman ME, Caldwell RB, Lin Q, Ogura Y, Orecchia A, Samuelson DA, Agnew DW, St Leger J, Green WR, Mahareshti PJ, Curiel DT, Kwan D, Marsh H, Ikeda S, Leiper LJ, Collinson JM, Bogdanovich S, Khurana TS, Shibuya M, Baldwin ME, Ferrara N, Gerber HP, De Falco S, Witta J, Baffi JZ, Raisler BJ, Ambati J. Corneal avascularity is due to soluble VEGF receptor-1. *Nature* 2006;443:993–997.
3. Cursiefen C. Immune privilege and angiogenic privilege of the cornea. *Chem Immunol Allergy* 2007;92:50–57.
4. Cursiefen C, Kruse FE. New aspects of corneal angiogenesis. In: *Essentials in Ophthalmology*, Kriegelstein GK, Weinreb RN, Eds. Springer; New York (2005).
5. Cursiefen C, Schlotzer-Schrehardt U, Kuchle M, Soroki L, Breiteneder-Geleff S, Alitalo K, Jackson D. Lymphatic vessels in vascularized human corneas: immunohistochemical investigation using LYVE-1 and podoplanin. *Invest Ophthalmol Vis Sci* 2002;43:2127–2135.
6. Campbell FW, Michaelson IC. Blood-vessel formation in the cornea. *Br J Ophthalmol* 1949;33:248–255.
7. Preis I, Langer R, Brem H, Folkman J. Inhibition of neovascularization by an extract derived from vitreous. *Am J Ophthalmol* 1977;84:323–328.
8. Brem H, Folkman J. Inhibition of tumor angiogenesis mediated by cartilage. *J Exp Med* 1975;141:427–439.

9. Folkman J. Tumor angiogenesis: therapeutic implications. *N Engl J Med* 1971;285:1182–1186.
10. Lee A, Langer R. Shark cartilage contains inhibitors of tumor angiogenesis. *Science* 1983;221:1185–1187.
11. Alitalo K, Carmeliet P. Molecular mechanisms of lymphangiogenesis in health and disease. *Cancer Cell* 2002;1:219–227.
12. Alitalo K, Tammela T, Petrova TV. Lymphangiogenesis in development and human disease. *Nature* 2005;438: 946–953.
13. Kaipainen A, Korhonen J, Mustonen T, van Hinsbergh VW, Fang GH, Dumont D, Breitman M, Alitalo K. Expression of the *fms*-like tyrosine kinase 4 gene becomes restricted to lymphatic endothelium during development. *Proc Natl Acad Sci USA* 1995;92:3566–3570.
14. Chang LK, Garcia-Cardena G, Farnebo F, Fannon M, Chen EJ, Butterfield C, Moses MA, Mulligan RC, Folkman J, Kaipainen A. Dose-dependent response of FGF-2 for lymphangiogenesis. *Proc Natl Acad Sci USA* 2004;101: 11658–11663.
15. Chen L, Hamrah P, Cursiefen C, Zhang Q, Pytowski B, Streilein JW, Dana MR. Vascular endothelial growth factor receptor-3 mediates induction of corneal alloimmunity. *Nat Med* 2004;10:813–815.
16. Maruyama K, Ii M, Cursiefen C, Jackson DG, Keino H, Tomita M, Van Rooijen N, Takenaka H, D'Amore PA, Stein-Streilein J, Losordo DW, Streilein JW. Inflammation-induced lymphangiogenesis in the cornea arises from CD11b-positive macrophages. *J Clin Invest* 2005;115: 2363–2372.
17. Bock F, Onderka J, Dietrich T, Bachmann B, Kruse FE, Paschke M, Zahn G, Cursiefen C. Bevacizumab as a potent inhibitor of inflammatory corneal angiogenesis and lymphangiogenesis. *Invest Ophthalmol Vis Sci* 2007; 48: 2545–2552.
18. Bock F, König Y, Kruse F, Baier M, Cursiefen C. Bevacizumab (Avastin) eye drops inhibit corneal neovascularization. *Graefes Arch Clin Exp Ophthalmol* 2008;246: 281–284.
19. Bock F, König Y, Dietrich T, Zimmermann P, Baier M, Cursiefen C. [Inhibition of angiogenesis in the anterior chamber of the eye]. *Ophthalmologe* 2007;104:336–344.
20. Auerbach R, Lewis R, Shinnars B, Kubai L, Akhtar N. Angiogenesis assays: A critical overview. *Clin Chem* 2003; 49:32–40.
21. Gimbrone MA, Jr, Leapman SB, Cotran RS, Folkman J. Tumor dormancy *in vivo* by prevention of neovascularization. *J Exp Med* 1972;136:261–276.
22. Gimbrone MA, Jr, Cotran RS, Leapman SB, Folkman J. Tumor growth and neovascularization: An experimental model using the rabbit cornea. *J Natl Cancer Inst* 1974;52:413–427.
23. Gross J, Azizkhan RG, Biswas C, Bruns RR, Hsieh DS, Folkman J. Inhibition of tumor growth, vascularization, and collagenolysis in the rabbit cornea by medroxyprogesterone. *Proc Natl Acad Sci USA* 1981;78:1176–1180.



24. Li WW, Grayson G, Folkman J, D'Amore PA. Sustained-release endotoxin. A model for inducing corneal neovascularization. *Invest Ophthalmol Vis Sci* 1991;32:2906–2911.
25. Langer R, Folkman J. Polymers for the sustained release of proteins and other macromolecules. *Nature* 1976;263: 797–800.
26. Loughman MS, Chatzistefanou K, Gonzalez EM, Flynn E, Adamis AP, Shing Y, D'Amato RJ, Folkman J. Experimental corneal neovascularisation using sucral-fate and basic fibroblast growth factor. *Aust NZ J Ophthalmol* 1996;24:289–295
27. Kenyon BM, Voest EE, Chen CC, Flynn E, Folkman J, D'Amato RJ. A model of angiogenesis in the mouse cornea. *Invest Ophthalmol Vis Sci* 1996;37:1625–1632.
28. Gimbrone MA, Jr, Leapman SB, Cotran RS, Folkman J. Tumor angiogenesis: Iris neovascularization at a distance from experimental intraocular tumors. *J Natl Cancer Inst* 1973;50:219–228.
29. Muthukkaruppan V, Auerbach R. Angiogenesis in the mouse cornea. *Science* 1979;205:1416–1418.
30. Muthukkaruppan VR, Kubai L, Auerbach R. Tumor-induced neovascularization in the mouse eye. *J Natl Cancer Inst* 1982;69:699–708.
31. Fournier GA, Luty GA, Watt S, Fenselau A, Patz A. A corneal micropocket assay for angiogenesis in the rat eye. *Invest Ophthalmol Vis Sci* 1981;21:351–354.
32. Fett JW, Strydom DJ, Lobb RR, Alderman EM, Bethune JL, Riordan JF, Vallee BL. Isolation and characterization of angiogenin, an angiogenic protein from human carcinoma cells. *Biochemistry* 1985;24:5480–5486.
33. Shing Y, Folkman J, Haudenschild C, Lund D, Crum R, Klagsbrun M. Angiogenesis is stimulated by a tumor-derived endothelial cell growth factor. *J Cell Biochem* 1985;29:275–29287.
34. Silverman KJ, Lund DP, Zetter BR, Lainey LL, Shahood JA, Freiman DG, Folkman J, Barger AC. Angiogenic activity of adipose tissue. *Biochem Biophys Res Commun* 1988;153: 347–352.
35. Phillips GD, Stone AM, Jones BD, Schultz JC, Whitehead RA, Knighton DR. Vascular endothelial growth factor (rhVEGF165) stimulates direct angiogenesis in the rabbit cornea. *In Vivo* 1994;8:961–965.
36. Cao Y, Linden P, Farnebo J, Cao R, Eriksson A, Kumar V, Qi JH, Claesson-Welsh L, Alitalo K. Vascular endothelial growth factor C induces angiogenesis in vivo. *Proc Natl Acad Sci USA* 1998;95:14389–14394.
37. Marconcini L, Marchio S, Morbidelli L, Cartocci E, Albini A, Ziche M, Bussolino F, Oliviero S. *c-fos*-induced growth factor/vascular endothelial growth factor D induces angiogenesis in vivo and in vitro. *Proc Natl Acad Sci USA* 1999;96:9671–9676.
38. Taylor S, Folkman J. Protamine is an inhibitor of angiogenesis. *Nature* 1982;297:307–312.

39. O'Reilly MS, Holmgren L, Shing Y, Chen C, Rosenthal RA, Moses M, Lane WS, Cao Y, Sage EH, Folkman J. Angiostatin: A novel angiogenesis inhibitor that mediates the suppression of metastases by a Lewis lung carcinoma. *Cell* 1994;79:315–328.
40. Voest EE, Kenyon BM, O'Reilly MS, Truitt G, D'Amato RJ, Folkman J. Inhibition of angiogenesis in vivo by interleukin 12. *J Natl Cancer Inst* 1995;87:581–586.
41. Dawson DW, Volpert OV, Gillis P, Crawford SE, Xu H, Benedict W, Bouck NP. Pigment epithelium-derived factor: a potent inhibitor of angiogenesis. *Science* 1999;285:245–248.
42. D'Amato RJ, Loughnan MS, Flynn E, Folkman J. Thalidomide is an inhibitor of angiogenesis. *Proc Natl Acad Sci USA* 1994;91:4082–4085.
43. Kenyon BM, Browne F, D'Amato RJ. Effects of thalidomide and related metabolites in a mouse corneal model of neovascularization. *Exp Eye Res* 1997;64:971–978.
44. Kusaka M, Sudo K, Fujita T, Marui S, Itoh F, Ingber D, Folkman J. Potent anti-angiogenic action of AGM-1470: comparison to the fumagillin parent. *Biochem Biophys Res Commun* 1991;174:1070–1076.
45. Ingber D, Fujita T, Kishimoto S, Sudo K, Kanamaru T, Brem H, Folkman J. Synthetic analogues of fumagillin that inhibit angiogenesis and suppress tumour growth. *Nature* 1990;348: 555–557.
46. Rohan RM, Fernandez A, Udagawa T, Yuan J, D'Amato RJ. Genetic heterogeneity of angiogenesis in mice. *FASEB J* 2000;14:871–876.
47. Kisucka J, Butterfield CE, Duda DG, Eichenberger SC, Saffaripour S, Ware J, Ruggeri ZM, Jain RK, Folkman J, Wagner DD. Platelets and platelet adhesion support angiogenesis while preventing excessive hemorrhage. *Proc Natl Acad Sci USA* 2006;103:855–860.
48. Bock F, Onderka J, Dietrich T, Bachmann B, Pytowski B, Cursiefen C. Blockade of VEGFR3-signalling specifically inhibits lymphangiogenesis in inflammatory corneal neovascularisation. *Graefes Arch Clin Exp Ophthalmol* 2008;246:115–119.
49. Auerbach R, Akhtar N, Lewis RL, Shinnors BL. Angiogenesis assays: Problems and pitfalls. *Cancer Metastasis Rev* 2000;19:167–172.
50. Folkman J. Endogenous angiogenesis inhibitors. *Apmis* 2004;112:496–507.
51. Chang L, Kaipainen A, Folkman J. Lymphangiogenesis new mechanisms. *Ann NY Acad Sci* 2002;979:111–119.
52. Folkman J, Kaipainen A. Genes tell lymphatics to sprout or not. *Nat Immunol* 2004;5:11–12.
53. Karkkainen MJ, Haiko P, Sainio K, Partanen J, Taipale J, Petrova TV, Jeltsch M, Jackson DG, Talikka M, Rauvala H, Betsholtz C, Alitalo K. Vascular endothelial growth factor C is required for sprouting of the first lymphatic vessels from embryonic veins. *Nat Immunol* 2004;5:74–80.

54. Kopfstein L, Veikkola T, Djonov VG, Baeriswyl V, Schomber T, Strittmatter K, Stacker SA, Achen MG, Alitalo K, Christofori G. Distinct roles of vascular endothelial growth factor-D in lymphangiogenesis and metastasis. *Am J Pathol* 2007;170:1348–1361.
55. Cursiefen C, Chen L, Borges LP, Jackson D, Cao J, Radziejewski C, D'Amore PA, Dana MR, Wiegand SJ, Streilein JW. VEGF-A stimulates lymphangiogenesis and hemangiogenesis in inflammatory neovascularization via macrophage recruitment. *J Clin Invest* 2004;113:1040–1050.
56. Bachmann BO, Bock F, Wiegand SJ., Maruyama K, Dana MR, Kruse FE, Luetjen-Drecoll E, Cursiefen C. Promotion of graft survival by vascular endothelial growth factor a neutralization after high-risk corneal transplantation. *Arch Ophthalmol* 2008;126:71–77.
57. Cursiefen C, Cao J, Chen L, Liu Y, Maruyama K, Jackson D, Kruse FE, Wiegand SJ, Dana MR, Streilein JW. Inhibition of hemangiogenesis and lymphangiogenesis after normal-risk corneal transplantation by neutralizing VEGF promotes graft survival. *Invest Ophthalmol Vis Sci* 2004;45:2666–2673.
58. Dietrich T, Onderka J, Bock F, Kruse FE, Vossmeier D, Stragies R, Zahn G, Cursiefen C. Inhibition of inflammatory lymphangiogenesis by integrin alpha5 blockade. *Am J Pathol* 2007;171:361–372.
59. Cursiefen C, Masli S, Ng TF, Dana MR, Bornstein P, Lawler J, Streilein JW. Roles of thrombospondin-1 and -2 in regulating corneal and iris angiogenesis. *Invest Ophthalmol Vis Sci* 2004;45:1117–1124.
60. Chang JH, Gabison EE, Kato T, Azar,DT. Corneal neovascularization. *Curr Opin Ophthalmol* 2001;12:242–249.
61. Kennedy MC, Rosenbaum JT, Brown J, Planck SR, Huang X, Armstrong CA, Ansel JC. Novel production of interleukin-1 receptor antagonist peptides in normal human cornea. *J Clin Invest* 1995;95:82–88.
62. Makino Y, Cao R, Svensson K, Bertilsson G, Asman M, Tanaka H, Cao Y, Berkenstam A, Poellinger L. Inhibitory PAS domain protein is a negative regulator of hypoxia-inducible gene expression. *Nature* 2001;414:550–554.
63. Barros LF, Belfort R, Jr. The effects of the subconjunctival injection of bevacizumab (Avastin) on angiogenesis in the rat cornea. *An Acad Bras Cienc* 2007;79:389–394.
64. Gerard AC, Poncin S, Caetano B, Sonveaux P, Audinot JN, Feron O, Colin IM, Soncin F. Iodine deficiency induces a thyroid stimulating hormone-independent early phase of microvascular reshaping in the thyroid. *Am J Pathol* 2008;172:748–760.
65. Heiduschka P, Julien S, Hofmeister S, Bartz-Schmidt KU, Schraermeyer U. Bevacizumab (avastin) does not harm retinal function after intravitreal injection as shown by electroretinography in adult mice. *Retina* 2008;28:46–55.

66. Hosseini H, Nejabat M, Mehryar M, Yazdchi T, Sedaghat A, Noori F. Bevacizumab inhibits corneal neovascularization in an alkali burn induced model of corneal angiogenesis. *Clin Experiment Ophthalmol* 2007;35:745–748.
67. Manzano RP, Peyman GA, Khan P, Carvounis PE, Kivilcim M, Ren M, Lake JC, Chevez–Barrios P. Inhibition of experimental corneal neovascularisation by bevacizumab (Avastin). *Br J Ophthalmol* 2007;91:804–807.
68. Papathanassiou M, Theodossiadis PG, Liarakos VS, Rouvas A, Giamarellos–Bourboulis EJ, Vergados IA. Inhibition of corneal neovascularization by subconjunctival bevacizumab in an animal model. *Am J Ophthalmol* 2008;145:424–431.
69. Yoeruek E, Ziemssen F, Henke–Fahle S, Tatar O, Tura A, Grisanti S, Bartz–Schmidt KU, Szurman P. Safety, penetration and efficacy of topically applied bevacizumab: evaluation of eyedrops in corneal neovascularization after chemical burn. *Acta Ophthalmol* 2008;86:322–328.
70. Parthasarathy A, Bock F, Onderka J, Kruse FE, Cursiefen C. Pegaptanib (Macugen) and Ranibizumab (Lucentis) eye drops inhibit inflammatory corneal neovascularisation. ARVO 2008. Fort Lauderdale, Florida.
71. Bahar I, Kaiserman I, McAllum P, Rootman D, Slomovic A. Subconjunctival bevacizumab injection for corneal neovascularization. *Cornea* 2008;27:142–147.
72. Bahar I, Kaiserman I, McAllum P, Rootman D, Slomovic A. Subconjunctival bevacizumab injection for corneal neovascularization in recurrent pterygium. *Curr Eye Res* 2008;33:23–28.
73. Erdurmus M, Totan Y. Subconjunctival bevacizumab for corneal neovascularization. *Graefes Arch Clin Exp Ophthalmol* 2007;245:1577–1579.
74. Uy HS, Chan PS, Ang RE. Topical bevacizumab and ocular surface neovascularization in patients with Stevens–Johnson syndrome. *Cornea* 2008;27:70–73.
75. Carmeliet P, Storkebaum E. Vascular and neuronal effects of VEGF in the nervous system: implications for neurological disorders. *Semin Cell Dev Biol* 2002;13:39–53.
76. Cursiefen C, Seitz B, Kruse FE. [Neurotrophic keratitis]. *Ophthalmologe* 2005;102:7–14.
77. Bock F, Onderka J, Hos D, Horn F, Martus P, Cursiefen C. Improved semiautomatic method for morphometry of angiogenesis and lymphangiogenesis in corneal flatmounts. *Exp Eye Res* 2008;87:462–470.

**Claus Cursiefen, MD**  
**Department of Ophthalmology and Interdisciplinary**  
**Center for Clinical Research**  
**Friedrich-Alexander University Erlangen- Nürnberg**  
**Schwabachanlage 6, 91054 Erlangen, Germany**  
**ccursiefen@yahoo.com**

# Immune privilege and angiogenic privilege of the cornea

| Claus Cursiefen, Germany |

---

## Abstract

The cornea is the transparent window of the eye and corneal transparency is essential for good vision. Inflammatory reactions within the cornea cannot only cause tissue destruction and scar formation, but are also associated with angiogenesis and lymphangiogenesis in the cornea. Both inflammation-associated processes interfere with corneal transparency and cause corneal blindness. During evolution the cornea has developed mechanisms for preventing and modulating inflammatory and angiogenic reactions. The fact that the cornea is normally devoid of both blood and lymphatic vessels and actively maintains this avascularity has been termed '*corneal angiogenic privilege*'. Corneal '*immune privilege*', on the other hand, indicates that the cornea is an immune-privileged site and tissue, enabling the extraordinary success of histologically incompatible corneal transplantation. Recent evidence indicates that there is considerable overlap in the molecular mechanisms maintaining corneal '*angiogenic*' and '*immune privilege*'.

Copyright © 2007 S. Karger AG, Basel

Transparency of the cornea, the 'window of the eye', is essential for good vision<sup>[1,2]</sup>. Therefore, evolutionarily developed strategies to interfere with processes that endanger corneal transparency can be explained teleologically. Clinically, the three entities most severely affecting corneal transparency are inflammatory reactions within the cornea, corneal neovascularization, and finally loss of corneal endothelial pump function (either due to degeneration or in the course of inflammation). Inflammation not only causes loss of transparency by the influx of inflammatory cells into the stroma, but also due to secondary changes, e.g. scar formation and destruction of endothelial pump cells. Similarly, corneal neovascularization reduces transparency not only by itself, Immune Privilege and Angiogenic Privilege 51 but also due to leakage of lipids, fluid, and erythrocytes into the cornea<sup>[3, 4]</sup>. Consequently, higher animals have developed strategies for limiting and modulating the response to inflammatory stimuli in the cornea and maintaining corneal avascularity. The first strategy refers to corneal '*immune privilege*'<sup>[1,5-7]</sup>. The normal cornea is devoid of blood and lymphatic vessels and actively maintains this avascularity;

this has been termed '*angiogenic privilege*' (by Streilein), being analogous to immune privilege. This study describes the two interdependent phenomena, their overlapping molecular mechanisms and novel immunomodulatory treatment options based on antihem- and antilymphangiogenic agents, i.e. 'immune privilege through angiogenic privilege' [8].

## Common phenomenology of corneal immune and angiogenic privilege

The normal cornea is avascular and, in contrast to other tissues, does not respond with hem- or lymphangiogenesis in response to the plethora of minor inflammatory and angiogenic stimuli in the cornea, due to its anatomical position, to which it is constantly exposed. Surprisingly, tissue destruction caused by refractive laser procedures never initiates angiogenesis. This suggests active modulation and inhibition of corneal angiogenic responses to minor stimuli, which are physiologically unnecessary and would interfere with corneal transparency (i.e. '*corneal angiogenic privilege*'). By contrast, if an angiogenic response becomes necessary (e.g. in severe, eye-threatening corneal infections), both hem- and lymphangiogenesis can be initiated within hours [9, 10]. In analogy, the extraordinary success of allogeneic corneal transplantation is related to the ocular surface being an *immune-privileged site* and the cornea in addition an *immune-privileged tissue* [11]. Therefore, the cornea has mechanisms actively and passively interfering with the afferent and efferent arms of the immune reflex arc [1].

There are several parallels between these two forms of privilege: first, both are redundant. Several active and passive mechanisms are responsible for corneal immune privilege [5-7]. In analogy, the cornea uses different strategies to maintain avascularity and buffer low-grade angiogenic stimuli. Genetic removal of one or more of the endogenous inhibitors of angiogenesis does not cause spontaneous corneal neovascularization, suggesting multiple backup mechanisms [12]. Second, both forms of privilege are incomplete, i.e. they can be overcome, as shown by immune rejection after keratoplasty and neovascularization during herpetic keratitis. Third, they are actively maintained [12]. Fourth, both are essential for vision and are highly conserved evolutionary. Finally, both forms of privilege are interdependent, i.e. invasion of blood and lymphatic vessels into the cornea abrogates corneal immune privilege [13]. On the other hand, severe corneal inflammation also leads to breakdown of the angiogenic privilege [3].

## Common molecular mechanisms of corneal immune and angiogenic privilege

Novel insights into the molecular mechanisms of hem- and lymphangiogenesis explain the close interrelations between neovascularization and immunity/ inflammation. Most mediators of angiogenesis, e.g. vascular endothelial growth factor (VEGF), which have traditionally been thought of as acting solely on vascular endothelium, also have profound effects on immune and inflammatory reactions. For example, VEGF-A (via its receptor 1: VEGFR1) is a potent chemoattractant for macrophages [3, 10]. VEGF-C, in addition to being the most potent lymphangiogenic growth factor, can recruit dendritic cells via VEGFR3 [14]. Hence, endogenous anti-angiogenic mechanisms targeting these agents have anti-inflammatory effects and also promote both angiogenic and immune privilege. Alternatively, most pro-inflammatory cytokines incite hemand lymphangiogenesis [3]. Neutralization of interleukin-1 almost completely abrogates the angiogenic response to inflammation in the corneal suture model [15]. Endogenous interleukin-1 receptor antagonist expression, therefore, promotes both angiogenic and immune privilege [1]. Indeed, both processes are so closely interrelated that it is nearly impossible to experimentally differentiate the two pathways in the cornea [10].

In addition to immunomodulation by angiogenic growth factors and angiogenesis by pro-inflammatory cytokines, inflammatory cells themselves also play paramount roles in the process of corneal angiogenesis. The immune amplification cascade leading to corneal hem- and lymphangiogenesis after corneal inflammation critically depends on the recruitment of macrophages, which in turn are potent sources for all major hem- and lymphangiogenic growth factors (VEGF-A, VEGF-C, and VEGF-D). Local depletion of macrophages can completely prevent the outgrowth of blood and lymphatic vessels [10].

From the inhibitory perspective, endogenous corneal thrombospondin-1 is an essential inhibitor and downregulator of both inflammatory and neovascular reactions in the course of corneal inflammation [12], and its deficiency leads to significantly prolonged inflammatory reactions and enhanced corneal neovascularization [12].

The close association between angiogenesis/lymphangiogenesis and immune reactions is further exemplified by findings indicating that inflammatory cells (CD11b macrophages), which can express the lymphatic vascular endothelial hyaluronate receptor LYVE-1 under certain pro-inflammatory conditions, cannot only release angiogenic growth factors [10], but also become integral components of inflammation-induced new (corneal) lymphatic vessels in the cornea [16].

Developmentally, corneal angiogenic privilege is established very early: already at fetal stages, the human cornea – in contrast to the adjacent conjunctiva – is devoid of lymphatic and blood vessels [Cursiefen et al., unpublished findings]. Whether corneal immune privilege is already fully active at these early stages is currently not known, but corneal antigen-presenting cells lacking major histocompatibility complex (MHC) class II are not present in fetal corneas before term [17].

Analogy exists between both forms of privilege regarding their anatomy; both have a transition zone at the limbus, where vascularized conjunctiva transitions into avascular cornea and where MHC class II-positive antigen-presenting cells decrease in number [18, 19].

## Corneal immune privilege

There are numerous active and passive mechanisms that contribute to corneal immune privilege via all three aspects of the immune reflex arc [5–7]. These include: lack of blood and lymphatic vessels, reduced numbers of MHC class II-positive antigen-presenting cells, reduced corneal expression of MHC class I, expression of CD95 ligand, an immunosuppressive microenvironment (-melanocyte-stimulating hormone and vasoactive intestinal polypeptide) and the fact that the cornea is part of the anterior chamber with its immune deviant, immunosuppressive mechanism of anterior chamber-associated immune deviation [1, 5–7]. The cornea is not only an immune-privileged site (as shown by low rejection rates after histologically incompatible allografting for example), it is also an immune-privileged *tissue*, which resists immune destruction, as shown by extended survival when transplanted into non-immune-privileged sites [11]. When grafted into a heterotopic site, the alloimmunogenicity of the normal cornea resides within its epithelial and stromal layers, whereas immune privilege arises from the endothelium. In analogy, the cornea is not only an angiogenically privileged *site*, but also an angiogenically privileged *tissue*, as shown by the observation that the cornea remains avascular when transplanted heterotopically to vascularized sites [11].

## Corneal angiogenic and lymphangiogenic privilege

Due to its normal avascularity, the cornea has been the prime *in vivo* model system to study the mechanisms of angiogenesis and lymphangiogenesis [9, 10].

The precise mechanisms of neovascularization in the course of corneal disease are only partly understood. In general, angiogenic growth factors (e.g. the VEGF family) induce angiogenesis by binding to their VEGF receptors on vascular



endothelial cells at the limbal vascular arcade. Stimuli for the release of these factors are inflammation and hypoxia [3, 4]. How the cornea normally prevents in-growth of blood and lymphatic vessels in response to the plethora of minor angiogenic and inflammatory stimuli has only recently gained wider attention [4,8, 12]. As mentioned above, there seem to be several redundant mechanisms in place securing this evolutionarily important privilege. Several anti-angiogenic factors have been localized within the cornea, especially at the inner and outer basement membranes and endothelial/epithelial cells; these include thrombospondin-1, pigment epithelium-derived factor, anti-angiogenic extracellular matrix breakdown products (e.g. angiostatin and endostatin) as well as receptor antagonists, e.g. interleukin-1 receptor antagonist. In addition, aqueous humor seems to contribute to the angiogenic immune privilege of the cornea by sequestering angiogenic growth factors, e.g. by soluble VEGFR1 or heparan sulfate binding of fibroblast growth factor [20, 21]. Nevertheless, the precise mechanisms of this system of buffering low concentrations of angiogenic factors and allowing angiogenesis to occur if this threshold is passed, are still unclear.

Although at least some of the endogenous angiogenesis inhibitors are known, so far, endogenous inhibitors of lymphangiogenesis remain to be determined. The normally alymphatic cornea is an excellent model to study these unknown factors.

## **Immunomodulatory effects of antihem- and antilymphangiogenic therapies in the cornea**

Corneal immune privilege depends on its angiogenic privilege. Consequently, the survival of allogeneic grafts placed in an avascular 'low-risk' recipient bed is very good. By contrast, survival rates dramatically fall when grafts are placed into prevascularized corneal beds (i.e. 'high-risk' keratoplasty). Both mouse experiments [22] and clinical studies [23] have shown that preoperative corneal neovascularization (i.e. loss of angiogenic privilege) is one of the strongest predictors of subsequent immune rejections [23]. Therefore, it was hypothesized that antihem- and antilymphangiogenic therapies could have beneficial effects on corneal graft survival by interfering with the 'afferent and efferent arms' of an immune response. Several recent publications provide 'proof-of-principle' for this novel concept.

Pharmacologic neutralization of VEGF-A using novel cytokine traps completely inhibits hem- and lymphangiogenesis normally produced in the mouse model of suture-induced high-risk keratoplasty [10]. When corneal allografts are placed in these 'avascular high-risk beds', graft survival is significantly higher compared to 'vascularized high-risk beds' [Cursiefen and Streilein, in preparation], indicating an

important role of the lacking angiogenic privilege for the high rate of graft rejections in high-risk settings. Therefore, novel antiangiogenic drugs given during corneal inflammation might prevent the development of a high-risk bed and thereby promote graft survival if future keratoplasty becomes necessary.

If primary prevention fails, secondary prevention has to take place. The most common keratoplasties are performed in low-risk patients who have avascular graft beds. However, even in these situations, about 10% of patients reject their corneal graft and also develop corneal neovascularization postoperatively [24]. Using the mouse model of low-risk keratoplasty, we have recently shown that this mild postkeratoplasty angiogenesis is accompanied by clinically invisible lymphangiogenesis, which compromises corneal immune privilege by providing access to both the afferent and efferent arm of the immune reflex arc [9]. Indeed, in the mouse model of low-risk keratoplasty, both vessel types reached the interface within 1 week of grafting, and inhibition of this postkeratoplasty neovascularization significantly improved graft survival [9]. Moreover, even in prevascularized high-risk graft beds, inhibition of the additional, postoperatively occurring hem- and lymphangiogenesis reduces the risk of subsequent graft rejections [25].

Besides the approaches targeting primarily hem- and lymphangiogenesis, antiangiogenic strategies targeting the immune effects of angiogenic growth factors have recently been shown to be very effective. Blocking antibodies against VEGFR3-mediated migration of dendritic cells to the regional lymph nodes significantly improves corneal graft survival [14]. Likewise, the beneficial effect of local macrophage depletion on corneal graft survival, which has previously been attributed to 'immunologic ignorance' [26], can also be explained by the antihem- and antilymphangiogenic effects of the liposome-depleting agent clodronate [10]. Furthermore, this clodronate-based, macrophage-depleting anti-angiogenic approach could even prolong graft survival in animal models of xenotransplantation [Borges et al., unpublished findings].

Angiogenesis and lymphangiogenesis tend to follow strong inflammatory processes in the cornea [27, 28]. There is evidence that corneal neovascularization, at least in some instances, is not only a result, but can also be a cause of corneal inflammation. The pathogenesis of herpetic keratitis seems to depend on corneal angiogenesis [29]. Anti-angiogenic therapies can prevent herpetic keratitis [29] and, indeed, could become part of future therapeutic regimens against corneal herpes infections.

In summary, due to its immune and angiogenic privilege, the cornea has acquired two fascinating systems to maintain transparency and to preserve vision.

Further unraveling of the molecular mechanisms of these processes will not only allow better understanding of corneal function, but will also provide useful new tools for immunomodulatory and anti-angiogenic/antilymphangiogenic therapies for diseases of the eye and maybe other organs as well<sup>[30]</sup>.

## References

1. Streilein JW: Ocular immune privilege: therapeutic opportunities from an experiment of nature. *Nat Rev Immunol* 2003;3:879–889.
2. Streilein JW: Ocular immune privilege: the eye takes a dim but practical view of immunity and inflammation. *J Leukoc Biol* 2003;74:179–185.
3. Cursiefen C, Kruse FE: New aspects of corneal angiogenesis; in Reinhard T, Larkin F (eds): *Cornea and External Eye*; in Kriegelstein GK, Weinreb RN (ser eds): *Essentials in Ophthalmology*. New York, Springer, 2006, pp 83–99.
4. Chang JH, Gabison EE, Kato T, Azar DT: Corneal neovascularization. *Curr Opin Ophthalmol* 2001;12:242–249.
5. Streilein JW, Yamada J, Dana MR, Ksander BR: Anterior chamber-associated immune deviation, ocular immune privilege, and orthotopic corneal allografts. *Transplant Proc* 1999;31:1472–1475.
6. Niederkorn JY: The immune privilege of corneal allografts. *Transplantation* 1999;67:503–508.
7. Streilein JW: New thoughts on the immunology of corneal transplantation. *Eye* 2003;17:943–948.
8. Cursiefen C, Chen L, Dana MR, Streilein JW: Corneal lymphangiogenesis: evidence, mechanisms and implications for transplant immunology. *Cornea* 2003;22:273–281.
9. Cursiefen C, Maruyama K, Liu Y, Chen L, Jackson D, Wiegand S, Dana MR, Streilein JW: Inhibition of hemangiogenesis and lymphangiogenesis after normal-risk corneal transplantation by neutralizing VEGF promotes graft survival. *Invest Ophthalmol Vis Sci* 2004;45: 2666–2673.
10. Cursiefen C, Chen L, Borges L, Jackson D, Cao J, Radziejewski C, D'Amore PA, Dana MR, Wiegand SJ, Streilein JW: VEGF-A stimulates lymphangiogenesis and hemangiogenesis in inflammatory neovascularization via macrophage recruitment. *J Clin Invest* 2004;113:1040–1050.
11. Hori J, Jouyce N, Streilein JW: Epithelium-deficient corneal allografts display immune privilege beneath the kidney capsule. *Invest Ophthalmol Vis Sci* 2000;41:443–452.
12. Cursiefen C, Masli S, Ng TF, Dana MR, Bornstein P, Lawler J, Streilein JW: Roles of thrombospondin 1 and 2 in regulating spontaneous and induced angiogenesis in the cornea and iris. *Invest Ophthalmol Vis Sci* 2004;45:1117–1124.

13. Dana MR, Streilein JW: Loss and restoration of immune privilege in eyes with corneal neovascularization. *Invest Ophthalmol Vis Sci* 1996;37:2485–2494.
14. Chen L, Hamrah P, Cursiefen C, Jackson D, Streilein JW, Dana MR: Vascular endothelial growth factor receptor-3 (VEGFR-3) mediates dendritic cell migration to lymph nodes and induction of immunity to corneal transplants. *Nat Med* 2004;10:813–815.
15. Cao J, Renard R, Song H, Ioffe E, Mosher V, Rudge JS, Koehler-Stec EM, Yancopoulos GD, Wiegand SJ: Inhibition of IL-1 blocks corneal inflammation and neovascularization. *Invest Ophthalmol Vis Sci* 2003;44:E823.
16. Maruyama K, Li M, Cursiefen C, Jackson DG, Keino H, Tomita M, Van Rooijen N, Takenaka H, D'Amore PA, Stein-Streilein J, Losordo DW, Streilein JW: Inflammation-induced lymphangiogenesis in the cornea arises from CD11b-positive macrophages. *J Clin Invest* 2005;115: 2363–2372.
17. Diaz-Araya CM, Madigan MC, Provis JM, Penfold PL: Immunohistochemical and topographic studies of dendritic cells and macrophages in human fetal cornea. *Invest Ophthalmol Vis Sci* 1995;36:644–656. *Immune Privilege and Angiogenic Privilege* 57
18. Hamrah P, Zhang Q, Liu Y, Dana MR: Novel characterization of MHC class II-negative population of resident corneal Langerhans cell-type dendritic cells. *Invest Ophthalmol Vis Sci* 2002;43: 639–646.
19. Brisette-Storkus C, Reynolds S, Lepisto A, Hendricks RL: Identification of a novel macrophage population in the normal mouse corneal stroma. *Invest Ophthalmol Vis Sci* 2002;43:2264–2271.
20. Lai CM, Brankov M, Zaknich T, Lai YK, Shen WY, Constable IJ, Kovesdi I, Rakoczy PE: Inhibition of angiogenesis by adenovirus-mediated sFlt-1 expression in a rat model of corneal neovascularization. *Hum Gene Ther* 2001;12:1299–1310.
21. Fannon M, Forsten-Willimas K, Dowd CJ, Freedmann DA, Folkman J, Nugent MA: Binding inhibition of angiogenic factors by heparan sulfate proteoglycans in aqueous humor: potential mechanism for maintenance of an avascular environment. *FASEB J* 2003;17:902–904.
22. Sano Y, Ksander BR, Streilein JW: Fate of orthotopic corneal allografts in eyes that cannot support anterior chamber-associated immune deviation induction. *Invest Ophthalmol Vis Sci* 1995;36: 2176–2185.
23. Maguire MG, Stark WJ, Gottsch JD, Stulting RD, Sugar A, Fink NE, Schwartz A; Collaborative Corneal Transplantation Studies Research Group: Risk factors for corneal graft failure and rejection in the collaborative corneal transplantation studies. *Ophthalmology* 1994;101:1536–1547.
24. Cursiefen C, Wenkel H, Martus P, Langenbacher A, Nguyen N, Seitz B, Kuchle M, Naumann GOH: Impact of short-term versus long-term topical steroids on corneal neovascularization after non-high-risk keratoplasty. *Graefes Arch Clin Exp Ophthalmol* 2001;239:514–521.

25. Bachmann B, Lütjen-Drecoll E, Wiegand SJ, Streilein JW, Kruse FE, Cursiefen C: Inhibition of angiogenesis and lymphangiogenesis after high-risk keratoplasty by neutralizing VEGF-A improves corneal graft survival. *Invest Ophthalmol Vis Sci* 2005;46:E4743.
26. Slegers TP, van der Gaag R, van Rooijen N, van Rij G, Streilein JW: Effect of local macrophage depletion on cellular immunity and tolerance evoked by corneal allografts. *Curr Eye Res* 2003;26:73–79.
27. Cursiefen C, Schlötzer-Schrehardt U, Küchle M, Sorokin L, Breitender-Geleff S, Alitalo K, Jackson D: Lymphatic vessels in vascularized human corneas: immunohistochemical investigation using LYVE-1 and podoplanin. *Invest Ophthalmol Vis Sci* 2002;43:2127–2135.
28. Cursiefen C, Ikeda S, Nishina PM, Smith RS, Ikeda A, Jackson D, Mo JS, Chen L, Dana RM, Pytowski B, Kruse FE, Streilein JW: Spontaneous corneal hem- and lymphangiogenesis in mice with *destrin*-mutation depend on VEGFR3 signaling. *Am J Pathol* 2005;166:1367–1377.
29. Zheng M, Schwarz MA, Lee S, Kumaraguru U, Rouse BT: Control of stromal keratitis by inhibition of neovascularization. *Am J Pathol* 2001;159:1021–1029.
30. Cursiefen C, Chen L, Saint-Geniez M, Hamrah P, Jin Y, Rashid S, Pytowski B, Persaud K, Wu Y, Streilein JW, Dana R: Nonvascular VEGF receptor 3 expression by corneal epithelium maintains avascularity and vision. *Proc Natl Acad Sci* 2006;103:11405–11410.

**Dr. Claus Cursiefen, FEBO**  
**Department of Ophthalmology**  
**Friedrich-Alexander University Erlangen- Nürnberg**  
**Schwabachanlage 6, 91054 Erlangen, Germany**  
**ccursiefen@yahoo.com**



# Keratoprosthesis surgery

| Christopher Liu, United Kingdom |

---

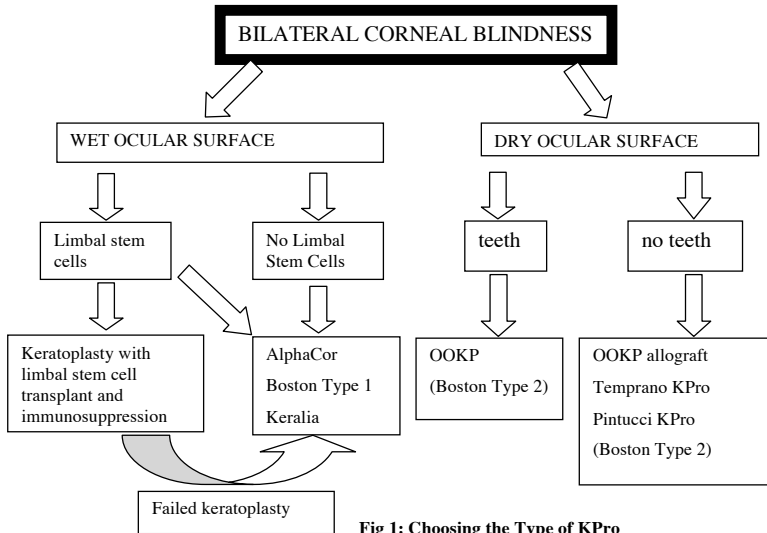
**Salim Okera** (*Anterior Segment Fellow*), **Christopher Liu**

Keratoprosthesis (KPro) surgery is an option for the visual rehabilitation of patients with corneal blindness resulting from conditions where penetrating keratoplasty would have little chance of survival. However, even after over two centuries of refinement it remains complex surgery that is performed by relatively few ophthalmologists, and which is often a last resort for desperate patients who are willing to undertake the many risks in the hope of seeing again.

## Indications<sup>1,2</sup>

The indications for keratoprosthesis surgery encompass two main groups of corneal blindness. In the first group a severely dry eye results in an ocular surface hostile to corneal graft survival, a situation often compounded by inflammation and limbal stem cell loss. Examples in this group include Stevens Johnson syndrome, ocular cicatricial pemphigoid, chemical burns, trachoma, and severe sicca states. While most keratoprostheses are suitable for use in eyes with some tear production, only certain types may be used in severe tear deficiency. In the second group there is a high risk of graft failure due either to a vascularized cornea, or multiple prior graft failures. This latter group lacks the severe tear deficiency and ocular surface inflammation of the former.

Most keratoprosthesis centres will only consider patients who have bilateral severe visual impairment, or blind only eyes. The eye to be rehabilitated should have, as best as can be determined, a functional retina and optic nerve. Patients with visual impairment due to severe optic nerve or retinal pathology will not benefit from a keratoprosthesis. Keratoprosthesis surgery is not a suitable intervention for patients that are unable to comply with the required postoperative care, or those who have unreasonable expectations of the outcome and cosmesis. Paediatric patients are generally not considered for keratoprosthesis surgery.



**Fig 1: Choosing the Type of KPro**

## The ideal keratoprosthesis

The ideal keratoprosthesis should provide excellent visual acuity that is maintained in the long-term. Optically therefore it should have a few aberrations and a specific power. Its biological properties would include biocompatibility with host tissue and resistance to infection. From the surgical viewpoint it should be easy to implant, allow good drug penetration, and have qualities that facilitate postoperative assessment such as intraocular pressure measurements<sup>3</sup>.

Unfortunately, these ideals are not met by any currently available keratoprosthesis. All involve complex surgery with the risk of serious complications, have limited optical qualities and even in the elderly generally do not last for the lifetime of the patient.

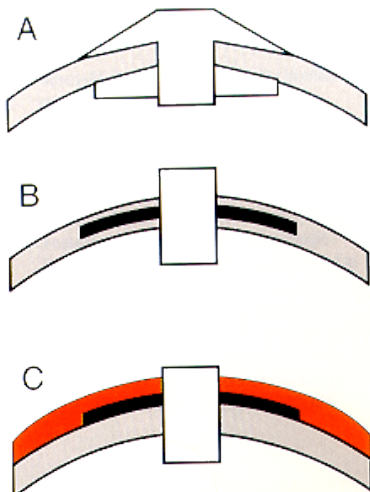
## History<sup>4</sup>

Pellier de Quengsy of Toulouse in 1789 was the first to suggest replacing an opaque cornea with a glass plate. Nussbaum in the 1850s used collar-stud devices consisting of two plates sandwiching the cornea, linked by an optical cylinder. Over the following century all attempts at keratoprosthesis surgery failed due mainly to implant extrusion. In the first half of the twentieth century the increasing success of keratoplasty, especially when combined with improved surgical technique, led many to abandon keratoprosthesis surgery. Filatov in Russia experimented with collar-stud keratoprostheses in the 1930s, but with little success.



In the 1950s a revival in keratoprosthesis research led to a multitude of new designs. All consisted of an optical cylinder, and a skirt to fix the prosthesis to the eye. The design of the skirt was recognized to be a significant factor in the retention of the device. Perforations in the skirt were found necessary to promote the passage of nutrients into the anterior corneal layers, while preventing aqueous humour filtration and eye infection. The large number of designs reflected both the varying ideas on maximizing retention, and the fact that none were uniformly successful. The main problem remained tissue melting around the synthetic material, presumably as a result of mechanical pressure necrosis, disturbance in nutrition, and tissue foreign body reaction. This resulted in leakage, extrusion and endophthalmitis.

Three main approaches were used in the attempt to prevent extrusion. The first was reinforcement of the corneal layers above the supporting skirt with materials such as donor cornea, sclera, periosteum, fascia lata and oral mucosa. The second consisted of varying the depth of corneal fixation, with the skirt being placed either on the corneal surface (epicorneal), in a lamellar pocket of varying depths (intracorneal), or behind the cornea (retrocorneal). Collar-stud devices were also re-invented, the most popular being the Dohlman-Doane and the Cardonna “nut and bolt” KPros (Fig 2).



**Fig 2: Modes of KPro Fixation**

(after Grabner 2004)

A: Collar stud Fixation

B: Intracorneal fixation

C: Epicorneal fixation

The third approach involved using materials that minimized tissue damage, and even allowed integration of KPro and host tissue. Some devices were coupled to corneal allografts. In others, skirts of autograft material such as bone, cartilage and tooth were tried. The use of teeth by Strampelli led to the development of the osteo-odonto-keratoprosthesis. Other researchers focused on the search for porous biologically inert materials capable of being colonized by host tissues, a variety of which were found, including silicone resin, Teflon, Dacron, and soft hydrophilic HEMA polymers. The latter had additional advantages of allowing manufacture of one-piece flexible core-and-skirt devices where both optic and skirt were chemically identical, thereby eliminating interface problems and allowing surgical handling similar to that of a corneal graft.

The retention of keratoprostheses has steadily improved as a result of improved materials and designs, the development of microsurgical techniques, and the discovery of new ways to prevent serious postoperative complications such as glaucoma and infection. Only a few of the many designs developed are in current use, and these are described below.

### **Preoperative assessment**

Due to the complexity, risks and costs of keratoprosthesis surgery, adequate patient selection and assessment is essential.

The ophthalmic history and examination has several goals. The primary diagnosis and its severity, the presence of other ocular co-morbidities especially glaucoma and retinal disease, and the extent of prior surgical intervention must be determined.

Of critical importance are the potential visual acuity and the demonstration of intact retinal and optic nerve function. The presence of a relative afferent pupillary defect and accurate light projection are determined. A B-scan ultrasound is essential to exclude retinal detachment, glaucomatous cupping, exudative maculopathy and pre-phthisis. In some cases a flash ERG and VEP are be useful, although their amplitude may be diminished due to media opacities. Axial length measurement by A-scan ultrasound allows determination of the power of the optical cylinder.

External ocular examination involves an assessment of the lids, fornices, and degree of tear insufficiency. The conjunctiva must be examined for stem cell failure, inflammation, metaplasia or dysplasia and the cornea for vascularization, thinning and prior perforation. The depth of the anterior chamber, synechia, angle status and presence of a crystalline or intraocular lens are noted if visible. The intraocular pressure is determined by tonometry if possible, or digitally.

A detailed psychological assessment must be undertaken, as well as an exploration of the patient's expectations of surgery, and those of their families. They must be given an appreciation of the potential benefits, the risks involved, and the significant commitment in time, finance and travel.

A general medical and anaesthetic assessment is required prior to surgery. Anaesthesia may be complicated by a history of drug reaction in Stevens Johnson patients, and concurrent mucous membrane disease causing difficulties with intubation. Both endotracheal and nasotracheal intubation is required for the separate stages of some devices, as access to the mouth (for mucosal graft harvesting) as well as the eye is required.

### Types of keratoprosthesis

Keratoprostheses generally consist of an optical cylinder, and a skirt for fixation to the eye. The latter is the source of most design variations, and to a large extent determines the retention of the device by the eye.

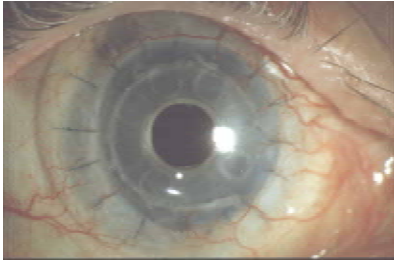
### Non-Integrated Synthetic Skirts:

#### **The Boston KPro (previously known as the Dohlman-Doane KPro)<sup>5-8</sup>**

The Boston KPro (Type 1), under development since 1965 and cleared by the FDA in 1992, is made of PMMA and shaped like a collar button when fully assembled. It is first screwed onto a donor corneal button like a nut and bolt. The graft-prosthesis combination is then transplanted into the patient's cornea. Vision is provided through the clear central stem. A soft contact lens is placed on the eye for permanent use in order to diffuse the evaporative forces and keep the cornea well hydrated. The supporting plate (haptic) is placed entirely behind the graft; holes in the back plate facilitate nutrition and hydration of overlying graft tissue.



**Fig 3A:** (Dohlman 2005)  
Boston Type 1 KPro



**Fig 3B:** (Dohlman 2005)  
*Boston Type 1 KPro in situ*


The crystalline lens, or if pseudophakic the intraocular lens, is removed. The device is custom made for the axial length in aphakia.

The indication for this KPro is graft failure in non-autoimmune disease, where tear and blink mechanisms are reasonably normal and in the absence of longstanding intraocular inflammation. Complications for these indications are rare and retention is excellent. Only if the recipient eye is chronically inflamed or has pre-operative retinal disease or glaucoma can corresponding complications occur (retroprosthetic membrane formation, sterile vitritis, aggravation of glaucoma etc). Prophylactic antibiotic drops, especially vancomycin, have markedly reduced the infection rate. Some success in glaucoma control has been achieved with Ahmed glaucoma valve shunts of new design, with aqueous diverted to distant sites in order to avoid the formation of cicatricial capsules around the shunt plate.

The Boston KPro is the most commonly used device in the USA. About 800 have been implanted. A modified device (Type 2) is available for through the lid implantation in end stage dry eye.

### **The Champagne Cork Keratoprosthesis<sup>9</sup>**

Designed by Jan Worst of the Netherlands and modified by Daljit Singh in India, this consists of a champagne cork or mushroom shaped polycarbonate optic held in place with thin stainless steel wires. The cap of the device is 6 mm in diameter. Wires are threaded through eight holes in the cap, and fitted with needles to allow anchoring of the device in equatorial sclera. The stem is 4.5 mm at the base and narrows to 3.0 mm at the neck, where it joins the cap. Scleral support keeps the cap apposed to the corneal surface, with the intraocular pressure pushing the corneal rim outwards against the back of the cap. The scleral fixation reduces the physical pressure on the cornea and hence the risk of corneal necrosis. However no actual bio-integration of host tissue into the keratoprosthesis can occur.



**Fig 4 A and B:** (Tandon 2005): The Champagne cork KPro

All patients undergo removal of the crystalline or artificial lens at the time of surgery; the optic is available in a standard dioptric strength for an aphakic eye. This KPro is suitable for cases of mild to moderate non-inflammatory dry eye. In severe tear deficiency additional measures such as mucous membrane grafts may be tried.

### **Biological Skirts:**

#### **The Osteo-Odonto-Keratoprosthesis (OOKP)<sup>2, 10-14</sup>**

Described by Strampelli and modified by Falcinelli, the PMMA optical cylinder is cemented into a rectangular block of dentine and surrounding alveolar bone from a harvested canine tooth, some 12-15mm long and 3mm thick. This complex is nourished by a vascular supply that develops from the underlying sclera, surrounding extraocular muscles and an overlying buccal mucous membrane graft. The latter also provides physical and microbiological protection, as the buccal mucosa with time joins with the dento-alveolar ligament, cement and dentine.

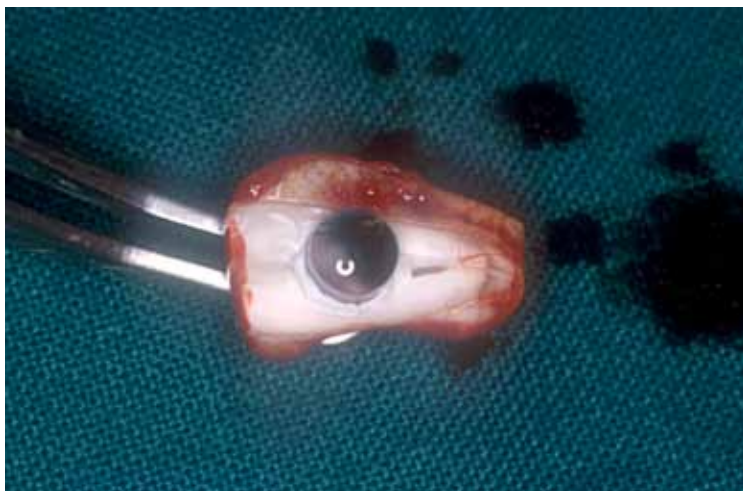
OOKP surgery consists of two stages. In the first stage, a mono-radicular tooth with surrounding alveolar bone is harvested. An osteo-odonto-lamina is prepared by grinding half of the root down to the pulp canal to form a rectangular block. The PMMA optical cylinder is cemented into a hole drilled into the lamina. The complex is then implanted into a sub-muscular pouch in the lower lid of the fellow eye for a period of 2-4 months. During this interval soft tissue invests the bone pores of the lamina. The delay also allows recovery of the lamina from thermal damage, and any infection introduced from the oral cavity can be treated whilst the lamina is sub-muscular rather than on the eye.

Also as part of the first stage, a buccal mucous membrane graft is harvested. After a 360 degree peritomy and removal of the epithelium and Bowman's membrane

from the cornea, the buccal mucosal graft is sutured to the sclera, the rectus muscle insertions, and recessed conjunctiva. It becomes vascularized by the time of Stage 2 surgery, and subsequently provides blood supply to the bone of the OOKP lamina.

In Stage 2, some three months later, the buried lamina is retrieved from its sub-muscular pouch. A flap is made in the buccal mucosal graft and reflected to allow corneal trephination. The lens, iris and anterior vitreous are excised, and the lamina is sutured to the sclera. The buccal mucous flap is repositioned over the device and an opening made for the optic.

The OOKP is the only keratoprosthesis able to withstand a severely dry ocular surface, such as in ocular cicatricial pemphigoid or Stevens Johnson syndrome. The power of the optical cylinder may be chosen based on the axial length of the eye, resulting in excellent visual acuity, but a narrow field of vision. Falcinelli's long-term retention rates and visual results are unmatched by any other keratoprosthesis, with survival analyses indicating an 85% chance of device retention at 18 years after surgery, and a 55% chance of retaining best postoperative visual acuity<sup>14</sup>. For edentulous patients HLA matched tooth allografts from relatives may be used, but immunosuppression is required and retention rates are lower.



*Fig 5A*

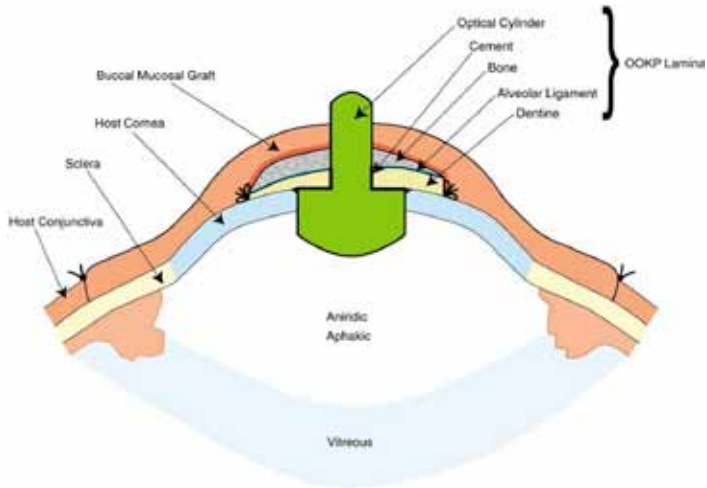


Fig 5B

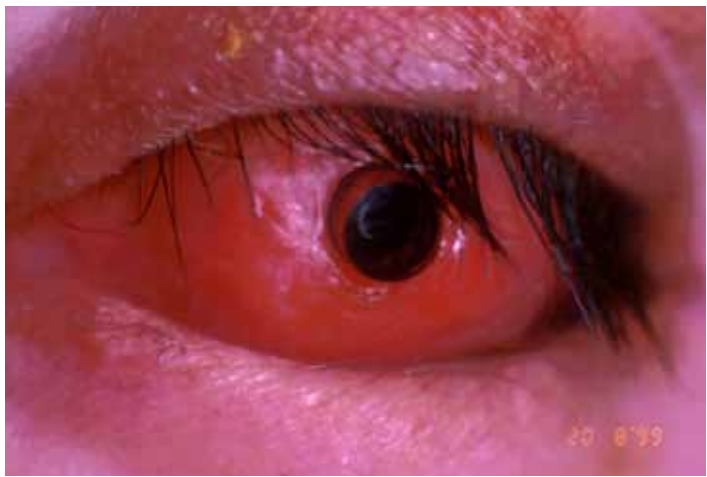


Fig 5C

Fig 5: A: OOKP lamina  
 B: OOKP schematic  
 C: OOKP in situ

## **Osteo-Keratoprosthesis**

This modification of the Strampelli OOKP, developed by Jose Temprano, uses a disc of tibial bone in place of the osteo-dental lamina. Long-term survival rates are lower than those for the OOKP, but it is an option where donor teeth are not available<sup>15,16</sup>.

## **The Coralline Hydroxyapatite (HA)KPro<sup>17</sup>**

Designed by Drs Carlos Leon, Jose Barraquer Snr and Jose Barraquer Jnr, this consists of a 3.5-5mm diameter optic anchored in a hydroxyapatite skirt of 8-10 mm in diameter. The skirt is placed into a corneal lamellar pocket and host stromal tissue invests the pores of the coral. It can also be placed between two corneas or under a rectus muscle flap if the host cornea is too thin. The device has shown good retention in animal models, but there are currently no published human results and the device has been used in a relatively small number of patients.

## **Integrated Synthetic Porous Skirts:**

### **The Pintucci Keratoprosthesis**

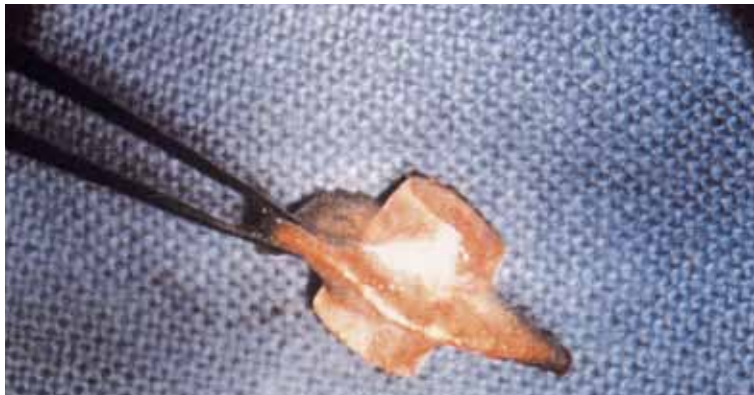The PMMA optic of the Pintucci KPro is surrounded by a porous Dacron skirt which becomes bio-integrated with the patient's connective tissue.

The implantation of the Pintucci device involves two-stage surgery very similar to that of the OOKP. In the first stage a labial mucous membrane graft is harvested, a peritomy performed, corneal epithelium removed, and the graft sutured to the conjunctiva and rectus insertions. The Pintucci device is buried beneath the orbicularis of the lower eyelid where it remains for two months, allowing investment of the skirt by connective tissue and blood vessels.

In Stage 2 surgery, two months later, the device is removed from its sub-muscular pouch and the optical cylinder cleaned of connective tissue. A flap is made in the labial mucosal graft, the cornea trephined, and the iris, lens and anterior vitreous removed. The keratoprosthesis is inserted so that the optic projects into the anterior vitreous, with the Dacron skirt sitting on top of the cornea. The mesh is sutured to the cornea, and the labial mucosa is replaced and trephined to allow protrusion of the KPro.

This KPro has relatively good medium term published retention and visual outcomes<sup>18-20</sup>.





**Fig 6:** *The Pintucci KPro with soft tissue investment*

### **The Retrocorneal Fixation Keratoprosthesis (Lacombe):**

The retrocorneal fixation KPro was designed initially as an all PMMA device maintained in place solely by the force of intraocular pressure on the posterior haptic placed against the corneal vault. Due to a high rate of extrusion with the initial design, subsequent modifications have included a bio-colonizable Teflon (ePTFE) skirt, designed to seal the implant-tissue interface. Despite initial ingrowth of host tissue into the Teflon, subsequent decolonisation, probably due to micro-mechanical trauma leading to apoptosis within the pores, has also resulted in high rates of expulsion. Ongoing design modifications continue<sup>21</sup>.

### **The Legeais BioKpro:**

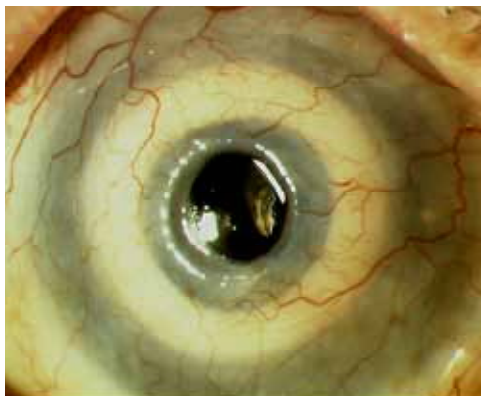
After experimental work demonstrating colonization of microporous PTFE by keratocytes, the multipiece BioKPro I was designed, consisting of a PMMA optic and PTFE skirt implanted in an intralamellar corneal pocket. The KPro was covered with a conjunctival or buccal mucosal flap, which was excised three months after the first stage to expose the optic. A high rate of anatomical failure resulted in the development of the BioKPro II, comprising a transparent soft silicone copolymer core chemically fused to the PTFE skirt, and the most recent modification, the BioKpro III, a similar device with smaller optic and larger skirt designed to enhance bio-colonization. Unfortunately recent published results indicate a very high short term-extrusion rate, due to poor colonisation and chronic inflammation in the skirt<sup>22-24</sup>.

## **Soft (hydrophilic) KPros:**

### **AlphaCor<sup>25-28</sup>:**

The AlphaCor (CooperVision Surgical Perth, Australia) is a flexible poly(2-hydroxyethyl methacrylate (PHEMA) device, with a transparent non-porous core optic and opaque skirt. The peripheral macro-porous skirt region allows bio-integration through tissue ingrowth, preventing leakage and epithelial downgrowth. It is implanted within a lamellar pocket of which the central 3.5 mm posterior to the optic is removed. The optic becomes a full thickness corneal replacement three months later at Stage 2 of the procedure, when tissue anterior to the optic is removed. A Gunderson flap was originally felt to be a necessary adjunct, but is now rarely performed.

Some degree of tear film is needed, as the hydrophilic nature of PHEMA requires a wet environment to provide a good quality refractive surface. An inadequate or inflammatory tear film increases the risk of postoperative stromal melting around the device, and of contact lens type deposition on the optic. Hence the device is mainly used for corneal opacities unsuited to keratoplasty, or in previous graft failures. In these groups the anatomical and visual success rates have been reasonable. A high incidence of stromal melting after implantation in HSV disease has resulted in this being a contraindication to the device. Topically applied medroxyprogesterone has been found to reduce the rate of stromal melting and is routinely used. Heavy smoking may discolour the optic and is also a contraindication to surgery.



**Fig 7:** (Hicks 2005)  
*The AlphaCor in situ*

## **The Supradesmetic Keratoprosthesis (Keralia)<sup>29,30</sup>:**

Designed by Parel, Lacombe and Alfonso in 1990, this KPro, made of pHEMA polymers, is designed to fit directly onto bare Descemet's membrane after deep lamellar dissection. It thus theoretically avoids some of the risks of penetrating KPros such as epithelial downgrowth, fistula formation and endophthalmitis. The central optic is 4.5 mm in diameter and surrounded by an annular skirt of 1.25 mm. It is 350 microns thick in the centre, narrowing to 100 microns at the periphery. Holes are present in the outer haptic for tissue ingrowth and nutrient transfer.

A multi-centre European trial is currently ongoing.

### **Postoperative care:**

Postoperatively, topical and in some cases oral or periocular steroids are administered. Immunosuppression may be required in inflammatory ocular surface diseases. Systemic antibiotics are used for the first week, and topical antibiotics are continued for life.

After discharge from hospital, patients are reviewed weekly. At each visit the keratoprosthesis is checked for complications, the intraocular pressure is digitally palpated and the optic disc and retina examined. B scan is useful for detecting early peripheral detachments. In uncomplicated cases the frequency of visits is reduced, and may be shared with a local ophthalmologist. However the need for regular review remains life-long.

### **Complications:**

Complications may occur at any stage of keratoprosthesis surgery. Many are common to all designs, whereas some are specific to the type of KPro used. Intra-operative complications include vitreous and suprachoroidal haemorrhage, and retinal detachment.

Glaucoma is a major problem after keratoprosthesis surgery, occurring in up to 75% of patients, and is complicated by the unreliable measurement of intraocular pressure and visual field. Many patients eligible for keratoprosthesis surgery have pre-existing glaucoma. Diagnosis rests on a combination of digital palpation, optic disc appearance and gross visual field defects. As penetration of topical medication is uncertain, and systemic acetazolamide has long-term risks, management of intractable glaucoma after keratoprosthesis implantation often involves surgery. Several methods are available, but drainage tubes (Ahmed, Baerveldt) are the most reliable means <sup>2,6</sup>.

After glaucoma, retinal detachment represents the most common sight-threatening risk, and its repair is complicated by the limited view affordable through the optical cylinder. Repair may necessitate removal of the KPro and use of a temporary KPro with a larger field of vision. Endoscopic surgery or the BIOM system may avoid this disadvantage, but the equipment is expensive and there is a learning curve<sup>2,5,6</sup>.

While retroprosthetic membrane formation was common in most artificial keratoprosthesis, it is less frequent with newer designs. It is rare after OOKP because of the removal of the iris, lens and anterior vitreous. If a membrane does develop it may be removed by YAG capsulotomy, or failing this by pars plana approach<sup>2,6</sup>.

Infectious endophthalmitis is devastating for a KPro and may be caused by a variety of organisms. It is less common with improved keratoprosthesis designs, and the use of lifelong topical antibiotic prophylaxis. If suspected, it requires urgent vitreous tap or vitrectomy, injection of intravitreal antibiotics, and topical and systemic antibiotics.

Leakage and extrusion are generally caused by lack of wound healing or stromal melting at tissue interfaces, most commonly between host tissue and the keratoprosthesis. Their incidence has also decreased significantly with research into KPro design and materials.

Each keratoprosthesis is associated with a specific set of complications. For example after OOKP surgery oral complications may occur at the mucosal and dental graft sites such as scarring, infection, and damage to the roots of adjacent teeth or the maxillary sinus. In the long term, resorption of the bone of the OOKP lamina may cause decentration of the cylinder, aqueous leak, extrusion, or endophthalmitis. Mucous membrane thinning and ulceration may result from infection or erosion from a bony spur on the lamina<sup>2,14</sup>.

The prognosis of KPros depends on the preoperative diagnosis, with non-inflammatory graft failures performing best, and inflammatory disorders such as Steven-Johnson syndrome having the highest rates of complications<sup>5</sup>.

### **The future of Keratoprotheses:**

Keratoprotheses have only recently achieved more universal recognition as a useful technique for severe corneal blindness. New materials and designs that improve anatomical success rates, simplify surgery, and reduce complications will result in more widespread acceptance. Optical modifications will improve the visual results of these devices.

Perhaps the most exciting developments lie in the development of corneal tissue replacements. These materials, comprised of natural and synthetic biopolymers, will allow colonization of the major cells of the cornea and will support nerve ingrowth. Their refractive index, transparency and mechanical properties will approach those of the natural cornea.

Currently keratoprosthesis surgery remains a complex procedure that is only offered to patients unable to benefit from keratoplasty. However ongoing research may take us closer to the ideal keratoprosthesis, which combines the technical ease and success rates of keratoplasty with bioengineered tissue that lacks the infective risks and immune reactions of allografting.

*The authors would like to thank the following, who have made personal contributions to this chapter: Griffith M, Hicks C, Tandon R, Maskati Q, Dohlman C, and Leon C.*

## References

1. *Ilhan-Sarac O, and Akpek EK. Current concepts and techniques in keratoprosthesis. Current Opinion in Ophthalmology 2005; 16: 246-250.*
2. *Liu C, Paul B, Tandon R, Herold J, Thorp S et al. The Osteo-Odonto-Keratoprosthesis (OOKP). Seminars in Ophthalmology 2005; 20: 113-128*
3. *Liu C, Tighe B. Striving for the perfect keratoprosthesis. Br. J. Ophthalmol. 1998; 82: 3-4.*
4. *Fyodorov SN, Morov ZI, Zuev VK. Keratoprostheses. Churchill Livingstone 1987; 1-137*
5. *Khan B, Dudenhofer EJ and Dohlman CH. Keratoprosthesis: an update. Curr Opin Ophthalmol. 2001; 12: 282-7*
6. *Dohlman CH, Abad JC, Dudenhofer EJ, Graney JM: Keratoprosthesis. Beyond Corneal Graft Failure. In: Ophthalmic Surgery. Principles and Practice. 3rd ed. Spaeth, G (ed), WB Saunders, Philadelphia , 2002*
7. *Zerbe BL, Belin MW, Ciolono JB and the Boston Keratoprosthesis Study Group. Results from the Multicenter Boston Type 1 Keratoprosthesis Study. Ophthalmology 2006 July (Epub ahead of print).*
8. *Aquavella JV, Qian Y, McCormick GJ, and Palakuru JR. Keratoprosthesis: the Dohlman-Doane device. Am J Ophthalmol. 2005; 140: 1032-1038*
9. *Worst J. Thirty years of experience with the stainless steel anchored artificial cornea Champagne Cork KP. An. Inst. Barraquer 2002; 31: 146*
10. *Barraquer J. Strampelli's Osteo-Odonto-Keratoprosthesis. An. Inst. Barraquer 2003; 32:197-199*

11. Falcinelli GC. *Biological Properties of Strampelli's OOKP and Surgical Improvements of Falcinelli's modified OOKP: Prevention against inflammation. An. Inst. Barraquer 2003; 32: 201-2005*
12. Tandon R, Herold J, Thorp S, Hull C, Britain B, Goldberg L, and Liu C. *Results of the Osteo-Odonto-Keratoprosthesis in Severe Inflammatory Eye Diseases: Experience from the United Kingdom. An. Inst. Barraquer 2003; 32: 219-223*
13. Hille K, Grabner G, Liu C, Colliardo P, Falcinelli G, Taloni M, Falcinelli G. *Standards for Modified Osteodontokeratoprosthesis (OOKP) Surgery According to Strampelli and Falcinelli: The Rome-Vienna Protocol. Cornea 2005; 24: 895-908*
14. Falcinelli G, Falsini B, Taloni M, Colliarso P and Falcinelli G. *Modified osteo-odonto-keratoprosthesis for the treatment of corneal blindness: long term anatomical and functional outcomes in 181 cases. Arch Ophthalmol. 2005; 123:1319-29*
15. Temprano Acedo J. *Advantages of the Autograft Tibial Keratoprosthesis. An. Inst. Barraquer 2002; 31: 146*
16. Temprano J, Alvarez A, Sripattanawat R, Michael R, de la Paz MF, Barraquer RI, Barraquer J. *Osteo-keratoprosthesis using Tibial Autograft: A review of 75 cases. Personal communication*
17. Leon C, Barraquer Jnr JI, Barraquer Snr JI. *Coralline Hydroxyapatite Keratoprosthesis in rabbits. J. Refractive Surg 1997; 13: 74-79*
18. Pintucci S, Pintucci F, Caiazza S, Cecconi M. *New Dacron tissue colonisable keratoprosthesis: clinical experience. Br J Ophthalmol. 1995; 79: 825-9*
19. Pintucci S, Pintucci F, Caiazza S, Cecconi M. *The Dacron Felt colonisable keratoprosthesis after 15 years. Eur J Ophthalmol. 1996; 6: 125-30*
20. Maskati QB, Maskati BT. *Asian Experience with the Pintucci keratoprosthesis. Indian J Ophthalmol. 2006; 54: 89-94*
21. Lacombe E. *Biocolonization: Early Successes and Late Disillusions. An. Inst. Barraquer 2002; 31: 150-151*
22. Alio JL, Mulet ME, Ruiz Moreno JM et al. *Five year follow up of biocolonisable microporous fluorocarbon haptic (BIOKOP) keratoprosthesis implantation in patients with high risk of corneal graft failure. Br.J.Ophthalmol. 2004; 88:1585-1589*
23. Hollick EJ, Watson SL, Dart JKG, Luthert PJ and Allan BDS. *Legeais BioKpro III keratoprosthesis implantation: long term results in seven patients. Br. J. Ophthalmol. 2006; 90: 1146-1151*
24. Mehta JS, Futter CE, Allan BDS et al. *Hydroxyapatite promotes superior keratocyte adhesion and proliferation in comparison with current keratoprosthesis skirt materials. Br. J. Ophthalmol. 2005; 89: 1356-1362*
25. CR Hicks, GJ Crawford, The AphaCor Clinical Investigator Group: *Melts with AlphaCor: Clinical Experience and the effect if MPG. An. Inst. Barraquer 2003; 32, 3-4: 233-235*
26. Crawford GJ, Hicks CR, Constable IJ et al. *The Chirila Keratoprosthesis: Phase I Human Clinical Trial. Ophthalmology 2002; 109: 883-889.*

27. Hicks CR, Crawford GJ, Lou X, Constable IJ et al. Corneal replacement using a synthetic hydrogel cornea, AlphaCor™: device, preliminary outcomes and complications. *Eye* 2003; 17: 385-392.
28. Hicks CR, Helen Fitton J, Chirila TV, Crawford CJ and Constable IJ. Keratopros-theses: Advancing toward a True Artificial Cornea. *Surv. Ophthalmol.* 1997; 42: 175-189
29. Stoiber J, Fernandez, Parel JM et al. Supradescemetic Synthetic Cornea (SDSC): Ex-Vivo Feasibility Study in Human Eye Bank Eyes. *An. Inst. Barraquer* 2003; 32, 3-4: 252-256
30. Stoiber J, Fernandez V, Parel JM et al. Biological response to a supraDescemetic synthetic cornea in rabbits. *Arch Ophthalmol.* 2004; 1222: 1850-5

**Christopher Liu**  
**Consultant Ophthalmic Surgeon**  
**Honorary Clinical Senior Lecturer**  
**Sussex Eye Hospital, Brighton, UK BN2 5BF**  
**cscliu@aol.com**





# Atopic eye disease

| John Dart, United Kingdom |

## Ocular Allergy

This group of disorders, often known as the allergic eye diseases, is probably better referred to as atopic eye diseases to distinguish them from disorders which result from other hypersensitivity mechanisms. The atopic eye diseases comprise a group of 6 disorders which have in common evidence of a Type 1 allergic mechanism together with a papillary conjunctivitis.

### Symptoms

Typically itching, sticky white and stringy mucous discharge. There may be extreme discomfort when severe with soreness and a foreign body sensation.

### Clinical characteristics and distinguishing features

Disease	Disease course	Conjunctival signs	Corneal signs	Disease associations	Diagnostic tests
<b>Seasonal allergic conjunctivitis (SAC)</b>	Onset 5-20 years. Spontaneous remissions common. Rare in old age. Strikingly seasonal	Hyperaemia. Stringy white discharge. Oedema. Micropapillae if severe	None	Personal or family history of atopy	Cytology usually normal. Serum & tear IgE often elevated
<b>Perennial allergic conjunctivitis (PAC)</b>	As for SAC but symptoms all year round with seasonal exacerbations	Hyperaemia, stringy white discharge, micro papillae common	None	Personal or family history of atopy	

<p><b>Atopic keratoconjunctivitis (AKC)</b></p>	<p>Onset between 20-50 years. Chronic course over many years. Spontaneous resolution in old age. Non seasonal</p>	<p>Micropapillae with intense infiltrate. Reticular and sheet scarring. Shortened fornices in some cases. Trantas dots<sup>1</sup>.</p>	<p>Punctate epithelial keratopathy, pannus, macroerosion<sup>2</sup> and plaque<sup>3</sup>. Pseudogerontoxon<sup>4</sup>. Herpes keratitis common.</p>	<p><b>Systemic:</b> atopy and atopic dermatitis. <b>Ocular:</b> staphylococcal lid disease, cataract, keratoconus, herpes simplex keratitis (often bilateral)</p>	<p>Cytology: eosinophils and mast cells. Serum and tear IgE elevated. Skin prick tests positive to many allergens</p>
<p><b>Atopic blepharconjunctivitis (ABC)</b></p>	<p>Do</p>	<p>Micropapillae with intense infiltrate, reticular scarring</p>	<p>None</p>	<p>Personal or family history of atopy</p>	<p>Do</p>
<p><b>Vernal keratoconjunctivitis (VKC)</b></p> <p><b>Palpebral, limbal and mixed forms.</b></p>	<p>Onset between 5-15 years. Spontaneous resolution in 95% after 10 years. Seasonal exacerbations usual</p>	<p><b>Palpebral form:</b> giant upper tarsal papillae often bilaterally asymmetrical. <b>Limbal form:</b> micro-papillae on upper tarsus but gelatinous macropapillae at limbus. Trantas dots in both. <b>Mixed form:</b> combines features of both diseases</p>	<p><b>Palpebral form:</b> punctate epithelial keratopathy affecting upper half of cornea. Adherent mucous appearing as superficial syncytial opacity progressing to macroerosion and vernal plaque. <b>Limbal form:</b> keratopathy extending in from limbus with associated epithelial dysplasia</p>	<p><b>Ocular:</b> keratoconus and cataract. <b>Systemic:</b> atopy in variable proportions from 0-100% depending on geographical location (atopy common in Northern Europe but rare in Middle East).</p>	<p>Do</p>

<b>Contact lens associated papillary conjunctivitis (CLPC) also known as Giant papillary conjunctivitis (GC)</b>	Progressively more common with length of contact lens or prosthesis use	Infiltrate without papillae in some. Micropapillae or giant papillae with scarred apices. Signs often asymmetrical. Mucous discharge, loss of lens tolerance	None	Atopy not strongly associated	Eosinophils in 25% . IgE usually normal
--	---	--	------	-------------------------------	---

1. Trantas dots: white pinhead sized dots consisting of eosinophils and necrotic epithelial cells.
2. Macroerosion: large epithelial erosions usually in upper half of cornea.
3. Plaque (vernal plaque): laminated structure of protein and polysaccharide adherent to the anterior stroma with destruction of Bowmans layer.
4. Pseudogerontoxon: arcus-like appearance in relation to limbal pannus. May disappear in remissions.

### Immunopathogenesis

- Recent advances in the understanding of these diseases have come from investigations of the humoral mediators of inflammation in the tears and analysis of the cellular components by immunostaining. Interactions between the cellular components by cytokine production is being actively investigated by immunostaining and in situ hybridisation. These techniques have shown that SAC and PAC are primarily typical Type 1 hypersensitivity diseases whereas the others show varying degrees of a coexisting Type 4 hypersensitivity response.
- SAC & PAC show mast cells and eosinophils in the conjunctival mucosa and submucosa with high levels of locally produced IgE to specific allergens present in the tears. The diseases can be mimicked by topical instillation of antigen and the reaction to these blocked by drugs active against mast cells ie cromones.
- AKC & VKC show both the cellular components present in SAC & VKC but with massive connective tissue hyperplasia and CD4 T cell lymphocytes, and plasma cells together with MCT mast cells and eosinophils in the epithelium and MCTC mast cells in the substantia propria. The T cells are probably im-

portant inducers of the cellular inflammatory response in these diseases. It is possible that the TH1 subset, predominant in delayed type hypersensitivity responses, that is inactivated by cyclosporine, is more predominant in AKC than VKC in which the TH2 subset, with a B cell helper role, may be more important. Mast cells and eosinophils are found in larger numbers in VKC than in AKC. ABC and GPC show similar cellular components.

- Differences between the disease phenotypes may be explained by functional differences in the effector cell populations - mast cells and eosinophils. There is heterogeneity in the mast cell populations as defined by their neutral protease composition with MCT (mast cells containing tryptase and typically found in the mucosa) predominating in the epithelium and MCTC (tryptase and chymase containing and typically found in the connective tissues) predominating in the substantia propria. MCT mast cells are dependant on T cells for regulation whereas MCTC are not. Although mast cells are important effectors of the allergic response they also have a role as mediators and produce cytokines stimulating the TH2 lymphocyte (IL4), the B cell (IL6) and the eosinophil (IL5). This mediator activity may be important in the early phase of the allergic response before T cells have been recruited. Although MCT mast cells are usually responsive to cromones and MCTC are not the relationship of the mast cell phenotype and function may not hold and functional heterogeneity may depend on the local environment. Functional heterogeneity may also occur in the eosinophil population.
- Adhesion molecules (selectins, integrins and their ligands), which are responsible for lymphocyte homing on involved tissues, are also upregulated in these diseases and may provide another target for therapeutic intervention.
- The role of the effector cells: Mast cells release preformed mediators in “packets” when they degranulate in response to binding of IgE with allergen. This is by exocytosis and the important mediators released are histamine resulting in hyperaemia, oedema and mucous production as well as prostaglandin production. Histamine has been detected in the tears in the atopic conjunctivitis. Eosinophils release cationic proteins including major basic protein. This is epitheliotoxic and has been identified in the tears in VKC. It is probably a major factor responsible for the development of corneal epithelial erosions and macroerosion. The presence of the latter with the mucous and debris present in an acute exacerbation of keratopathy account for the formation of plaque. B cells produce IgE locally in atopic conjunctivitis. Locally produced IgE is an important factor in the pathogenesis of SAC, PAC and some cases of VKC but less so in AKC, ABC & CLPC.

## Diagnosis

- Laboratory investigations only needed in patients not responding to therapy or who require topical (or systemic ) steroid therapy for relief of symptoms.
- Conjunctival cytology for eosinophils and mast cells simple and helpful if positive. Negative in 75% SAC patients and 50% of SAC patients. Usually positive in VKC and AKC. Scrape tarsal conjunctiva with spatula firmly after anaesthetising with benoxinate, smear on glass slide, air dry , fix in methanol and stain with Giemsa (1).
- Serum IgE positive in atopes but not in all patients with atopic eye diseases who may have locally produced IgE. In SAC & PAC only present in 80% of patients. Variable results in VKC and GPC. Very high in AKC(1-3).
- Tear IgE elevated in most all patients with atopic eye diseases (SAC 96% PAC 100%, limbal VKC 80%, palpebral VKC 100% and AKC 100% (1-3) except possibly GPC. Use ophthalmic cellulose surgical sponges to collect tears with modified PRIST radioimmunoassay (4) or Adiatec Tear IgE test if available.
- Biopsy with conventional histology the gold standard. Bulbar snip biopsy and tarsal punch (using 3 mm disposable dermatological punch) but patients MUST be off steroid for 2 weeks before.
- Skin prick tests very variable in VKC depending on population. Positive in AKC, SAC and PAC but not indicative of precipitating allergen; this has only been identified for PAC from locally produced tear IgE.

## Treatment

SAC & PAC: Ketotifen or olopatadine are currently often used as first line therapy as they have combined antihistaminic and mast cell stabilizing effects. However cromones (mast cell stabilizers including sodium cromoglycate 2%, levocabastine and nedocromil) and/or antihistamines (levocabastine or emedastine) may be more effective in some patients. Severe exacerbations may require short periods of topical steroid in addition.

ABC & AKC: These respond poorly to the mast cell stabilizers and/or antihistamines used although these are worth a trial in mild cases. These drops are often not tolerated until the inflammation is brought under

control with high dose topical steroids when they can be introduced as steroid sparing drugs. Pulses of systemic steroids may be needed to bring the diseases under control before substituting topical therapy. The management may be very specialised because of the problems of steroid glaucoma and herpes exacerbations associated with topical and systemic steroids. Oral acyclovir prophylaxis is useful in many patients who often have bilateral HSV keratitis. Systemic therapy with ciclosporin or tacrolimus in younger patients and azathioprine or mycophenolate in older patients (or both combined) are needed in severely affected patients.

**VKC:** Topical mast cell stabilisers/antihistamines are the mainstay of treatment with the addition of the minimal dose of topical steroid that is needed to control exacerbations. Patients and parents should be taught to manage their own diseases with ophthalmological backup. Patients must have immediate access to the ophthalmologist to help manage exacerbations and blinding corneal complications. Systemic therapy, usually with steroids or ciclosporin, is rarely required but may be necessary in very severely affected cases. Cataract and steroid glaucoma are constant iatrogenic threats to vision in severe disease.

**GPC:** Improve the contact lens hygiene and modify the lens fit and material before considering treatment as for SAC. Patients are more easily managed in daily disposable or rigid gas permeable lenses.

### **New approaches to therapy**

Advances in the understanding of the immunopathology will hopefully lead to improved management of these disorders. At present mast cell stabilisers/antihistamines are the mainstay of mild disease and are used to spare the amount of topical steroid needed in severe disease. In severe disease steroids are widely used because of their efficacy and despite their side effects. Their mode of action is very nonspecific and it is hoped that more targeted therapy may be developed. Topical cyclosporine (tacrolimus in Japan) is available commercially in the USA but not in Europe. However trials have been very encouraging and have shown good effect in VKC & AKC as expected from the immunopathogenic findings. New modalities of treatment such as drugs targeting other effector cells like eosinophils, and therapy directed at adhesion molecules and cytokines, remain attractive goals for the future.

**Recommended book chapter:** Hannouche D, Hoang-Xuan T. Allergic conjunctivitis Chapter 3 in *Inflammatory Diseases of the Conjunctiva*. Thieme Stuttgart 2001:53-66

## References

1. Dart et al. *Perennial allergic conjunctivitis: definition, clinical characteristics and prevalence*. *Trans Ophthalmol UK* 1986;105:513-20
2. Tuft SJ, Dart JK, Kemeny. *Limbal vernal keratoconjunctivitis: clinical characteristics and immunoglobulin E compared with palpebral vernal*. *Eye* 1989;3:420-7.
3. Tuft SJ, Kemeny DM, Dart JK, Buckley RJ. *Clinical features of Atopic Keratoconjunctivitis*. *Ophthalmology* 1991;98:150-8.
4. Tuft SJ, Dart JKG. *The measurement of IgE in tear fluid: a comparison of collection by sponge or capillary*. *Acta Ophthalmologica* 1989;67:301-5.
5. Friedlander MH. *Conjunctivitis of allergic origin: clinical presentation and differential diagnosis*. *Surv Ophthalmol* 1993; 38: 105–14.
6. Power WJ, Tughal-Tutkun I, Foster CS. *Long-term follow up of patients with atopic keratoconjunctivitis*. *Ophthalmology* 1998; 105: 637–42.
7. Abelson M, Schaefer K. *Conjunctivitis of allergic origin: immunologic mechanisms and current approaches to therapy*. *Surv Ophthalmol* 1993; 38: 115–32.
8. Tuft SJ, Ramakrishnan M, Seal DV, Kemeny DM, Buckley RJ. *Role of Staphylococcus aureus in chronic allergic conjunctivitis*. *Ophthalmology* 1992; 99: 180–4.
9. Montan PG, van Hage-Hamsten M. *Eosinophil cationic protein in tears in allergic conjunctivitis*. *Br J Ophthalmol* 1980: 556–60.
10. Whitcup SM, Chan CC, Luyo DA, Bo P, Li Q. *Topical cyclosporine inhibits mast cell mediated conjunctivitis*. *Invest Ophthalmol Vis Sci* 1996; 37: 2686–93.
11. Hoang-Xuan T, Prisant O, Hannouche D, Robin H. *Systemic cyclosporine A in severe atopic keratoconjunctivitis*. *Ophthalmology* 1997; 104: 1300–5.
12. Bleik JH, Tabbara KF. *Topical cyclosporine in vernal keratoconjunctivitis*. *Ophthalmology* 1991; 98: 1679–84.
13. Akpek EK, Dart JK, Watson S, Christen W, Dursun D, Yoo S, O'Brien TP, Schein OD, Gottsch JD. *A Randomized Trial of Topical Cyclosporin 0.05% in Steroid-Resistant Atopic Keratoconjunctivitis*. *Ophthalmology* 2004;111:476-82

**John Dart DM FRCS**  
**Moorfields Eye Hospital & Institute of Ophthalmology**  
**j.dart@ucl.ac.uk**





# Meibomian gland dysfunction, Ocular Rosacea

| Thanh Hoang-Xuan, France |

---

## Ocular Rosacea

Ocular rosacea is frequent and its morbidity is far from negligible. Effective treatments are available, but inappropriate treatment can lead to sight-threatening ocular and iatrogenic complications. It can remain isolated, with no cutaneous involvement (acne rosacea), or can precede the cutaneous signs sometimes by several years. Ophthalmologists often fail to identify the cutaneous signs of rosacea, because rosacea is defined by highly pleomorphic criteria. They consist of a combination of signs visible on the face: telangiectasia, flushing, and papules or pustules. The rhinophyma is highly evocative, but it is rare and occurs only in certain advanced forms. Rosacea generally affects middle-aged adults of all races, between 40 and 60 years, but can also occur during childhood.

Meibomian dysfunction is one of the key mechanism of ocular rosacea. It is responsible for tear film instability, excessive tear evaporation, and a dry-eye syndrome. The lipases produced by the bacteria of the commensal flora appear to be indirectly responsible for meibomitis, by favoring lipolysis of the cholesterol esters present in meibum and the release of toxic free fatty acids. Direct lipase toxicity and an immune reaction to an exotoxin produced by commensal bacteria may also play a role in the inflammation associated with ocular rosacea.

The symptoms of ocular rosacea are usually mild, consisting of blepharitis and chronic conjunctivitis, which are linked together. The eyelid margins are hyperemic, irregular and thickened. The orifices of the meibomian glands can be occluded by yellowish, solidified meibum plugs. Digital pressure to the lid margin expresses a more or less viscous and cloudy, sometimes granular or doughy material from the meibomian orifices. There is often a history of chalazia. Ocular manifestations are nonspecific, and may include a burning sensation, a foreign body sensation, irritation, and sometimes itching and visual fluctuations. Many patients themselves complain of a sensation of dryness. The conjunctiva may be white or, on the contrary, diffusely hyperemic.

The best-known ocular complication, albeit rare, is phlyctenular keratoconjunctivitis, with peripheral keratitis and corneal neovascularization. Other complications

include conjunctival fibrosis which can lead to fornix foreshortening, symblepharon formation, and trichiasis, epithelial punctate keratitis, catarrhal infiltrates, peripheral ulcerative keratitis, scleritis and episcleritis. The clinical presentation of ocular rosacea in children is usually phlyctenular keratoconjunctivitis and skin lesions of rosacea are exceptional.

The principal differential diagnoses are dryness, allergy, and toxic conjunctivitis. These diagnoses are particularly difficult to rule out because they can be associated with ocular rosacea.

The patient must be informed from the outset that ocular rosacea is a chronic condition, that treatment will no doubt be lengthy. Daily lid hygiene is the cornerstone in the treatment of ocular rosacea. The eyelids must be warmed by applying for several minutes a facecloth or packs soaked in warm water. The patient must be shown how to perform a firm and effective finger massage of the four eyelids. Finally, the eyes are rinsed with preservative-free saline. Oral tetracycline, its derivatives (oxytetracycline and doxycycline), and minocycline have proven their efficacy in ocular rosacea. The mode of action of the cyclines is not clear. They appear to act by reducing lipase production by staphylococci present in the commensal flora, thereby reducing the release of toxic free fatty acids through meibomian lipid hydrolysis. They also have anticollagenase activity, suppress neovascularization, and have an antichemotactic effect. Tetracycline and its derivatives must be reserved for severe forms of ocular rosacea and their contraindications must be respected. Topical corticosteroid eyedrops are only indicated to control an acute inflammatory exacerbation, and only for a brief period. Topical 2% cyclosporine is very effective in childhood ocular rosacea. Oral cyclines are contraindicated and can be replaced by erythromycin.

***Professor Thanh Hoang-Xuan***  
***Head of Ophthalmology Unit at American Hospital Paris***  
***HOANGXUANT@aol.com***

# Keratoconus and pellucid marginal degeneration: diagnosis and treatment including crosslinking

| François Malecaze , France |

---

## Keratoconus: diagnosis and treatment

The treatment of this disease – a disease which nowadays remains the first indicated cause for corneal transplantation among young adults – is at the beginning of a major turning point in its evolution.

I think it is important, first and foremost, to mention that all these advances have been made possible thanks to a better knowledge of the innermost structure of this mysterious dystrophy. With this aim in view, the numerous biological works, have really brought about the “modern” keratoconus era. The advance of para clinical exploration initially, and most importantly of the topography of the cornea, have allowed to make more and more precise detection of its forme fruste, which are real nightmares for the refractive surgeon. More recent technologies (aberrometry, Scheimpflug rotating camera, genetic studies will no doubt cast a new light on this difficult diagnosis to the point of abnormality.

Contactology has also advanced, with lenses increasingly better fitting lenses that can be adapted to the unusual fitting to the unusual curvatures of keratoconus, offering remarkable safety, quality of vision and comfort. It has allowed to postpone still further for as long as possible the surgical operation which is often dreaded by our young patients. However, though still concerning 20% of these patients, the surgical technique of transplantation has considerably evolved too, thanks to the rapid expansion of lamellar transplantations which today allow to keep the patient’s endothelium and thus lessen the risk of rejection as much as possible. Besides short of obtaining an etiological the treatment of the keratoconus for now thanks to the combined advances of genetic therapy and molecular biology, new preserving strategies are developing, such as corneal collagen cross-linking which is becoming a precious tool in the fight against this dystrophy.

Finally, we are eager to discuss post-LASIK ectasia which is a particular but connected entity, and which will undoubtedly interest all those who practise this kind of surgery.

As you can see, the keratoconus is now an ailment which is the target of many new kinds of diagnostic and therapeutic techniques, which create wonderful hope for all our patients.

***Pr François Malecaze - CRNK Toulouse, France***  
***malecaze.fr@chu-toulouse.fr***

# Bacterial Keratitis

| Joseph Frucht-Pery , Israel |

---

## Management of bacterial Keratitis

Microbial keratitis is a sight-threatening corneal disease. Microbial keratitis is usually associated with predisposing factors. A port of entry, such as epithelial damage, is necessary for development of microbial keratitis for most of the bacteria species. However, in a few exceptions the infection occurs despite intact epithelium such as in cases of *Neisseria Gonorrhoeae*. Contact lens use, trauma, and altered defense mechanisms are the most common predisposing factors for microbial keratitis.

Microbial keratitis starts with red painful eye. Photophobia and decrease of visual acuity are common. Clinical evaluation typically shows epithelial corneal defect with stromal inflammatory infiltration and stromal edema. The severity of signs and symptoms are dependent on type and virulence of the infective bacteria. The most common organisms are staphylococci, streptococci, and *pseudomonas aeruginosa*.

Suspicion of bacterial keratitis requires conducting microbiologic diagnostic tests. These tests include specimen collection from the ulcer for staining and for culturing of bacteria. In patients with advancing ulceration despite antibacterial treatment, the treatment should be discontinued for 24 hours, followed by collection of cultures for diagnostic purpose.

At the present time no single antibiotic therapy can cover appropriately both gram-negative and gram-positive bacteria. Therefore, initial treatment should be broad spectrum and include two antibiotics. Once a single microbe is identified, then appropriate monotherapy can be considered. However, the option of multimicrobial infection should always be kept in mind.

The initial treatment is based on use of topical fortified antibiotics. To achieve bactericidal concentrations of the antibiotics into the cornea, frequent drug administration is required (every 30 – 60 minutes). We suggest drops of Cefazolin 50 mg/ml and one of the aminoglycosides (Gentamicin or Tobramycin) 14 mg/ml. Other combinations including Fluoroquinolones and Vancomycin are also possible under certain conditions. Topical antibiotics are used on an hourly basis, day and night, for the first days. The dose is decreased upon clinical response. The clinical parameters for a positive response to the drugs include decrease of

pain, re-epithelialization of the ulcerations, decrease of the density of the stromal infiltration and edema, and reduction of the inflammation in the anterior chamber.

In cases of prolonged non-healing, one should consider the irritative and toxic effects of the fortified antibiotics, particularly of aminoglycosides and Vancomycin.

Corticosteroid use is very controversial. At the present time, there is no study that clearly shows the advantage of corticosteroid use in active microbial keratitis. Relapse of infection may occur in association with corticosteroid use during infective event in cornea. Corticosteroids can be applied when bacteria were identified and appropriate antibiotic is used with an evidence of clinical response to antibiotic treatments. A variety of rules should be observed while steroids are applied.

Surgical approach is indicated only in extreme events such as perforation or pending perforation. Penetrating keratoplasty in a “hot eye” is the last choice in treating bacterial keratitis.

### **References:**

1. Preferred Practice Pattern Committee, Cornea/External Disease Panel, Bacterial Keratitis, San Francisco: American Academy of Ophthalmology; 2005.
2. Schein, O.D., Glynn R.J., Poggio, E.C., et al.: The relative risk of ulcerative keratitis among users of daily-wear and extended-wear soft contact lenses. A case-control study. Microbial Keratitis Study Group. New England Journal of Medicine 773-778; 1989.

**Prof. Joseph Frucht-Pery**  
**Department of Ophthalmology**  
**Hadassah University Hospital**  
**Jerusalem, Israel**  
**JOSEFR@hadassah.org.il**

# Herpes simplex infections and herpes zoster of the cornea

| Lies Remeyer , The Netherlands |

---

Treatment of herpetic keratitis should be quite simple.

Despite the availability of effective antiviral treatment and potent steroids to suppress inflammation associated with acute herpetic disease, chronic HSV continues to give significant ocular morbidity.

HSV keratitis is a common disease entity with significant morbidity.

The mainstay of a correct treatment protocol for HSV keratitis is linking of the clinical picture to the pathogenesis.

The most commonly used antiviral drugs are acyclovir and trifluridine. Add steroids when there is an immune response and that is it!

Then why do we have difficulties in treating HSV keratitis?

There are multiple mechanisms of disease after ocular HSV infection:

- a. damage from live virus
- b. immune and inflammatory disease
- c. structural damage after HSV infection

## What events take place when the herpes simplex virus enters the eye?

- Viral replication at the endpoint of the sensory nerves: skin, conjunctiva, epithelium, stroma, endothelium, trabecular system, uvea, retina.

- Immune reaction:

The virus can replicate in and destroy corneal epithelial cells, but the permanent loss of vision associated with HSV-1 corneal infection appears to be due to an inflammatory response in the cornea referred to as herpetic stromal keratitis (HSK). Because HSK represents an inflammation that often develops in the absence of replicating virus, HSK usually does not respond to antiherpetic drugs, but can benefit from the anti-inflammatory effects of corticosteroids.

Animal models of HSK: The mouse does develop a delayed onset corneal inflammation that resembles many characteristics of the recrudescence disease

in humans.

Using congenitally nude mice that lack T lymphocytes it was established that HSK did not develop in the absence of T lymphocytes. Nude mice could be rendered susceptible to HSK through adoptive transfer of T lymphocytes and the subpopulation of T cells that regulate inflammation in HSK are CD4+.

The T cell receptors on the CD4+ T cell recognize antigens that are processed, bound to major histocompatibility (MHC) class II molecules, and presented on the surface of antigen presenting cells (APC). Langerhans' cells, normally only present at the limbus, are a very efficient APC population. After HSV infection these Langerhans' cells rapidly migrate into the central cornea. Depletion of corneal Langerhans' cells before HSV-1 infection interferes with the development of inflammation. ( Maybe the recurrent trauma of recrudescence enlarges the number of Langerhans' cells in the central cornea which gives an explanation of the increasing severity after multiple recurrences.)

The presence of Langerhans' cells in the central cornea correlates with the onset and persistence of stromal keratitis .

CD4+ T cells mediate their immunologic functions primarily through the elaboration of soluble cytokines. In HSV-1 infected mice the Th1 cytokines IL-2 and IFN  $\gamma$  are produced, these cytokines play a necessary role in the induction of HSK. Neutralization of these two cytokines can cause a remission of existing HSK. IL-10 is able to inhibit HSK.

Although HSK is regulated by T cells, polymorphonuclear neutrophils (PMN) make up about 90% of the infiltrating cells and are probably responsible for most of the corneal tissue destruction. After HSV corneal infection the focus of inflammation is in the central cornea, whereas the cells that mediate the inflammation arrive via the limbal vasculature. PMN must extravasate from the limbal vessels migrate through avascular tissue and then be activated to maintain viability and release the proteolytic enzymes that degrade the cornea.

Neutralization of IFN  $\gamma$  resulted in a rapid shutdown of extravasation of PMN from peripheral blood vessels. IL 2 neutralization revealed that PMN continued to extravasate but did not show evidence of directed migration into the central cornea. In the central cornea the PMN that were involved in the inflammation undergo apoptotic death when IL-2 is neutralized. Beside these effects blocking IL-2 diminished the effects of IFN-  $\gamma$  as well.

#### **Working model (R.L. Hendricks):**

Activation of CD4+ T cells by viral antigens on the surface of Langerhans' cells initiates a chronic inflammatory response. The activated CD4+ T cells produce IL-2 which enhances IFN $\gamma$  production. The IFN $\gamma$  production upregulates PECAM-1 expression on the vascular endothelium, enhancing PMN extravasation. Both IL-2



and IFN- $\gamma$  appear to contribute indirectly to PMN chemotaxis , which directs the migration of PMN toward the central cornea.

(Is the fact that the central cornea is inflamed most frequently indirect evidence that virus plays a role in HSK? Diffusion of virus out of the subbasal plexus which has its highest innervation in the center of the cornea?)

Once in the central cornea , IL-2 activates the PMN, maintaining their viability and enhancing their release of proteolytic enzymes that contribute to the dissolution of the corneal tissue.

Experimental data support the assumption that HSV stromal keratitis is an immune attack on HSV-infected corneas with delayed type hypersensitivity directed at non-replicating virus-encoded antigens involving cytotoxic and helper T-lymphocytes. The source of the antigen has been debated; it may include residual viral antigen in the corneal stroma after previous epithelial keratitis, concurrent or previous epithelial keratitis, smoldering lytic HSV infection in keratocytes, or recurrence from neuronal or keratocyte latency.

Immune stromal disease also may have an active viral process in addition to immunologic response (Liesegang).

Although fundamental research has elucidated parts of the pathogenesis of HSK, the clinician is not able to define which specific mechanism plays a role at a certain time point, just by slit-lamp examination.

### **Can we define which mechanism plays a role just by slit-lamp examination?**

1. Is there still viral replication in a longstanding dendritic lesion?
2. What is the most important mechanism in stromal keratitis: Viral replication or immune response?
3. There is still discussion about the disease mechanism in endotheliitis.
4. In penetrating keratoplasty conflicting situations can occur.

Furthermore: the clinical classification of herpetic eye disease has been confusing. This is to some degree caused by the descriptive terminology we have been using for the last decades.

Poor and imprecise description of herpetic disease can lead to wrong therapeutic measures.

The clinical choice to be made always amounts to the distinction between

- *active infection,*
- *an immunological reaction to viral antigen or maybe altered host antigen*
- *or structural alteration resulting from viral insult*

The distinction between these three classes of events becomes critical to management decision making, since the cure of one maybe the bane of the other. A sound understanding of each of the clinical manifestations of HSV keratitis is important in properly treating HSV keratitis.

Classification of the disease will help to decide on the treatment regimen and gives clinician and patient an indication which course the disease might take. Prognosis and clinical course are different, visual outcome is dependent on proper recognition and treatment.

Classification related to pathogenesis is crucial to therapeutic success.

Using the classification, proposed by Holland and Liesegang (1999), combined with current concepts about underlying pathology, a treatment regimen is proposed for recurrent and persistent herpetic keratitis.

The classification based on the anatomy and pathophysiology of various presentations of HSV keratitis.

1. First the specific level of the cornea
  - a. epithelium
  - b. stroma
  - c. endothelium
2. Second the cause of the disease
  - a. infectious
  - b. immunologic

**There are four major categories of HSV keratitis:**

1. Infectious epithelial keratitis → active viral replication
2. Stromal keratitis
  - a. immune stromal keratitis → primarily immunologic, possible viral replication or sequestered viral antigens
  - b. necrotizing stromal keratitis → active viral replication combined with severe immune reaction
3. Endotheliitis → immunologic, with a possible infectious component
4. Neurotrophic keratitis → multifactorial, no viral replication, no primary immune reaction.

**General therapeutic considerations:**

**Possible antivirals:**

**Topical**

1. acyclovir ointment 3% 5id
2. trifluridine 1% solution 9id ----> 5id

**Oral antiviral therapy**

tissue absorption is excellent with a tear and aqueous concentration of acyclovir that is 20-40 times the therapeutic dose at 400mg orally five times a day.

**therapeutic dose:**

1. acyclovir 400mg 3id—5id
2. Famciclovir 250mg 3id
3. Valacyclovir 1000mg bid—3id

**prophylactic dose:**

1. Acyclovir 400mg bid
2. Valacyclovir 500mg bid

**1. Infectious epithelial keratitis:**

**Clinical findings:**

- Live virus in epithelium; examination of the anterior stroma beneath the epithelial dendrite may reveal stromal haze which may represent diffusion of viral particles or
- Mild immune response in the superficial stroma  
Epithelium: Corneal vesicles  
Dendritic ulcers  
Geographic ulcers  
Marginal ulcers  
Stroma: Ghost scars

Will heal without scarring within 14-21 days.

Frequent recurrence leads to stromal scarring or thinning that will reduce visual acuity. The frequency of past attack appears to be predictive of future attacks.

## Therapy:

Acute disease:

- a. Gentle debridement and when possible viral culture.
- b. Antiviral therapy: full dose topical or oral therapy therapeutic dose.
- c. **steroids are contraindicated** in pure epithelial infections: worsening of ulceration and prolong the infectious phase. Steroids will suppress the first influx of polymorphonuclear cells which helps clearing the virus.

Prevention of recurrence in pure epithelial disease: in a recurrence rate of 3/year: prophylactic dose.

## 2. Stromal keratitis

Stromal disease may occur through a variety of mechanisms, which probably form a continuum of overlapping disease patterns. One mechanism does not exclude the other.

1. Primarily stromal involvement:
  - Immune stromal keratitis
  - Necrotizing stromal keratitis
2. Secondary after
  - epithelial keratitis
  - trophic keratitis
  - endotheliitis

**Treatment should be directed to the origin of inflammation**

### a. Immune stromal keratitis

#### Clinical findings:

- Live virus?, or sequestered viral antigen
- T-cell mediated immune response

Recurrence of stromal inflammation takes a more severe course. Conform the delayed type hypersensitivity reaction.

Epithelium: Overlying epithelium mostly intact.

Stroma: Infiltrate → combination of cellular infiltrate (mainly T-cells and PMN's) and edema as sequel of inflammation no endothelial dysfunction

Immune ring → might represent antigen-antibody-complement immune complexes (= Wessely Ring), analogous to an Ouchterlony zone in agar plates.  
*The ring like shape is the hall-mark of local antigen production in the presence of an already immunized patient*

Scarring →

Thinning →

Neovascularization → at any level in the cornea, lipid deposition as a result of longstanding leaking neovascularization

## Therapy:

*Antiviral therapy:* topical

1. Acyclovir ointment 3% 5id
2. Trifluridine 1% solution 9id -----> 5id

Systemic:

In chronic cases oral acyclovir can avoid surface toxicity of topical antiviral agents used prophylactically during steroid treatment.

Oral antiviral therapy is ineffective in acute stromal disease, although visual acuity improved over 6 months in significantly more patients when treated with oral acyclovir. Oral acyclovir is useful as a year course to prevent recurrences. However in the setting of HSV keratouveitis the addition of oral acyclovir appeared to be beneficial but the results were not statistically significant.

*Steroids:* If steroids have never been previously used in the eye one should try to do withheld them as the process may burn itself out spontaneously. However when the inflammation progresses steroids should be given.

Indication for topical steroids:

1. the visual axis is threatened
2. severe stromal inflammation
3. active neovascularization
4. steroids have been used previously

Steroid dosage range:

Very severe infiltration: prednisolon **1%** or dexamethason 0.1% 8id  
Mild recurrence: prednisolon 0.125% 2-3id

Steroid tapering:

start when edema and hyperemia are resolving.

Too rapid steroid taper or cessation of treatment may be accompanied by recrudescence of disease: slow taper with reductions of no less than 50% of current steroid dosage. (dose reduction or frequency reduction)

concomitant antiviral therapy should be continued until dose is  $\leq$  prednisolon **1%** 1 daily = dexamethason **0.1%** bid

The Vasculatisation may regress to leave ghost vessels

The clinical course of ISK is chronic, recurrent inflammation that can persist for years.

## **b. Necrotizing keratitis**

**Clinical findings:** Necrosis, ulceration and dense infiltration.

- Viral invasion of stroma
- Severe immune reaction

The replicating virus and the severe host inflammatory response lead to destructive intra-stromal inflammation, progressive thinning of the cornea and may lead to perforation within a short period of time.

Clinical findings may resemble severe bacterial ulcer.

Epithelium:	With or without epithelial defect. The epithelium may break down over the stromal abscess with edema, ulceration and stromal neovascularization.
Stroma:	Necrosis Ulceration Gray or white dense infiltration, diffuse or localized abscesses Edema Neovascularization
Endothelium:	Keratic precipitates
Uvea:	Severe iritis with synechiae, hypopion Secondary glaucoma

### Therapy:

*Antiviral therapy:* control of the infectious process should precede attempts to modulate the immune response. Topical (and probably oral) antiviral therapy should be administered at least 2 days before steroid treatment is started.

topical combined with oral antivirals:

topical

1. acyclovir ointment 3% 5id
2. trifluridine 1% solution 9id -----> 5id

oral

1. acyclovir 400 mg tid -5id
2. Famciclovir 250mg tid
3. Valacyclovir 1000mg bid

### 3. Endotheliitis

**Clinical findings:** Corneal stromal edema without stromal infiltration: Keratic precipitates underlying the stromal and epithelial edema and anterior chamber inflammation.

- Immune reaction on infected endothelium
- Live virus?, Viral antigens?

- Endothelium: Keratic precipitates
- Disciform
  - Linear
  - Diffuse
- Stroma: Secondary edema  
No infiltration  
No neovascularization
- chronic phase: Scarring  
secondary neovascularization  
permanent endothelial decompensation
- Epithelium: normal, chagrin, bulla
- Uvea: Iritis
- Secondary elevated eye pressure  
Primary trabeculitis  
Inflammatory cells blocking aqueous outflow

**Therapy:**

HSV trabeculitis can be considered as a peripheral endotheliitis or limbitis. It presents with sectorial or circumferential redness and an elevated eye pressure. Topical steroids decrease the eye pressure quickly.

#### 4. Trophic keratopathy

Oval shaped, thickened grayish borders with loose epithelium, the area of epithelial defect often reveals a subtle haziness to the anterior stroma.

- Impaired innervation
- Damaged epithelial basement membrane
- Decreased tear secretion
- Stromal inflammation
- Exacerbation by: toxicity from topical medication
  - Topical drug toxicity may occur with prolonged treatment of topical antivirals and may be confused with the disease itself. Gentamycin, Acyclovir.



Epithelium: punctate epithelial erosions  
epitheliopathy  
Persistent epithelial defect

Stroma: Inflammation  
Melting  
Scarring

Complications of trophic keratopathy:

- Stromal scarring
- Neovascularization
- Necrosis
- Perforation
- Secondary bacterial infection

### **Therapy:**

*No stromal loss:*

- *Lubrication with artificial tears or autologous serum*
- *Therapeutic soft contact lens with antibiotic prophylaxis*
- *Discontinue toxic topical medication (acyclovir, gentamycin)*

*Preservative free medication*

- *When in doubt about viral replication or in settings of surface toxicity : start oral acyclovir 400 3-5id*
- *Low strength topical steroids prednisolon 0.125% 2-3id in stromal inflammation.*
- *Future therapy: compounds as Substance P, Growth factors*

*Corneal melting:*

*Combine the above mentioned therapy with:*

- *Cyanoacrylate tissue adhesive or*
- *Amnion transplant*
- *(Conjunctival flap)*

## **Suggested reading:**

- *E.J. Holland, GS Schwartz: Classification of herpes simplex virus keratitis. Cornea 1999;18:144-54.*
- *T.J. Liesegang : Classification of herpes simplex virus keratitis and anterior uveitis. Cornea 1999;18: 127-43.*
- *S.Y. Lee, P.R. Laibson: Medical management of herpes simplex ocular infections. Int. Ophthalmol Clin 1996;36:85-97.*
- *J.S. Pepose , Lieb D, Stuart M, Easty D: Herpes simplex virus disease: Anterior segment of the eye in Ocular infection and immunity ed. Pepose JS, Holland G, Wilhelmus K, St Louis, Mosby publishers.p905-932*
- *Hendricks RL: An immunologist's view of herpes simplex keratitis: Thygeson lecture 1996. Cornea 1997;16(5): 503-506.*
- *Herbert E. Kaufman Treatment of Viral Diseases of the Cornea and External Eye Progress in Retinal and Eye Research Vol. 19, No. 1, pp. 69 to 85, 2000*
- *Remeijer L, Osterhaus A, Verjans G. Human herpes simplex virus keratitis: the pathogenesis revisited.Ocul Immunol Inflamm. 2004 Dec;12(4):255-85.*

**L. Remeijer**

**Corneal and external diseases**

**The Rotterdam Eye Hospital**

**[l.remeijer@planet.nl](mailto:l.remeijer@planet.nl)**

# Fungal and chlamydial infections

| Philippe Kestelyn , Belgium |

---

## Fungal keratitis

### Introduction

Fungal keratitis is caused by yeast (e.g. *Candida*) or molds (*filamentary fungi*). Yeasts grow as creamy, opaque pasty colonies on culture media. Molds exhibit feathery or powdery growth on the surface of culture media (*Aspergillus*, *Fusarium*).

### Epidemiology

Fungal keratitis was first described by Leber in 1879, a case of *Aspergillus*. In the industrialized world fungal keratitis is rather uncommon, but is one of the major causes of keratitis in tropical areas of the world. The incidence varies according to the geographical location: in temperate regions yeasts will prevail, whereas in the tropics *Aspergillus* and *Fusarium* are more common. The incidence of fungal keratitis is on the rise over the past 30 years for several reasons: widespread use of antibiotics; increased prevalence of immune suppressed patients; better isolation techniques; and use of multipurpose no-rub contact lens solutions. A recent outbreak of *Fusarium* keratitis was reported in the USA, in Singapore, and in Europe (U.K., Belgium, and France), probably related to the use of no-rub multipurpose products (BL ReNu Moisture Lock).

### Pathophysiology

Fungi gain access into the corneal stroma through a defect in the epithelium. The organisms can penetrate intact descemet membrane, proliferate in the anterior chamber and spread to the posterior segment causing fungal endophthalmitis.

### Risk factors

- corneal trauma with vegetable material (plant or soil matter)
- corneal trauma related to contact lens wear
  - therapeutic lenses (*candida*)
  - refractive lens wear (*fusarium*)
- topical steroids (but also systemic steroids)
- corneal surgery (PKP, RK)
- chronic keratitis (HSV, HZV, VKC)
- immunosuppressive disease

## **Clinical presentation**

A fungal keratitis shows fewer inflammatory signs and symptoms during the initial period than a bacterial keratitis. As the keratitis progresses, intense suppuration may develop and the lesions may resemble bacterial keratitis. At this point rapidly progressive hypopion and anterior chamber inflammatory membranes will appear. If untreated extension in to the anterior chamber will occur and the fungus may invade the iris or the posterior chamber!

The clinical picture is different according to the causative organism. Filamentous fungal keratitis often follows corneal trauma. The lesion presents as a gray-white, dry-appearing infiltrate that may appear elevated. It has irregular feathery of filamentous margins with occasionally multifocal or satellite infiltrates. The initial break in the epithelium may have healed so that a deep stromal infiltrate is observed in the presence of an intact epithelium. Endothelial plaque and/or hypopion formation may also occur if the infiltrates are sufficiently deep or large.

The picture is somewhat different in yeast fungal keratitis. Here the normal microflora invades a preexisting epithelial defect. Most cases tend to remain superficial and present as superficial white raised colonies in a structurally altered eye. Occasionally deep invasion may occur with suppuration resembling bacterial keratitis.

In summary the most important clues to the diagnosis of fungal keratitis are the protracted time course, the discrepancy between the infiltrate and the level of inflammation, the presence of a plaque against the endothelium, the shape of the hypopion, and the association of intact epithelium over a deep infiltrate. When in doubt, confocal microscopy may be a useful technique. Confocal microscopy is a non-invasive, high resolution technique which allows rapid detection of fungal hyphae in the cornea long before laboratory cultures give conclusive results. If performed by an experienced observer a sensitivity of 50% and a somewhat higher specificity are obtained.

## **Laboratory examinations**

Smears, culture, histopathology and PCR are all potential techniques to consolidate the clinical suspicion. Smears with conventional staining have a sensitivity of about 50% to 80%.

Drawbacks of conventional stains include the frequent presence of background artifacts with potassium hydroxide (KOH), the weak staining (yeast) and interference with background staining for the Gram stain, and the need for an expensive

fluorescence microscope for calcofluor white staining. Therefore there is a need for a new staining technique that is rapid, easy to perform, highly sensitive and specific, and that can be done with a routine microscope.

[chlorazol black E mounts? very rapid (30 secs), not as sensitive as gram or lactophenol staining, more specific].

Culture is performed on Sabouraud and blood agar at 25°C. Most fungi can be isolated within 48-96h of incubation, but at least 25% require an incubation period of up to three weeks.

Histopathology a corneal biopsy can be considered when corneal smears and cultures are negative at 48-72 hours, in a patient who is strongly suspected of having a fungal infection or who is not improving on the initial, broad-spectrum antibacterial therapy. PAS and Grocott are classic stains for histopathology specimens. Fungal specific antibodies may be used as well.

PCR detects microbial DNA in the majority of fungal corneal ulcers and identifies potentially pathogenic organisms in a high proportion of culture-negative cases. The yield and concordance with culture are higher for fungal than bacterial ulcers. Unfortunately, there is a very high rate of false positives for apparently nonpathogenic organisms.

## Treatment

The most important antifungal agents are the polyene and the azole components:

- polyenes
  - amphotericin B 0,15% (Candida)
  - natamycin 5% (only commercially available drop)
- azoles
  - econazole 2%
  - voriconazole 1% (Fusarium)

## Different routes of administration have been tried:

- topical
  - hourly
  - with frequent (every other day) debridement of the epithelial layer
- intracameral
- subconjunctival
- intrastromal injection

Surgical therapy is an option when medical treatment fails. If the infection extends into the anterior chamber under therapy, debulk with early PKP (use of UBM/visante OCT), remove and culture or perform pathology of all infected tissue. Rinse the anterior chamber and clean the instruments. Interrupted sutures are recommended. The postoperative management should include topical and systemic antifungals, cyclosporin A and no steroids in the immediate postoperative period, until adequate control of infection is assured.

## Adult inclusion conjunctivitis

### Introduction

The chlamydiae are nonmotile, gram-negative bacteria that are metabolically deficient in their ability to synthesize ATP. Their dependency on an exogenous source of energy explains their obligate intracellular life cycle. Chlamydiae undergo a biphasic development cycle, forming distinctive intracellular inclusions that permit identification by light or fluorescence microscopy.

The genus *Chlamydia* is composed of four species: *Chlamydia trachomatis*, *Chlamydia pneumoniae*, *Chlamydia psittaci*, and *Chlamydia pecorum*. The different serovariants or “serovars” of *Chlamydia trachomatis* are responsible for the following diseases: serovars A, B, Ba, and C cause trachoma, a chronic and potentially blinding keratoconjunctivitis endemic in many developing countries where poverty goes along with deficient sanitation and poor hygiene; serovars D to K are the cause of one of the most common sexually transmitted diseases worldwide and both adult and neonatal inclusion conjunctivitis arise from transfer of bacteria from the genitalia to the eye; serovars L1, L2, and L3 are the etiological agent in venereal lymphogranulomatosis. The observation under the microscope of inclusion bodies in conjunctival cells infected with Chlamydiae explains the term inclusion conjunctivitis<sup>(18, 19)</sup>.

### Epidemiology

Adult inclusion conjunctivitis is due to *Chlamydia trachomatis* serovars D, E, F, G, H, I, J, and K. The bacterial reservoir is the genital tract of the sexually active adult. Urogenital chlamydiosis is the most common STD in the developed world and accounts for approximately 3 million new cases each year in the United States<sup>(4)</sup>. The highest prevalence is found in young, sexually active adults. The disease accounts for 40% to 50% of all cases of non-gonococcal urethritis in men<sup>(10)</sup>.

According to the WHO chlamydial prevalence rates in pregnant women range from 2.7% to 8% in Europe <sup>(24)</sup>.

Fifty to 70% of genital infections are asymptomatic and less than 10% of prevalent cases are diagnosed <sup>(20,21)</sup>. The genital infection causes urethritis, cervicitis, endometritis, salpingitis, and perihepatitis in women and is a major cause of sterility. In men it causes balanitis, urethritis, prostatitis, and epididymitis <sup>(3)</sup>. The rising prevalence of chlamydial infection and its association with an increased risk of cervical cancer, sterility and acquisition of HIV brings up the question whether a comprehensive European-wide screening policy is needed <sup>(16)</sup>.

Transmission to the eye occurs in the vast majority by autoinoculation with infected genital secretions from either the patient or his partner. Direct infection from the eye of one patient to the eye of another is possible but uncommon and could account for the small number of affected patients without concomitant genital disease. Indirect infection from inadequately disinfected swimming pools and from contact with contaminated inert surfaces has been described but is rare <sup>(23, 11, 13)</sup>.

### **Clinical picture**

The incubation period of adult inclusion conjunctivitis varies from 2 days to 3 weeks. It starts as a unilateral, papillary conjunctivitis with mucopurulent secretions and a swelling of the ipsilateral premandibular lymph glands. Later on typical follicles will develop on the upper and the lower tarsal plate. Swelling and infiltration of the subconjunctival tissue may obscure the vertical vessels of the upper tarsal plate mimicking the classic picture of inflammatory trachoma at this stage <sup>(1, 6)</sup>. Pseudomembrane formation seen in neonatal inclusion conjunctivitis is not seen in the adult form. Involvement of the second eye may ensue, but is not always present.

Corneal involvement includes discrete pannus formation, superficial punctate keratopathy, and more seldom marginal infiltrates <sup>(7)</sup>. Frank corneal neo-vascularisation and conjunctival scarring typical of trachomatous keratoconjunctivitis are not observed in adult inclusion conjunctivitis.

The initial phase of acute infection is often missed and most patients will present with a chronic red eye. They will complain of mucopurulent secretions and sticky eyes in the morning, a foreign body sensation and photophobia. Inspection at this stage will show a papillary and follicular conjunctival reaction, eventually discrete corneal changes, but the inflammatory swelling of the subconjunctival tissue will no longer be present <sup>(8)</sup>.

The differential diagnosis of adult inclusion conjunctivitis is in the first place the differential diagnosis of chronic follicular conjunctivitis and should include the following entities: classic trachoma, adenoviral epidemic keratoconjunctivitis, herpes, Newcastle disease virus conjunctivitis, chronic allergic conjunctivitis, acnea rosacea and chronic blepharitis, and even floppy eyelid syndrome <sup>(15)</sup>.

### **Laboratory diagnosis**

The clinical diagnosis of adult inclusion conjunctivitis may be difficult and therefore identifying chlamydiae in conjunctival scrapings or direct diagnosis may be very useful. Because chlamydiae are obligate intracellular pathogen, the scraping should include infected cells. Therefore, specimens that contain only exudate or secretions but no cells are unsatisfactory. For conjunctival specimens any purulent exudate should be removed before collecting epithelial cells by vigorously rubbing a dry swab over the everted palpebral conjunctiva. The specimen is then transferred to a transport medium that makes it possible to perform both culture and DNA amplification techniques from a single swab. The likelihood of isolation is optimized if specimens are refrigerated immediately after collection at 2 to 8° Celsius and kept at this temperature during transport. The delay between collection and laboratory processing should be less than 48 hours. Specimens that cannot be processed within 48 hours may be frozen at – 70° Celsius, but this is likely to result in a 20% loss of viability. Freezing at – 20° Celsius should be avoided altogether <sup>(2)</sup>.

The following laboratory methods are available to identify chlamydial infection:

1. Culture methods
2. Nonculture methods
  - a. Direct cytologic examination to identify inclusion bodies by staining methods
  - b. Identification of chlamydial antigen
  - c. nucleic acid amplification techniques (NAATs)
3. Serologic tests.

### **Culture methods**

Culture methods on viable cells used to be the gold standard for the diagnosis of chlamydial infection. They have lost this status with the advent of nuclear acid amplification techniques or NAATs during the last decade because of their relative insensitivity: culture methods have a specificity that approaches 100% , but their sensitivity is only 70 to 85% in comparison with NAAT's (cfr. infra). Other disadvantages of culture techniques include the requirement for a stringent cold chain for transportation of specimens, high cost, high level of technical expertise and a time delay to obtain results from 3 to 7 days.



## Nonculture methods

- a. Staining of conjunctival scrapings with Giemsa to demonstrate typical chlamydial inclusion bodies is not recommended for the diagnosis of adult inclusion conjunctivitis due to its lack of sensitivity<sup>(17)</sup>. Moreover, recognition of chlamydial inclusions requires considerable expertise.
- b. Antigen detection methods include the DFA test based on direct visualization of the chlamydial organism by staining with fluorescein-labeled specific antibody, the EIA test based on immunochemical detection of antigen, and the DNA hybridization probe to detect chlamydial rRNA. All these tests are commercially available and commonly used (Microtrak DFA, Behring Diagnostics; Chlamydiazyme, Abbott Diagnostics; Microtrak EIA, Behring; PACE 2, Gen-Probe).
- c. The development of NAATs has been the major advance in the field of chlamydial diagnosis in the last decade. A number of commercial tests are available: polymerase chain reaction or PCR tests (Amplicor, Roche Diagnostics), strand displacement amplification (SDA, Becton Dickinson), and ligase chain reaction (LCR, Abbott Laboratories). They all combine exquisite sensitivity with very high specificity and are considered the new gold standard in the diagnosis of chlamydial disease<sup>(12)</sup>.

## Serologic tests

Serologic tests are generally not useful in the diagnosis of genital tract infection caused by *Chlamydia trachomatis*. Antibodies elicited by infection are long lived and a positive titer will not distinguish a previous from a current infection. The presence of IgM is an unreliable marker of acute infection since it is often not present. The presence of antichlamydial IgG in tears might be helpful for diagnosis in patients with suspected chlamydial conjunctivitis, since IgG seems to be absent in tears from patients with only urethritis<sup>(9)</sup>.

## Treatment

Since adult inclusion conjunctivitis results from autoinfection in patients with genital disease in the vast majority of cases, systemic treatment is mandatory to prevent extraocular morbidity and ocular reinfection. The classic treatment includes oral doxycycline, 100 mg twice a day for one week; or in pregnant women erythromycin, 500 mg four times a day for one week. Azithromycin, 1 g as a single dose is equally effective, more patient friendly, but more expensive<sup>(14)</sup>. Oral

fluoroquinolones are also effective agents against *C. trachomatis*. Screening and treatment of infected sexual partners of the patients as well as counseling about safe sex should be part of the comprehensive care<sup>(5)</sup>.

The CDC does not recommend routine test-of-cure visits during the post treatment period. If for some reason a test-of-cure seems indicated, only culture methods should be used. NAATs are less useful for this indication as they may pick up residual DNA in the early post treatment period in patients whose infection has been cured<sup>(2)</sup>.

### Summary for the clinician

- urogenital chlamydiosis due to *C. trachomatis* serovars D-K is the most frequent STD in the industrialized world
- although often asymptomatic, it is responsible for significant morbidity
- adult inclusion conjunctivitis arises from transfer of bacteria from the genitalia to the eye (autoinoculation)
- the prevailing clinical presentation is that of a chronic red eye with a moderate amount of mucopurulent secretions
- the differential diagnosis includes the different causes of follicular and chronic conjunctivitis, uni- or bilateral
- the clinical suspicion is confirmed by laboratory methods
- nucleic acid amplification tests have the highest sensitivity and specificity and have supplanted culture methods as the gold standard
- systemic administration of doxycycline, erythromycin, azithromycin or fluoroquinolones is the treatment of choice
- sexual partners of the patient should be screened as well
- counseling about safe sex should be provided to the patient and his partners

## Trachoma

Trachoma is the second or the third most important cause of blindness in the world (either before or after glaucoma). According to WHO estimates 150 million people are infected and 5.5 million people are blinded by this disease. Blinding trachoma is the end result of repetitive infections that cause scarring of the tarsal plate and trichiasis which predisposes the corneal surface to micro-erosions and subsequent bacterial superinfections.

### **Risk factors for the disease:**

- lack of personal hygiene
- absence of pit latrines
- keeping cattle in the immediate vicinity of the house
- crowding
- presence of waste and feces in the open air

All these factors will attract flies that feed on the nasal secretions and the tears of children and carry the infection from one person to the other. Children will get the infection at an early age and will reinfect the adults taking care of them, mainly women (mother, grandmother, elder sister). Reinfection of the adults creates a cycle of repetitive infections leading to chronic inflammation of the tarsal plate. This chronic inflammation will cause scarring and contraction of the inner lamellae of the tarsal plate. Inward bowing of the upper eyelid causes trichiasis: the cilia of the upper eyelid will rub against the corneal surface. Chronic rubbing of the cilia will cause micro-erosions and subsequent bacterial superinfections. The cornea will gradually become opaque and vascularized as a result of the repetitive infections.

### **Simplified WHO classification of trachoma**

The WHO has proposed a simplified classification of trachoma that is useful for the diagnosis and the staging of the individual patient. Moreover it is a useful tool to assess the importance and the dynamics of the disease in the community.

**TF Trachomatous Inflammation Follicular (TF)**

At least 5 follicles on the flat surface of the upper tarsal plate

**TI Trachomatous Inflammation Intense (TI)**

Inflammatory thickening of the tarsal conjunctiva that obscures at least half of the normal deep tarsal vessels

**TS Trachomatous Scarring Scarring**

Citracial trachoma, presence of fine white lines in the tarsal conjunctiva

**TT Trachomatous Trichiasis**

At least one eyelash rubs on the eyeball

**CO Corneal Opacity**

Opacity of the cornea extending over part of the pupil

Screening of a population for trachoma with the aid of this grading system allows the following conclusions:

- the number of individuals with TF is a measure for the incidence (early infection = new cases)
- the number of individuals with TI is a measure for the prevalence of active disease; both TF and TI individuals need antibiotic treatment
- the number of individuals with TT is a measure for the magnitude of the population at risk of becoming blind; trichiasis surgery should be made available to this group
- the number of individuals with CO is a measure for the importance of trachoma as a blinding disease in that particular community

**Differential diagnosis:**

- with vernal keratoconjunctivitis
- with ocular pemphigoid

## Medical treatment (TF and TI)

- Tetracycline ointment BID for 6 weeks
- Azythromycine eyedrops BID for 3 days
- Doxycycline 100 mg per day for 3 weeks
- Tetracycline 250 mg QID for 3 weeks
- Azythromycine 1G as a single dose treatment

## Surgical treatment

- Epilation
- Electrolysis
- Cryoablation
- Trichiasis surgery (bilamellar tarsal rotation procedure)

## References

1. *Bialasiewicz AA (1994) Ocular features of oculogenital Chlamydial infections. Bialasiewicz AA, Schaal KP. Infectious diseases of the eye. Aeolus PRESS. 561-575*
2. *Blythe M, Katz BP, Batteiger BE, Ganser JA, Jones RB (1992) Recurrent genitourinary chlamydial infections in sexually active female adolescents. J Pediatr 121:487-493*
3. *Cates W Jr, Wasserheit JN (1991) Genital chlamydial infections: epidemiology and reproductive sequelae. Am J Obstet Gynecol 164:1771-1781*
4. *Centers for Disease Control and Prevention: MMWR Morb Mortal Wkly Rep (2005) Reporting of chlamydial infection-Massachusetts, January-June 2003, 54(22):558-560*
5. *Centers for Disease Control and Prevention: MMWR Recommendations and Reports (2006) Sexually transmitted Diseases Treatment Guidelines 2006 55(RR11):1-94, p. 54.*
6. *Creuzot-Garcher C, Guertzider V (2001) Chlamydial conjunctivitis. In: Hoang-Xuan T, Baudouin C, Creuzot-Garcher C, Inflammatory diseases of the Conjunctiva, Georg Thieme Verlag Stuttgart-New York, p 121-132*
7. *Darougar S, Viswalingam M (1988) Marginal corneal abscess associated with adult Chlamydial ophthalmia. Br J Ophthalmol 72:774-777*
8. *Dawson C (1998) Chlamydial diseases. Kaufman HE, Barron BA, McDonald MB. The cornea. Butterworth-Heinemann, p 315-329*
9. *Haller EM, Auer-Grumbach P, Stuenzer D, Kessler HH, Pierer K, Muellner K, Zenz H (1996) Detection of antichlamydial antibodies in tears. Ophthalmology 104:125-130*

10. Holmes KK, Handsfield HH, Wang SP, Wentworth BB, Turck M, Anderson JB, Alexander ER (1975) Etiology of nongonococcal urethritis. *N Engl J Med* 292:1199-1205
11. Jones BR (1964) Ocular syndromes of TRIC virus infection and their possible genital significance. *Br J Vener Dis* 10:3-18
12. Martin DH, Nsuami M, Schachter J, Hook EW 3rd, Ferrero D, Quinn TC, Gaydos C (2004) Use of multiple nucleic acid amplification tests to define the infected-patient "gold standard" in clinical trials of new diagnostic tests for *Chlamydia trachomatis* infections. *J Clin Microbiol* 42(10):4749-4758
13. Novak KD, Kowalski RP, Karenchak LM, Gordon YI (1995) *Chlamydia trachomatis* can be transmitted by a non porous plastic surface in vitro. *Cornea* 14:523-526
14. Rahangdale L, Guerry S, Bauer HM (2006) An observational cohort study of *Chlamydia trachomatis* treatment in pregnancy. *Sex Transm Dis* 33:106-110
15. Rapoza PA, Quinn TC, Tery AC, Gottsch JD, Kiessling LA, Taylor HR (1990) A systematic approach to the diagnosis and treatment of chronic conjunctivitis. *AM J Ophthalmol* 109:138-142
16. Roberts TE, Robinson S, Barton P, Bryan S, Low N, Chlamydia Screening Studies (ClasS) Group (2006) Screening for *Chlamydia trachomatis*: a systematic review of the economic evaluations and modeling. *Sex Transm Infect* 82(3): 193-200, discussion 201
17. Schachter J (1980) *Chlamydiae* In: N.R. Rose and H. Friedman (ed.), *Manual of clinical microbiology*, 2nd ed. American Society for Microbiology, Washington, D.C., p 701-706
18. Schachter J, CR Dawson (1978) *Human chlamydial infections*, PGG Publishing Co., Littleton, Mass, p. 187
19. Schachter J, Stamm WE (1995) *Chlamydia*, In: Murray PR, Pfaller MA, Tenover FC, Tenover RH (ed), *Manual of clinical microbiology*, 6th ed. American Society for Microbiology, Washington DC, p 669-677
20. Schachter J, Stoner E, Moncada J (1983) Screening for chlamydial infections in women attending family planning clinics. *West J Med* 138:375-379
21. Stamm WE, Cole B (1986) Asymptomatic *Chlamydia trachomatis* urethritis in men. *Sex Trans Dis* 13:163-165
22. Stamm WE, Koutsky A, Benedetti JK, Jourden JL, Brunham RC, Holmes KK (1984) *Chlamydia trachomatis* urethral infections in men. Prevalence, risk factors, and clinical manifestations. *Ann Intern Med* 100:47-51
23. Weinstock H, Dean D, Bolan G (1994) *Chlamydia trachomatis* infections. Sexually transmitted diseases in the AIDS era, part II. *Infect Dis Clin North Am* 8:797-819
24. [www.who.int/docstore/hiv/GRSTI/003.htm](http://www.who.int/docstore/hiv/GRSTI/003.htm)

**Kestelyn Philippe**  
**Philippe.Kestelyn@uzgent.be**

# Role of inflammation in ocular surface disease

| Dana Reza , United States |

---

## I. Overview of Immunity

### a. Innate Immunity

- i. Rapid response
- ii. No memory
- iii. No gene rearrangement
- iv. Effectors: macrophages, neutrophils, NK cells

### b. Adaptive immunity

- i. Slower to generate
- ii. Involves memory
- iii. Antigen-specific
- iv. Effectors: T cells

## II. Common corneal and ocular surface immunoinflammatory disorders

### a. Ocular Allergy

- i. Clinical presentation
- ii. Principal target tissue: conjunctiva
- iii. Immunopathogenesis
  1. Mast cells
  2. Eosinophils
  3. T helper 2 responses

### b. Dry eyes

- i. Clinical presentation
- ii. Principal target tissues: cornea and conjunctiva
- iii. Immunopathogenesis
  1. Role of corneal monocytes
  2. Induction of Th1 and Th17 effectors
  3. Role of T regulatory cells
  4. T cell homing and role of CC chemokines

**c. Transplant rejection**

- i. Early involvement of innate responses and role of limbal vasculature
- ii. Maturation of corneal antigen-presenting cells (APC)
- iii. Trafficking of APC to lymphoid organs through lymphatics
- iv. Activation of T cells

**d. Angiogenesis**

- i. Blood vs lymphatic vessels
- ii. Role in inflammation: Induction versus expression of immunity
- iii. Anti-angiogenic treatments in eye disease

***Reza Dana, MD, MPH, MSc***

***Director of Cornea & Refractive Surgery Service, Mass Eye & Ear Infirmary***

***Harvard Department of Ophthalmology***

***reza\_dana@hotmail.com***



# Tumors of conjunctiva and cornea

| Stefan Seregard , Sweden |

---

Tumours include neoplasia and reactive mass-like lesions. Neoplastic lesions may be benign or malignant. Malignant lesions are characterized by the capacity to invade basement membranes and the potential to generate metastasis. Metastatic disease are caused by cells invading lymphatic vessels or blood vessels, surviving in the circulation and then attaching and extravasating at a distant site. For this reason, lesions which are confined to the epithelium (i.e. without signs of break of basement membrane invasion) do not have the capacity to generate metastatic spread. Such lesions are typically referred to as carcinoma-in-situ or melanoma-in-situ. Nearly all tumour-like lesions of the cornea and conjunctiva actually derive from the conjunctiva, and any corneal location is usually caused by secondary tumour invasion.

The tumours of the cornea and conjunctiva may for practical reasons be divided into melanocytic and non-melanocytic lesions. Most melanocytic lesions are pigmented, but a substantial proportion (e.g. approximately 30% of conjunctival naevi are non-pigmented). Similarly, non-melanocytic lesions may show pigmentation (e.g. squamous cell carcinoma of the conjunctiva presenting in individuals with heavy skin pigmentation).

Melanocytic lesions of the conjunctiva arise from melanocytes typically lodged in the basal part of the conjunctival epithelium or sometimes in the conjunctival stroma. The most common lesion is the acquired conjunctival naevus, typically presenting as a thin, pigmented or non-pigmented lesion in the limbal or juxtalimbal region. This lesion rarely undergoes malignant transformation to malignant melanoma, but may be excised for cosmetic reasons.

Individuals with abundant skin pigmentation often features bilateral and symmetrical conjunctival pigmentation of the limbal region. This is a normal variant referred to as ethnic or racial melanosis and should not be confused with primary acquired melanosis (PAM). The PAM typically features a unilateral flat pigmentation without cysts. The borders are not sharply defined and lesions may have satellites or be multifocal. Up to 50% of PAM featuring cytological atypia progresses into malignant melanoma. In contrast, PAM without atypia have a very small risk (if any) for malignant transformation. To assess the presence of atypia, biopsy of the conjunctival lesion is usually required even though cytological sampling by exfoliative smears are advocated by some authors.

Malignant melanoma is a very rare tumour typically occurring in the limbal or juxtalimbal region of middle-aged or elderly individuals. Sometimes, a melanoma may arise from the tarsal, forniceal or caruncular conjunctiva. Thus, a complete examination of the entire conjunctival sac including the tarsal conjunctiva is warranted in patients evaluated for conjunctival malignant disease. Treatment of malignant melanoma of the conjunctiva is usually surgical taking care to provide adequate surgical margins. Large conjunctival defects may be covered by amniotic membrane grafts. Adjunctive treatment may include cryotherapy, topical chemotherapy (using mitomycin) or brachytherapy. Primary orbital exenteration has not been shown to improve survival, but exenteration may sometimes be required to control local disease. Metastatic disease appears in some 30% of patients usually confined to the ipsilateral regional lymph nodes or salivary glands (in particular the ipsilateral parotid gland). Lymph nodes may be monitored by simple palpation or imaging by ultrasound. Any lymph node suspected of harbouring metastatic disease may be surgically excised or studied by cytology after sampling using a fine-needle aspiration biopsy. Confirmed spread to the lymph nodes may be managed by radical neck dissection. Later in the course of disease, systemic spread to distant sites may occur. Patients with malignant melanoma of the conjunctiva or PAM with atypia should probably have period ophthalmic follow-up for life.

Non-melanocytic lesions of the conjunctiva include a wide variety of neoplastic and reactive mass-like lesions. Conjunctival intraepithelial neoplasia (CIN) typically occurs in the limbal region of elderly patients and tend to encroach onto the cornea. Once referred to as Bowen's disease this in-situ carcinoma has traditionally been managed surgically. Local recurrence is common but recently excellent results have been reported using topical chemotherapy (5-fluorouracil or mitomycin). The CIN rarely progress to invasive squamous cell carcinoma, but once this has happened the lesion carry a potential to seed metastases, usually to the ipsilateral regional lymph nodes. The carcinomas of the conjunctiva also include the rare, but highly aggressive mucoepidermoid carcinoma and the poorly differentiated spindle cell carcinoma. Rarely, neoplastic disease secondarily invade the conjunctiva from the neighbouring skin or adnexal structures.

Reactive, and usually non-pigmented, mass-like lesions include the fleshy, heavily vascularized so-called pyogenic granuloma (often occurring at the site of previous surgery or chalazion), the limbal dermoid (actually a choristomatous type of lesion; i.e. a congenital lesion composed normal cells not normally present at the location), conjunctival papilloma, and lymphangiectasia.

In summary, the conjunctiva and cornea is the site of origin for a wide variety of neoplastic and reactive mass-like lesions. Some of these lesions may masquerade

as others, but it is important to make a correct diagnosis as some lesions are associated with systemic spread and even may cause death in disseminated disease. The majority of lesions are, however, benign. Management depends on the specific type of lesion encountered and is typically surgical, even though a number of adjunctive therapies like cryotherapy, topical chemotherapy and brachytherapy are available. New techniques like sentinel lymph node biopsy may be helpful to diagnose malignant lesions with early metastatic spread.

**Classification of some epidermal and stromal tumours of the conjunctiva**

Non-melanocytic	Benign lesions	Squamous papilloma Keratoacanthoma Pyogenic granuloma Oncocytoma Lymphocytic hyperplasia Lymphangiectasia Lymphangioma
	Premalignant	Actinic keratosis Conjunctival intraepithelial neoplasia
	Malignant	Squamous cell carcinoma Mucoepidermid carcinoma Lymphoma Kaposi sarcoma
Melanocytic	Benign	Junctional naevus Compound naevus Intrastromal naevus PAM without atypia
	Premalignant	PAM with atypia
	Malignant	Melanoma

**Stefan Seregard**  
**St. Eriks Hospital and Kaolinska Institute**  
**Stockholm, Sweden**  
**stefan.seregard@sankterik.se**



# Dry eye and clinical disease of tear film, diagnosis and management

| Christoffe Baudouin , France |

---

New mechanistic schemas and definitions of dry eye disease (DED) have been recently proposed, in order to complete the classic etiological approach and provide a better understanding of this complex pathology. Inflammation, ocular surface damage, visual impairment and hyperosmolarity are now considered as key factors influencing pathogenesis of DED and patient complaint. Two levels of ocular surface impairment can be proposed, with standard etiologies, previously validated in the NEI/Industry workshop, being not independent diseases but risk factors and/or ways to enter a self-stimulated biological process involving the ocular surface.

Tear film instability or hyposecretion can be considered as the central key point of DED. They will cause local or diffuse hyperosmolarity of the tear film and therefore of superficial epithelial cells of cornea and/or conjunctiva, stimulating epithelial cells and resident inflammatory cells. Cell damage that will result at levels of cornea and conjunctiva, by mean of apoptosis, direct mechanical and/or osmotic stress, will stimulate the reflex neurosensory arc, stimulating lacrimal gland and neurogenic inflammation, with inflammatory cytokine release, MMP activation and inflammatory involvement of the conjunctival epithelium. Goblet cell loss is thus directly related to chronic inflammation and surface cell apoptosis subsequent to cell hyperosmolarity and chronic damage, resulting in further tear film instability/imbalance.

This mechanistic approach proposes a synthetic combination of mechanisms previously validated in an independent way, with two levels of ocular surface impairment, a first level including many possible acute or chronic causes that favor or trigger the disequilibrium, and can be reversible if correctly and specifically managed when possible, and the further involvement of a series of biological cascades centered by tear film imbalance and inflammatory stimulation, finally acting as an independent vicious circle, whatever the way(s) the patient entered the loop.

This proposed schema should be considered as a basis for further reflection on biological mechanisms that could be even more complex but individually constitute potential tracks for targeting therapeutic strategies in order to allow patients to leave the loop even though the triggering factor(s) are still present or can only be attenuated, such as in Sjögren syndrome or ocular rosacea. This approach as

well as new definitions, pathogenesis and therapeutic targets will be described and discussed. Anti-inflammatory and immunomodulating agents are now the basis for mechanistic treatments. The deleterious role of preservatives is also recognized and treating associated diseases, such as rosacea or meibomian gland dysfunction, may be helpful for treating more efficiently dry eyes.

***Christophe Baudouin, MD, PhD***  
***Professor and Chair of Ophthalmology***  
***Department of Ophthalmology III***  
***Quinze-Vingts National Ophthalmology Hospital***  
***Paris, France***  
***chrbaudouin@aol.com***

# Present role of surface ablation & PTK

| Timo Tervo , Finland |

---

Timo M.T. Tervo, MD, PhD and Waldir Neira, MD

## 1. Introduction

First refractive surgical procedures were performed about 100 years ago, but the fastest development in this field has taken place in the last 25 years<sup>1</sup> with the development of excimer laser as an instrument for refractive surgery. Thus, the number of refractive cor-rections performed has rapidly increased and today several million procedures are performed annually worldwide. A good understanding of biomechanical changes in the cornea<sup>2, 3</sup> the interaction between the corneal tissue and appropriate laser energy,<sup>4</sup> and more importantly, the processes of wound healing related to the laser wounds are mandatory for providing satisfactory results.<sup>5-7</sup>

The photoablative process can be divided into surface photoablation and lamellar corneal surgery after formation of an epitheliostromal flap.

Photorefractive keratectomy (PRK) is the most common for reshaping the superficial stroma. Various types of corneal epithelial removal are used to perform it. The most frequent technique is to remove the corneal epithelium with a sharp blade or blunt spatula (mechanical debridment). Alternatively the epithelium can be removed by the excimer laser itself (transepithelial ablation). The absence of epithelium has been thought to induce more epithelio-stromal cytokine interaction, which may translate into scar (haze) formation during the course of wound healing.<sup>8</sup> Attempts to return the epithelium on top of the stromal wound have led to alternative techniques for “*en bloc*” epithelial removal. These include the application of diluted alcohol suspension on the corneal surface to “harden” and then loosen the epithelium, knowing as Laser-Assisted SubEpithelial Kera-tomileusis (LASEK).<sup>9</sup> More recently techniques utilizing a mechanical microkeratome with a customized blade design have been introduced. This procedure is called Epi-LASIK.<sup>10</sup> The microkeratome has also been used as an advanced epithelial scraper for PRK.

On the other hand, Laser in-situ keratomileusis (LASIK) -stromal ablation- has become the most popular form of refractive surgery. The photoablation is performed deeper (90 to 180  $\mu\text{m}$  under the surface) in the stroma after the creation of a lamellar flap<sup>11</sup> formed with a mechanical microkeratome or a femtosecond laser.

Clinical haze has not been reported in long-term LASIK studies although some microscopically haze may be present.<sup>12</sup>

Different advantages and disadvantages of the surface photoablation and intrastromal surgery should be considered when selecting the right procedure for the patient.

## 2. Refractive results

Twelve year long-term follow-up (up to -7.00 D) study after PRK showed that stable visual acuity was achieved only 1 year after the procedure.<sup>13</sup> At least up to -6.00 diopters (D), the results of myopic correction in terms of predictability and uncorrected visual acuity (UCVA) are similar for PRK and LASIK.<sup>14-17</sup> Long-term studies have shown that PRK is safe and predictable procedure in correction of low and moderate refractive errors.<sup>13,18</sup> Yet, PRK showed more regression than LASIK at 10 years follow-up.<sup>18-22</sup> Our unpublished results also shows that postoperative outcomes after high astigmatism correction are slightly better with LASIK than PRK.

## 3. Haze

Incidence of haze is higher after surface ablations, specially after correction of moderate to high myopia.<sup>23-26</sup> Haze reaches its maximum between the second and third months,<sup>27</sup> but resolves spontaneously by 6 months to 1 year. In surface ablations, the absence of epithelial basement membrane and/or Bowman's layer are thought to allow the entry of epithelium derived cytokines into the stroma necessary and lead to myofibroblast alteration and formation of scar-type ECM. Postoperative haze may continue to disappear, even after the first postoperative year.<sup>28</sup> Twelve year's follow-up after PRK reported no haze in 94% of the eyes.<sup>13</sup> Yet, cases of late-onset haze have also been described.<sup>29</sup> Both simple epithelial scrape as well as PRK has been shown to induce death of anterior stromal keratocytes within minutes by apoptosis. Transepithelial PRK photoablation has been reported to induce less stromal cell apoptosis than PRK performed after surgical scraping of the epithelium.<sup>30</sup> Deep photoablations (high corrections) have been shown<sup>26, 31</sup> to create surface irregularities. Phototherapeutic keratectomy (PTK)-smoothing seems to decrease the incidence of haze after PRK.<sup>32</sup> Interestingly, visual outcomes appear to be better after transepithelial PRK (T-PRK) than LASIK<sup>33</sup> but micro- and macro folds are almost unavoidable even if they often "smoothen" by the epithelium. However, they may affect the corneal optics.



## 4. Regression

Myopia regression after PRK is thought to result from resynthesis of ECM by activated fibroblasts and altered keratocytes.<sup>24</sup> A relation between regression and age has been described,<sup>13</sup> yet none relation with epithelial thickness has been reported as in LASIK. In some cases, regression of myopia may continue even up to 5 years after PRK.<sup>34</sup>

## 5. Corneal nerves

Nerve damage in the anterior corneal stroma appears to be less severe in PRK than in LASIK.<sup>35</sup> Histological sections have revealed presumably regenerating nerve fibres already on day one post-PRK.<sup>36, 37</sup> Neural orientation and regrowth may be affected by the absence of Bowman's layer in corneas after PRK.<sup>38</sup> PRK ablates the superficial subbasal nerves resulting in less stromal nerve destruction. Thus the neural recovery after PRK is usually faster. Nerve density after PRK improves significantly still after 1 year, and reaches near normal mean values at 2 years. Several studies<sup>39, 40</sup> have shown that two years after LASIK, the subbasal nerves density reaches ~ 60% of the preoperative values. Similar values have been reported to be reached one year after PRK. Recent observation suggest the importance of sufficient neural regeneration on the postoperative healing and predictability.<sup>41</sup>

Hyperopic PRK may induce even more profound sensory denervation, since it damages the thick peripheral nerve bundles, thus leading to more profound haze and keratocyte activation in the corneal periphery, as well as in the central area. It also needs a longer period to stabilize and less predictability and is usable to only up to + 4D provided that the cornea is not very deep preoperatively.

## 6. Postoperative pain

Pain is maybe a one of the problems related to surface ablations although it shows a large inter-individual variation. Patients who receive PRK typically have moderate to severe pain for 1–4 days after the procedure, and usually recovery of visual performance takes one to two weeks.<sup>42, 43</sup> Different techniques have been tried in order to decrease postoperative pain but have shown only limited success. Less pain- and probably haze has been reported after epiLASIK and LASEK vs. PRK but contradictory reports have also been published.<sup>44-47</sup>

## 7. Epithelial basement dystrophy

Anterior basement membrane dystrophy, such as RCES (MDF), has been suggested to arise from abnormal adhesion between the epithelium and the basement membrane-Bowman's layer complex. This, in addition to variable epithelial thickness may contribute or generate a morphologically irregular anterior corneal surface.<sup>48</sup> Eyes with history of MDF / RCES that did not show changes at the slit lamp biomicroscopy examination, but showed CCTs compatibles with irregular astigmatism that affects the VA can be cor-rected with simple PTK.<sup>49</sup> Consequently, wave front analysis is unreliable in these cases, and simple epithelial abrasion and PTK should be performed first and the patient re-examined after PTK prior to any stromal re-sculpture

## 8. Conclusion

Surface ablations still have pros and cons, indications and contraindications. Surface ablation is often the method of choice in small deep eyes, thin corneas, corneas with penetrating wounds such as RK, MDF-like eyes and in correction of low simple myopic corrections. Less expensive and easier surface ablations avoid flap complications, and decrease the risk of ectasia in thin corneas. LASEK and epi-LASIK do not seem to offer significant benefits over transepithelial-PRK or PRK. However, short topical postopera-tive mitomycin-C treatments with a low concentration may in selected cases also im-prove the results of surface ablations.

## References

1. Stulting RD, Lahnert WJ, Carr JD. *Advances in refractive surgery: 1975 to the pre-sent. Cornea.* 2000;19:741-753.
2. Eshbaugh et al. *Optical quality and refractive surgery. International Ophthalmology.* 2000;Summer; 40:1-10.
3. Holladay JT. *Optical quality and refractive surgery. Int Ophthalmol Clin.* 2003;43:119-136.
4. Krauss JM, Puliafito CA, Steinert RF. *Laser interactions with the cornea. Surv Oph-thalmol.* 1986;31:37-53.
5. Dawson DG, Edelhauser HF, Grossniklaus HE. *Long-term histopathologic findings in human corneal wounds after refractive surgical procedures. Am J Oph-thalmol.* 2005;139:168-178.
6. Wilson SE, Mohan RR, Hong JW, Lee JS, Choi R, Mohan RR. *The wound healing response after laser in situ keratomileusis and photorefractive keratectomy: Elu-sive con-trol of biological variability and effect on custom laser vision correction. Arch Ophthal-mol.* 2001;119:889-896.

7. Latvala T, Linna T, Tervo T. Corneal nerve recovery after photorefractive keratectomy and laser in situ keratomileusis. *Int Ophthalmol Clin.* 1996;36:21-27.
8. Helena MC, Baerveldt F, Kim WJ, Wilson SE. Keratocyte apoptosis after corneal sur-gery. *Invest Ophthalmol Vis Sci.* 1998;39:276-283.
9. Taneri S, Zieske JD, Azar DT. Evolution, techniques, clinical outcomes, and patho-physiology of LASEK: Review of the literature. *Surv Ophthalmol.* 2004;49:576-602.
10. Pallikaris IG, Katsanevaki VJ, Kalyvianaki MI, Naoumidi II. Advances in subepi-thelial excimer refractive surgery techniques: Epi-LASIK. *Curr Opin Ophthalmol.* 2003;14:207-212.
11. Updegraff SA, Kritzinger MS. Laser in situ keratomileusis technique. *Curr Opin Oph-thalmol.* 2000;11:267-272.
12. Latvala T, Barraquer-Coll C, Tervo K, Tervo T. Corneal wound healing and nerve morphology after excimer laser in situ keratomileusis in human eyes. *J Refract Surg.* 1996;12:677-683.
13. Rajan MS, Jaycock P, O'Brart D, Nystrom HH, Marshall J. A long-term study of pho-torefractive keratectomy; 12-year follow-up. *Ophthalmology.* 2004;111:1813-1824.
14. Azar DT, Farah SG. Laser in situ keratomileusis versus photorefractive keratectomy: An update on indications and safety. *Ophthalmology.* 1998;105:1357-1358.
15. Shah S, Chatterjee A, Smith RJ. Predictability of spherical photorefractive keratec-tomy for myopia. *Ophthalmology.* 1998;105:2178-84; discussion 2184-5.
16. el Danasoury MA, el Maghraby A, Klyce SD, Mehrez K. Comparison of pho-torefrac-tive keratectomy with excimer laser in situ keratomileusis in correcting low myopia (from -2.00 to -5.50 diopters). A randomized study. *Ophthalmology.* 1999;106:411-20; discus-sion 420-1.
17. Hersh PS, Steinert RF, Brint SF. Photorefractive keratectomy versus laser in situ keratomileusis: Comparison of optical side effects. summit PRK-LASIK study group. *Ophthalmology.* 2000;107:925-933.
18. Alio JL, Muftuoglu O, Ortiz D, et al. Ten-year follow-up of photorefractive keratec-tomy for myopia of less than -6 diopters. *Am J Ophthalmol.* 2008;145:29-36.
19. Alio JL, Muftuoglu O, Ortiz D, et al. Ten-year follow-up of photorefractive keratec-tomy for myopia of more than -6 diopters. *Am J Ophthalmol.* 2008;145:37-45.
20. Alio JL, Muftuoglu O, Ortiz D, et al. Ten-year follow-up of laser in situ keratomileu-sis for myopia of up to -10 diopters. *Am J Ophthalmol.* 2008;145:46-54.
21. Alio JL, Muftuoglu O, Ortiz D, et al. Ten-year follow-up of laser in situ keratomileu-sis for high myopia. *Am J Ophthalmol.* 2008;145:55-64.
22. Waring GO. Have you seen the 10-year long-term safety data on laser in situ kera-tomileusis? *Am J Ophthalmol.* 2008;145:1-2.
23. Frueh BE, Cadez R, Bohnke M. In vivo confocal microscopy after photorefrac-tive keratectomy in humans. A prospective, long-term study. *Arch Ophthalmol.* 1998;116:1425-1431.

24. Moller-Pedersen T, Cavanagh HD, Petroll WM, Jester JV. Stromal wound healing explains refractive instability and haze development after photorefractive keratectomy: A 1-year confocal microscopic study. *Ophthalmology*. 2000;107:1235-1245.
25. Jester JV, Petroll WM, Cavanagh HD. Corneal stromal wound healing in refractive surgery: The role of myofibroblasts. *Prog Retin Eye Res*. 1999;18:311-356.
26. Mohan RR, Hutcheon AE, Choi R, et al. Apoptosis, necrosis, proliferation, and myo-fibroblast generation in the stroma following LASIK and PRK. *Exp Eye Res*. 2003;76:71-87.
27. Corbett MC, Prydal JI, Verma S, Oliver KM, Pande M, Marshall J. An in vivo investigation of the structures responsible for corneal haze after photorefractive keratectomy and their effect on visual function. *Ophthalmology*. 1996;103:1366-1380.
28. Moilanen JA, Vesaluoma MH, Muller LJ, Tervo TM. Long-term corneal morphology after PRK by in vivo confocal microscopy. *Invest Ophthalmol Vis Sci*. 2003;44:1064-1069.
29. Lipshitz I, Loewenstein A, Varssano D, Lazar M. Late onset corneal haze after photorefractive keratectomy for moderate and high myopia. *Ophthalmology*. 1997;104:369-73; discussion 373-4.
30. Lee HK, Lee KS, Kim JK, Kim HC, Seo KR, Kim EK. Epithelial healing and clinical outcomes in excimer laser photorefractive surgery following three epithelial removal techniques: Mechanical, alcohol, and excimer laser. *Am J Ophthalmol*. 2005;139:56-63.
31. Moller-Pedersen T, Cavanagh HD, Petroll WM, Jester JV. Corneal haze development after PRK is regulated by volume of stromal tissue removal. *Cornea*. 1998;17:627-639.
32. Netto MV, Mohan RR, Sinha S, Sharma A, Dupps W, Wilson SE. Stromal haze, myofibroblasts, and surface irregularity after PRK. *Exp Eye Res*. 2006;82:788-797.
33. Ghadhfan F, Al-Rajhi A, Wagoner MD. Laser in situ keratomileusis versus surface ablation: Visual outcomes and complications. *J Cataract Refract Surg*. 2007;33:2041-2048.
34. Kim JH, Kim MS, Hahn TW, Lee YC, Sah WJ, Park CK. Five years results of photorefractive keratectomy for myopia. *J Cataract Refract Surg*. 1997;23:731-735.
35. Gallar J, Acosta MC, Moilanen JA, Holopainen JM, Belmonte C, Tervo TM. Recovery of corneal sensitivity to mechanical and chemical stimulation after laser in situ keratomileusis. *J Refract Surg*. 2004;20:229-235.
36. Tervo K, Latvala TM, Tervo TM. Recovery of corneal innervation following photorefractive keratoablation. *Arch Ophthalmol*. 1994;112:1466-1470.
37. Trabucchi G, Brancato R, Verdi M, Carones F, Sala C. Corneal nerve damage and regeneration after excimer laser photokeratectomy in rabbit eyes. *Invest Ophthalmol Vis Sci*. 1994;35:229-235.
38. Seiler T, Kahle G, Wollensak J. Scar formation in the cornea after photorefractive

- keratectomy. *Ophthalmologie*. 1995;92:492-495.
39. Moilanen JA, Holopainen JM, Vesaluoma MH, Tervo TM. Corneal recovery after la-sik for high myopia: A 2-year prospective confocal microscopic study. *Br J Ophthalmol*. 2008;92:1397-1402.
  40. Erie JC, McLaren JW, Hodge DO, Bourne WM. Recovery of corneal subbasal nerve density after PRK and LASIK. *Am J Ophthalmol*. 2005;140:1059-1064.
  41. Neira-Zalentein W, Moilanen JA, Tuisku IS, Holopainen JM, Tervo TM. Photorefractive keratectomy retreatment after LASIK. *J Refract Surg*. 2008;24:710-712.
  42. Jackson WB, Casson E, Hodge WG, Mintsoulis G, Agapitos PJ. Laser vision correction for low hyperopia. an 18-month assessment of safety and efficacy. *Ophthalmology*. 1998;105:1727-38; discussion 1737-8.
  43. Williams DK. One-year results of laser vision correction for low to moderate hyperopia. *Ophthalmology*. 2000;107:72-75.
  44. Chen WL, Chang HW, Hu FR. In vivo confocal microscopic evaluation of corneal wound healing after epi-LASIK. *Invest Ophthalmol Vis Sci*. 2008;49:2416-2423.
  45. Gamaly TO, El Danasoury A, El Maghraby A. A prospective, randomized, contralateral eye comparison of epithelial laser in situ keratomileusis and photorefractive keratectomy in eyes prone to haze. *J Refract Surg*. 2007;23:S1015-20.
  46. Torres LF, Sancho C, Tan B, Padilla K, Schanzlin DJ, Chayet AS. Early postoperative pain following epi-LASIK and photorefractive keratectomy: A prospective, comparative, bilateral study. *J Refract Surg*. 2007;23:126-132.
  47. Ghirlando A, Gambato C, Midena E. LASEK and photorefractive keratectomy for myopia: Clinical and confocal microscopy comparison. *J Refract Surg*. 2007;23:694-702.
  48. Rosenberg ME, Tervo TM, Petroll WM, Vesaluoma MH. In vivo confocal microscopy of patients with corneal recurrent erosion syndrome or epithelial basement membrane dystrophy. *Ophthalmology*. 2000;107:565-573.
  49. Zalentein WN, Holopainen JM, Tervo TM. Phototherapeutic keratectomy for epithelial irregular astigmatism: An emphasis on map-dot-fingerprint degeneration. *J Refract Surg*. 2007;23:50-57.

**Timo M.T. Tervo, MD, PhD**  
**Department of Ophthalmology,**  
**University of Helsinki,**  
**Finland**  
**Timo.Tervo@hus.fi**

## Notes

---

---

---

---

---

---

---

---

---

---

---

---

---

---

---

---

---

---

---

---

---

---

---

---

---

---

---

---

---

---


# LASIK and microkeratomes

| Thomas Kohnen, Germany |

## LASIK and microkeratomes

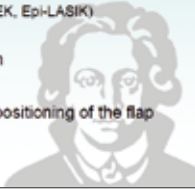
*Thomas Kohnen*

Department of Ophthalmology  
Goethe-University  
Frankfurt am Main, Germany



## Surface treatments

1. epithelia removal
  - mechanical (PRK, ASA)
  - Epithelial flap (LASEK, Epi-LASIK)
2. excimer laser ablation
3. wound treatment / repositioning of the flap



## LASIK (laser in situ keratomileusis)

1. femtosecond laser / microkeratome
  - flap cut
2. excimer laser
  - ablation
3. flap repositioning



## LASIK (classic)

- microkeratomes (here: BSL)



ACS



Hannu



Zytele XP


## Femto-LASIK




Intralase FS 60  
frequency 50 kHz




## Application



flap




excimer



different systems use different modes of application

advantage: variable settings!

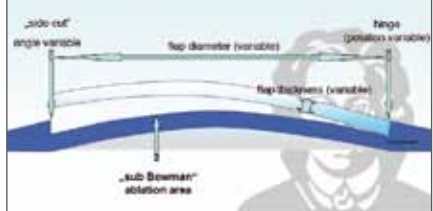


## Comparison of application modes

	AMO IntraLase	Ziemer	Femtec 2010	Carl Zeiss Meditec
flap settings	variable	variable	variable	variable
suction	limbus	limbus	limbus	cornea
application	flat	flat	curved	curved

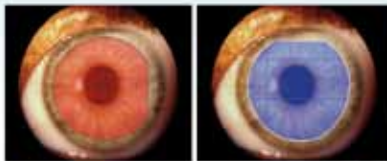
## Femto-LASIK

flap architecture fs-LASIK (here: IntraLase)



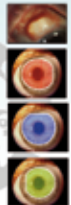
## Hinge positioning

nasal hinge vs. superior hinge



## Hinge positioning variable

- sicca
- scars
- bleps
- flat and steep corneas
- safety

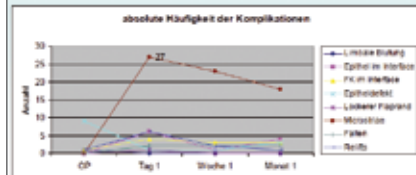


## Frankfurt results

- no free-caps or button-holes
- no suction-loss or incomplete stromal cuts
- 3/308 incomplete side-cuts (about 20°)  
– diamond knife treatment



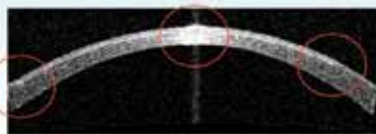## Frankfurt results





## Frankfurt results


Visante OCT scan (Carl Zeiss Meditec): IntraLase femto-LASIK flap



• Jorges R, Kohnen T. Corneal architecture of femtoresect laser and microkeratome. Eye Imaged by OCT. J Cataract Refract Surg 2009; 35:1548

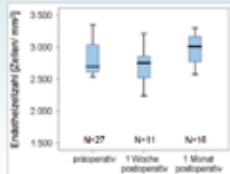
## Frankfurt results

cut architecture comparison femto laser vs. microkeratome (Visante OCT)



• Jorges R, Kohnen T. Corneal architecture of femtoresect laser and microkeratome. Eye Imaged by OCT. J Cataract Refract Surg 2009; 35:1548

## Frankfurt results



- preoperative: 2751,37±387,09 cells/mm<sup>2</sup>
- 1 week: 2706±296,77 cells/mm<sup>2</sup>
- 3 months: 2919,94±291,18 cells/mm<sup>2</sup>

no loss in endothelial cell count with FS60

## Microkeratome: IOP

Bradley JC, McCartney DL, Greenen GA.\*

- human bulb
- dynamic measurement during LASIK
- comparison of three microkeratomes
  - Ceramza-Barraquer (Morfe Inc.)
  - Innovatome (Innovative Optics Inc.)
  - Hansatome (Bausch & Lomb)

mean IOP during appplanation and cut

- 154,7 mm Hg, 151,8 mm Hg, und 175,8 mm Hg

\*Continuous intraocular pressure recordings during corneal microkeratome measurements. Invest Ophthalmol Vis Sci 2007;48:12

## Microkeratome vs. Femto: IOP

- IOP rises during flap cut

	microkeratome	femto-laser
Hernández-Vedego JL, Teus MA, Román JM, Bolívar G. Invest Ophthalmol Vis Sci. 2007;48:68-72	122.52 ± 30.40 mm Hg*	89.24 ± 24.26 mm Hg*
	160.52 ± 22.73 mm Hg†	119.33 ± 15.99 mm Hg†

\* During suction, † during laser application / keratome cut

Thank you for your kind attention!

Thomas Kohnen

Department of Ophthalmology  
Goethe-University  
Frankfurt am Main, Germany

# Notes

---

---

---

---

---

---

---

---

---

---

---

---

---

---

---

---

---

---

---

---

---

---

---

---

---

---

---

---

---

# Laser eye surgery for refractive errors

| Dimitri Azar, United States |

---

Tohru Sakimoto MD, Mark I Rosenblatt MD, Dimitri T Azar MD

**Several laser and non-laser refractive surgical procedures have been used to modify the shape of the cornea and correct myopia, hyperopia, astigmatism, and presbyopia. Introduction of the excimer laser to reshape the cornea has resulted in remarkable developments in the correction of these refractive errors. Combined with other advanced ophthalmological instruments, laser refractive eye surgery has resulted in a substantial rise in the safety, efficacy, and predictability of surgical outcomes. Despite these advances, certain limitations and complications persist. In this review, we describe the history, preoperative assessment, surgical techniques, outcomes, and complications of laser refractive surgery.**

The function of the anterior segment of the eye (cornea and lens) is to focus incoming rays of light onto the lightsensing element of the eye—the retina. The bending of incoming light rays, termed refraction, is predominantly done by the cornea at the interface between air and the tear film. Of the 60 D of total refraction, about two-thirds is achieved by the cornea.<sup>1</sup> The remainder of the refractive power is provided by the lens, which is also capable of changing its shape to modulate the total refractive power.

Refractive errors have been traditionally divided into categories on the basis of the location of the focus of parallel light rays, emanating from infinity (equivalent to a distant object), relative to the retina. Emmetropia describes a refractive situation in which the light rays are perfectly focused on the fovea. Myopia (near-sightedness) arises when the light rays are focused in front of the retina. The hyperopic (far-sighted) eye focuses rays from distant objects at a theoretical point behind the retina. Astigmatism represents the differential focusing of light passing through various corneal meridians. The emmetropic, myopic, or hyperopic eye focuses light in a way similar to a spherical lens, and the astigmatic eye focuses light like a spherocylindrical lens (see panel for definitions of terms used in this review).

A complex optical system, such as the human eye, cannot merely be divided into spherical and cylindrical components, although the prescription of glasses does just that. Wavefront aberrometry has become available for the measurement of more subtle, and often major, optical aberrations in the eye.<sup>2</sup> These aberrometres

measure how the optical system alters a wavefront of light entering the eye or emanating from the retina. Alterations can then be analysed to separate the aberrated wavefront into components, using either Zernike polynomials or Fourier analysis.<sup>3</sup> Detailed descriptions of these techniques are beyond the scope of this review, but how these wavefront aberrations can be treated with laser refractive surgery, one of the most important advances in refractive surgery, is described below.

## Search strategy and selection criteria

We reviewed excimer laser refractive surgical procedures, and excluded other refractive surgical procedures, which do not need laser treatment, such as radial keratotomy, astigmatic keratotomy, epikeratoplasty, thermokeratoplasty, intrastromal corneal implants, and phakic intra-ocular lenses. Our search for outcomes data focused primarily on a search of the US Food and Drug Administration (FDA)-approved clinical trials database for laser vision correction (for US FDA approved clinical trials database see <http://www.fda.gov/cdrh/LASIK/lasers.htm>), which provided the largest and best controlled cohort of laser refractive surgery patient data.

Furthermore, we undertook a comprehensive review of PubMed databases for relevant topics with emphasis on review articles, randomised clinical trials, original articles, including prospective and retrospective studies, and case reports with the key words “refractive surgery,” “laser in situ keratomileusis,” “laser subepithelial keratomileusis,” “Epi-LASIK”, “photorefractive keratectomy,” and “wavefront guided refractive surgery”. Current issues of Investigative Ophthalmology and Visual Science, Ophthalmology, Archives of Ophthalmology, American Journal of Ophthalmology, Cornea, Journal of Cataract and Refractive Surgery, and Journal of Refractive Surgery were thoroughly examined for articles that might have been missed by the PubMed search. We searched publications from the past 10 years, and reviewed the papers identified and their references. Relevant information from recent ophthalmic corneal and refractive surgical textbooks was also identified. For every study included in this review, the quality of the study was assessed.

Masked, prospective, randomised trials were deemed to represent the best quality evidence, followed by cohort studies, then retrospective studies, and finally case series and case reports. Although the FDA data used in this article represented uncontrolled cohort studies, the surveillance provided by FDA monitoring and review resulted in a better quality than that of non-FDA studies with the same basic design. Furthermore, the number of patients included in the FDA-sponsored trials was large, which added to the importance of these studies in assessing the refractive surgical outcomes.

## History of refractive surgery

Although scientists such as Da Vinci proposed theories as to the source of refractive errors,<sup>4</sup> the first systematic analysis of the nature and results of refractive errors came from Francis Cornelius Donders. His classic treatise, “On the anomalies of accommodation and refraction of the eye”, outlined the fundamental principles of physiological optics.<sup>5</sup> Ironically, in this treatise, Donders railed against surgical attempts to correct refractive errors by altering corneal shape. A procedure associated with corneal incisions to correct astigmatism was later then attempted by Hjalmar Schiøtz in 1885.<sup>6</sup> Most other early attempts at refractive surgery were also limited to the use of incisions to treat astigmatism.<sup>7-9</sup>

Modern refractive surgery extended corneal reshaping to treat myopia and astigmatism. Throughout the 1930s and 1940s, Sato<sup>10</sup> published several reports, describing his attempts to refine incisional refractive surgery with anterior and posterior corneal incisions. The Russian ophthalmologist, Fyodorov<sup>11</sup> later developed a systematic process of anterior radial keratotomy and treated thousands of myopic patients with greater predictability.

Lamellar surgery was first introduced by Jose Barraquer;<sup>12</sup> he invented keratoplasty procedures that involved the transplantation of corneal tissue of a size different from the host size to alter the curvature of cornea. He also invented a series of lamellar procedures and developed a formula that represented the relation between the added corneal thickness and the change in refractive power, later called Barraquer’s law of thickness.<sup>13</sup>

The transition from incisional to ablative laser refractive surgery arose with the development of excimer laser technology. Although lasers were initially used to create anterior radial keratotomy incisions or for thermal shrinkage of collagen-laden corneal tissue (in the form of laser thermal keratoplasty), the most successful and widely used technique is ablation of corneal tissue with the excimer laser. Excimer lasers use argon fluoride gases to emit ultraviolet laser pulses. Taboda and Archibald<sup>14</sup> reported the use of the excimer laser to reshape the corneal epithelium in 1981 at the Aerospace Medical Association Meeting. In 1983, Trokel and colleagues<sup>15</sup> showed how the excimer laser could be used to ablate bovine corneal stroma. Their study also identified an excimer laser emission of 193 nm as ideal in terms of increasing to a maximum ablation efficiency, and limiting collateral thermal damage to the surrounding collagen within the cornea. In 1985, Seiler did the first excimer laser treatment in a blind eye. He later did the first excimer laser astigmatic keratotomy.<sup>16</sup> The first FDA trials were initiated by L’Esperance and consisted of photorefractive keratectomy in a blind eye.<sup>17</sup> McDonald and colleagues<sup>18</sup> then did the first photorefractive keratectomy on a seeing eye with myopia.

Jose Barraquer's pioneering work, including the use of lamellar procedures to subtract corneal stromal tissue and the development of the first microkerotomes, set the stage for laser in situ keratomileusis (LASIK) surgery.<sup>13,19</sup> Ruiz and Rowsey<sup>20</sup> modified Barraquer's technique to undertake keratomileusis in situ with a geared automated microkeratome. In the early 1990s, Pallikaris and colleagues<sup>21</sup> and Buratto and colleagues<sup>22</sup> independently described a technique that combined two existing technologies: the microkeratome and the excimer laser. Pallikaris coined the term LASIK for this new technique, which has become a widely used refractive technique worldwide.

## **Panel: Glossary**

### **Accommodation**

The adjustment of the total refractive power of the eye to allow seeing at various distances. Accommodation is effected mainly by changes in the convexity of the lens.

### **Artificial tears**

Topical eyedrops, often formulated to match the pH of human tears. Artificial tears are used to soothe the eyes, moisturise dry spots on the eyes, supplement the eye's own tears, and protect the eye from irritation.

### **Astigmatism**

A defect of an ocular structure (most often the cornea), causing parallel rays of light to be refracted without meeting at a single focal point. An imperfect blurred or smeared image is formed on the retina.

### **Cyclopentolate**

An anticholinergic topical eyedrop used, especially in the form of its hydrochloride  $C_{17}H_{25}NO_3 \cdot HCl$ , to dilate the pupil, and relax the ciliary body of the eye for ophthalmological examination and measurement of the refractive error of the eye in the absence of accommodation.

### **Emmetropia**

The absence of refractive errors of the eye with its accommodation relaxed. In emmetropia, parallel rays of light are all brought accurately to a focus upon the retina of the unaccommodating eye.

### **Epi-LASIK**

Epi-LASIK includes mechanical separation of the corneal epithelial layer, as a sheet, from the underlying stroma. After excimer laser ablation, the epithelial sheet is repositioned over the treatment zone.

**Excimer laser**

Excimer lasers are ultraviolet gas lasers. The term excimer is a contraction of excited dimer. At first, intermediary structure for the excited state of these laser heads was thought to include the formation of dimers, two atoms of the same element. Although the gas halide is now recognised as the activated intermediary, instead of a dimer, the term excimer is broadly accepted.

**Femtosecond laser**

Femtosecond lasers are neodymium glass lasers able to generate femtosecond pulses with high output and short exposure time. The pulses are focused to preset depths below the corneal surface. Blunt separation of the photodisrupted corneal stroma creates the LASIK flap.

**Flying spot**

Flying spot ablation uses a computer-controlled small fixed diameter beam that allows for peripheral ablation or customised ablation pattern. This technique needs prolonged ablation time, and, not uncommonly, it is coupled with eye-tracking systems.

**Hyperopia**

A condition in which visual images come to a focus behind the retina of the eye. Accommodation often improves distance vision, but might not be sufficient to improve near vision.

**Keratotomy**

Surgical excision of part of the cornea.

**Keratoconus**

Progressive thinning of the central cornea, resulting in corneal bulging and formation of a rounded cone. Keratoconus produces moderate to severe corneal distortions and is often associated with myopia and irregular astigmatism.

**Keratomileusis**

Keratoplasty in which the anterior lamellae of the cornea are removed, frozen, reshaped, and reinserted to correct refractive error.

**Laser in-situ keratomileusis**

LASIK is a refractive surgical procedure that permanently changes the shape of the cornea with an excimer laser and a microkeratome or femtosecond laser. The microkeratome or femtosecond laser produces a hinged lamellar flap in the cornea. The flap is folded back, exposing the corneal stroma. Pulses from a computer-controlled excimer laser vapourise a portion of the stroma before the flap is replaced.

**Myopia**

A condition in which parallel rays of light are bent to a focus in front of the retina of the eye. In myopia, the cornea might be too steep or the axial length of the eyeball might be too long, resulting in defective vision of distant objects.

**Presbyopia**

A visual condition that generally becomes apparent in middle age and in which loss of elasticity of the lens of the eye causes defective accommodation and inability to focus sharply for near vision.

**Photorefractive keratectomy**

The use of laser ablation to reshape the stromal surface of the cornea for the correction of myopic or hyperopic refractive errors, or both.

**Phototherapeutic keratectomy**

A method to treat corneal pathology using ablative laser energy.

**Radial keratotomy**

A surgical operation on the cornea to correct myopia. This operation includes making a series of incisions in a radial pattern, resembling the spokes of a wheel, to flatten the cornea.

**Visual acuity**

The relative ability of the visual system to resolve detail, usually expressed as the reciprocal of the minimum angular separation, in minutes of arc, of two lines just resolvable as separate and that forms in the average human eye an angle of one minute of arc; often measured by Snellen test, a test presenting letters of graduated sizes to establish the smallest size that can be read at a standard distance (a 20/20 letter located 20 ft away from an eye subtends an angle of 5 minutes of arc at the eye). The normal acuity in the human eye is 20/20, although some eyes are capable of 20/15 or even 20/10 acuity.



## Preoperative assessment

### Patients' history

The preoperative assessment for laser refractive surgery begins with careful acquisition of the patient's ophthalmic history and general medical history. In view of the elective nature of refractive surgery, the selection of appropriate surgical candidates is paramount. Active infection or intra-ocular inflammation is a contraindication for laser refractive surgery. However, surgery on patients with cured or controlled disease can be more controversial. A history of bacterial keratitis would not exclude surgery, but even a remote history of herpetic keratitis is believed by many to contraindicate laser refractive surgery, since application of the laser can potentially stimulate herpes simplex virus re-activation.<sup>23</sup> Most refractive surgeons hesitate to undertake laser surgery on eyes with a history of uveitis. Although not absolute contraindications to laser surgery, a history of glaucoma, retinal detachment, ocular trauma, and previous ocular surgery might affect the decision to undertake surgery or alter the surgical plan in substantial ways. For example, after central corneal excimer laser ablation, the cornea is thinned and measurements of intraocular pressure might be artifactually low. Postoperative monitoring of the intraocular pressure in glaucomatous eyes might thus become more difficult. A patient with well-controlled glaucoma might still be a candidate for refractive surgery, but a patient with severe disease should defer surgery.

With the removal of tissue by laser refractive surgical techniques, the presence of keratoconus is a strong contraindication for LASIK surgery. Creation of a lamellar flap and tissue removal can destabilise an already ectatic cornea and worsen the condition. Some researchers<sup>24</sup> have suggested that surface ablation might be acceptable in some individuals, although this issue remains controversial. Also of importance is the identification of keratoconus suspects or forme fruste keratoconus, which might be a contraindication for LASIK surgery.

A patient's lifestyle, vocation, and hobbies might also affect their selection for surgery, and the choice of vision correction modality. Participation in contact sports is a contraindication for LASIK surgery because of the risk of flap trauma. In view of the limitations of the surgery, patients who can tolerate zero risk to vision or need perfect stereopsis (and who presently have good vision and stereovision with other forms of correction) for their jobs or hobbies might not be good candidates for laser refractive procedures. The armed services has recognised that soldiers should be encouraged to pursue surface ablation instead of LASIK to avoid the risks associated with flap trauma.<sup>25</sup>

A history of contact lens use and the length of time the patient has refrained from use before the assessment should be established. In general, patients should not have used soft contact lenses for at least 1 week before the assessment, and patients who wear rigid lenses should wait a minimum of 3 weeks. Even with these guidelines, there are several examples of contact lens-induced changes in corneal shape that persist for months.<sup>26</sup>

Patients should have stable refractions, and a history of frequent or recent changes in the refraction should delay surgery. Patients younger than 18 years of age might not have stable refractions, and surgery on these patients should be deferred.

## **Refraction**

A careful refraction is a mainstay of laser refractive surgery. Although an automated refraction might serve as a useful starting point, a subjective manifest refraction must be carefully done. A hand-held retinoscope can also be used to estimate the refraction and can also identify corneal irregularities. Once the manifest refraction has been completed, the patient's ability to accommodate (focus at near) should be paralysed with a cycloplegic agent—eg, cyclopentolate 1%.

Refractions obtained by any of these methods should be compared to allow surgical planning. Consistency between measurements should be the aim, and any disparities should be explained before surgery. The degree of refractive error also helps to establish the eligibility of the patient for treatment with a particular surgical method on a specific laser platform. When possible, one should attempt to use excimer laser systems within US Food and Drug Administration (FDA)-approved treatment ranges. Refractive error outside these ranges can be treated with the laser outside of FDA approval (with informed consent from the patient), on an alternative platform with a larger approved treatment range, or only partly treated.

## **Measurements of corneal curvature**

Keratometry can measure the steepest and flattest corneal meridians. These measurements usually correlate with the refraction unless the lens is a source of astigmatic refractive error. Corneas outside normal ranges ( $>47$  D or  $<39$  D) should create suspicion. The degree of cutting of lamellar flaps with a microkeratome can be altered, according to the keratometry readings.

Automated corneal topography can be done to measure the corneal curvature at multiple points across the cornea. The corneal relief map identifies the overall corneal shape. Irregularities of shape consistent with ectatic disorders, such as

keratoconus and pellucid marginal degeneration, can be identified by careful analysis of these maps. Moreover, a predisposition for these disorders, forme fruste ectasia, might be identified, even when no manifest disease is seen via slit-lamp biomicroscopy.

## **Pachymetry**

Central corneal thickness is generally measured by ultrasonic pachymetry. The removal of large amounts of corneal tissue during laser refractive surgery can lead to weakening of the cornea and ectasia, resulting in loss of vision and surgical effect. Knowledge of the central corneal thickness provides the surgeon with an estimate of the corneal residual bed (the amount of stroma posterior to the deepest ablation). At least 250  $\mu\text{m}$  (we prefer a more conservative value of 300  $\mu\text{m}$ ) thickness should remain at the end of the procedure to maintain the structural integrity of the cornea. The pachymetry, combined with the level of refractive error, directs the surgical planning.

## **Pupillometry**

Pupil size under both bright and dim illumination is tested. Excimer laser ablation treatment diameters can be adjusted. The role of pupil size (especially the size relative to ablation diameter) as a risk factor for postoperative glare and halos is controversial. However, most refractive surgeons agree that pupil size, although not the only factor in glare, might play a substantial part.<sup>27</sup> When possible, an attempt to make the treatment diameter greater than the largest pupil size might reduce induced aberrations and prevent the symptoms of glare and halos postoperatively. However, for a given amount of intended correction, the larger the ablation diameter, the greater is the required treatment depth and the greater is the risk of LASIK-induced ectasia.

## **Tear production**

Tear production and quality can be assessed by examining the tear meniscus and persistence at the slit lamp. We often undertake a Schirmer's tear production test to obtain a quantitative assessment of the amount of tear production. Dry eye syndrome is a common postoperative complication after laser refractive surgery, and treatment of any pre-existing dry eye can be important. If tear production is extremely low (as in Sjögren's syndrome) and if a patient's symptoms do not improve with appropriate treatment, the patient might benefit from deferring LASIK refractive surgery. Surface ablation might be less risky in such situations.

## **Complete eye examination**

Further to the examination components listed above, candidates for potential refractive surgery should have other tests, including tonometry, slit-lamp biomicroscopy, motility, ocular alignment, and dilated fundus examination. Anatomical factors that could affect surgery should be identified. Glaucoma and cataract might affect the patient's candidacy for a refractive procedure, since thinning of the cornea makes intraocular pressure measurements more difficult and progressive cataract can cause the refraction to shift. Eventual cataract surgery is affected by previous laser vision correction, since predictable intraocular lens calculations are harder to measure accurately. A myriad of calculation systems that use preoperative and postoperative measurements and nomograms have been developed to help improve intraocular lens calculations after refractive surgery.

Newer modalities, such as high-frequency ultrasound, anterior segment ocular coherence tomography, and Scheimflug cameras, might improve our ability to identify changes in the anterior and posterior corneal surface relation and improve lens calculations further.

## **Counselling**

Perhaps the greatest factor in assuring the ultimate success of laser refractive surgery is communication during the preoperative visit. Refractive surgical techniques have a high degree of objective success. Patients should be given realistic expectations as to what refractive surgery can offer and should be made aware of the risks of surgery. Several refractive surgical options available to patients, many of which do not use the excimer laser, have grown in popularity over the years. A discussion of these newer techniques and how they might apply to the specific patient, might be necessary. Patients will go to their assessment with ever more knowledge as the internet becomes a burgeoning source of medical information and misinformation. The refractive surgeon should be prepared to deal with the questions that inevitably arise from this information.

## **Surgical techniques**

Several effective options for laser refractive surgery are available. Navigating the complex array of options can be difficult, but more choices also bring the opportunity to meet more of the needs of an individual patient. The choices can broadly be divided into lamellar (LASIK) and surface (photorefractive keratectomy, laser epithelial keratomileusis [LASEK], and Epi-LASIK) ablation.

## LASIK

LASIK is lamellar laser refractive surgery in which the excimer laser ablation is done under a partial-thickness lamellar corneal flap. Until recently, the lamellar flap could only be made with a microkeratome. The microkeratome uses an oscillating blade to cut the flap after immobilisation of the cornea with a suction ring. Microkeratomes from several companies cut the lamellar flaps with either superior or nasal hinges, and can cut to depths of 100–200 µm.

A femtosecond laser has been developed that can etch lamellar flaps within the cornea stroma at a desired corneal depth. The femtosecond laser provides more accuracy in flap thickness than previous methods; the microkeratome cuts can vary widely in depth, even with the same preset thickness.<sup>28</sup>

Femtosecond laser flap creation is less dependent on the corneal curvature and might be more reliable in cases of steep or flat corneas, which can be at greater risk for irregular corneal cuts. Increased cost, surgical time, and diffuse lamellar keratitis are potential limitations of the femtosecond laser keratome. The incidence and severity of diffuse lamellar keratitis are ameliorated by the use of intensive perioperative topical corticosteroids.

Once the flap has been created, it is reflected at its hinge away from the corneal stroma. The patient is asked to fixate on a centration light, an eye-tracker is engaged to adjust for any eye movements during the ablation, and a preprogrammed excimer ablation is done. Variables such as refractive target, treatment diameter, and treatment blend zone can be altered for most laser platforms. Excimer laser pulses might be applied as a variable spot scanning pattern or as a flying spot pattern. The ablation might either correct sphere and cylinder error, or be wavefront-guided. After the ablation has been completed, the stromal bed is irrigated and the corneal flap is repositioned.

Compared with surface ablation, LASIK results in earlier and faster improvement of uncorrected visual acuity, and has less (or almost no) postoperative discomfort, improved stability, and predictability. With LASIK, however, the risks of flap-related complications (wrinkles, debris, folds, buttonhole, and diffuse lamellar keratitis) may be associated with the creation of the lamellar flap.

### Surface ablation

This class of laser refractive surgical procedure uses the excimer laser to ablate the most anterior portion of the corneal stroma. These procedures do not require

a partial thickness cut into the stroma, and thus leave a larger residual bed to retain the cornea's biomechanical strength. The ablation of the anterior stroma and, in particular, ablation through Bowman's layer does, however, lead to a wound-healing response that might result in greater stromal haze and scarring than that in LASIK. Recovery after surface ablation is both substantially slower and more painful than that after LASIK. LASIK patients often have markedly improved vision 2–3 days after surgery and have little or no pain; patients who receive surface ablation typically have episodes of moderate to severe pain for 1–4 days after the procedure, and usually do not achieve vision similar to LASIK patients for several weeks. Several reports have shown good visual outcomes after photorefractive keratectomy for low-to-moderate hyperopia.<sup>29–31</sup>

Three methods of surface ablation are in use: photorefractive keratectomy, LASEK, and Epi-LASIK. These methods differ in the way the epithelial layer is handled. In photorefractive keratectomy surgery the epithelium is removed, a large epithelial defect ensues, and healing occurs by migration and division of surrounding epithelium. The epithelium might be removed in several ways, including excimer laser destruction, mechanical debridement with a surgical blade, abrasion with a brush, or use of alcohol to loosen the epithelium.

In LASEK and Epi-LASIK surgery, the patient's original epithelial sheet is repositioned onto the stromal bed after laser ablation. After the ablation, this epithelial sheet is placed back into its original position using preplaced corneal surface marks.<sup>32</sup> The epithelial alignment is protected from blinks and eye movements by the addition of a bandage contact lens. A series of techniques have been developed, each differing slightly in the way in which the flap is chemically loosened and then reflected away from the cornea. In Epi-LASIK, a purely mechanical means of epithelial dissection allows the creation of an epithelial sheet, which is repositioned on the stroma after excimer laser ablation. Several epikeratomes have been developed for this purpose. These devices differ from LASIK microkeratomes in that the blade and its angle of cutting are optimised for a clean subepithelial dissection, which does not disrupt the corneal stroma.<sup>33</sup>

Whether the outcomes of photorefractive keratectomy, LASEK, and Epi-LASIK actually differ is unclear, in part because the viability of the replaced epithelial sheet is uncertain. 6 months after surgery, the procedures have very similar outcomes with respect to acuity and refractive error. It is tempting to hypothesise that if the epithelium is viable, it might serve to quell some of the pain experienced as a result of the epithelial defect. The biological properties of the epithelium might also modulate corneal wound healing, and inhibit haze formation after surgery. Laboratory data suggest that not only is the epithelium viable after carefully controlled

epithelial lifting, but that cell death in keratocytes below the treatment might be reduced in LASEK as compared with photorefractive keratectomy.<sup>34</sup>

### **Conventional versus wavefront-guided treatment**

Whether the surgeon does LASIK or surface ablation, the “Where?” in laser refractive surgery is decided. With the advent of wavefront aberrometry and lasers capable of translating these data into ablation profiles, we now have a choice in “How?” the laser surgery will be done. Conventional ablations make use of data obtained during manifest and cycloplegic refractions. The ablation profile will contain a spherical component and an astigmatic component when applicable. Although the profiles incorporate additional nomogram adjustments and additional components for blending the transition zone between the treated and untreated stroma, they essentially treat what glasses have been treating for hundreds of years.

Wavefront-guided treatments allow optical properties beyond spherical and cylindrical defocus to be corrected. Wavefront aberrometers capture data that describe the optical aberrations of a patient’s eye as an optical system.<sup>35,36</sup> These measurements take into account factors beyond corneal irregularities. Aberrations from other sources, however, can be corrected at the corneal plane by the excimer laser guided by the wavefront data. Preoperative analysis of higher-order aberrations (those beyond defocus corrected by glasses) can be done preoperatively and quantified. Whether the degree of higher-order wavefront aberrations should be the determinant for a particular eye to receive wavefront-guided ablation is still unclear. Refractive surgery itself produces higher-order aberrations, and it can be argued that even in the patient with a perfect preoperative wavefront, wavefront-guided treatment should be done to prevent the inevitable increase of aberrations caused by the procedure. Since wavefront-guided treatments correct more components, it is not surprising that for a given eye the wavefront-guided treatment will ablate deeper into the stroma. The increased depth of these ablations might hinder their use in higher myopia or patients with thin corneas (patients who might have a great deal of higher-order aberrations).

The effectiveness of custom treatments to correct aberrations after previous surgery is also not well established. In theory, affected patients might benefit most from a wavefront-guided enhancement. In practice, however, whether the algorithms used to translate the aberrometry data into ablation profiles have been optimised for enhancements, particularly when the aberrations are caused by previous, often complicated refractive surgery, is unclear.

## Outcomes of laser eye surgery

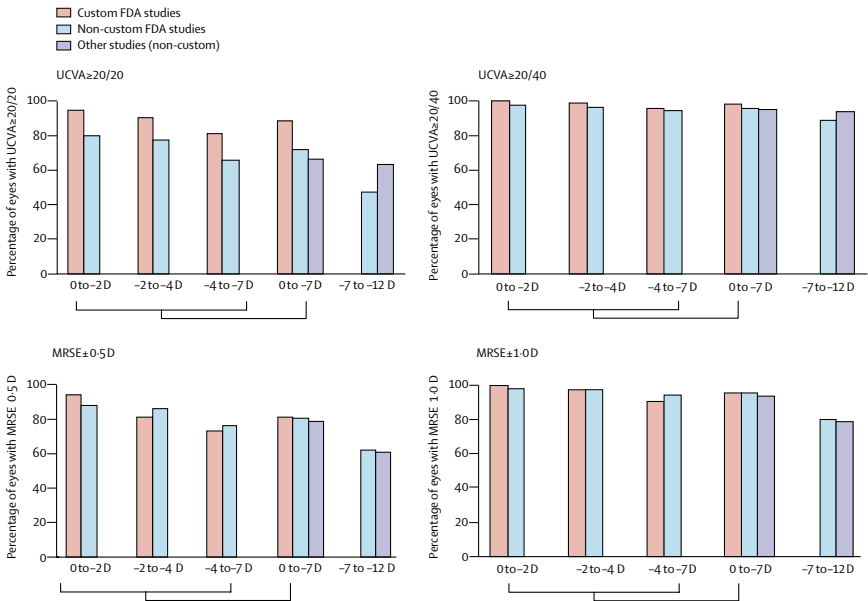
Outcome data are available from multiple sources, including the FDA, laser-producing companies, and independent investigators. The number of patients, outcome measures, and length of follow-up might differ in these sources, making data comparison somewhat problematic. For this review, we have divided the available data into two groups: data obtained from the FDA clinical trial database of laser platforms,<sup>37-49</sup> and other data from laser companies or individual investigators.<sup>50-66</sup> FDA data are derived from well controlled and monitored investigations of outcomes in a large cohort of patients and are rigorously analysed. We grouped data from multiple FDA studies for myopia into four subgroups— 0 to -2 D, -2 D to -4 D, -4 D to -7 D, and -7 D to -12 D—and those for hyperopia into three subgroups—0 to +2 D, +2 D to +4 D, and +4 D to +6 D. The cut-offpoints were included in the corresponding subgroups on the basis of the sub divisions within the individual FDA applications. The other sources of data varied substantially in methodology and level of analysis. Follow-up times for these other sources of data were often insufficient to accurately show reasonably final surgical outcomes.

Most published analyses of data have pitted laser platform against laser platform. This head-to-head comparison of laser platforms in published work might be driven in part by marketing concerns. We have grouped data for different treatment modalities (conventional vs wavefront-guided treatments) and for every type of refractive error treated (low or moderate myopia vs high myopia vs hyperopia), when sufficient data for comparison were available. In this way, we were able to assess the effectiveness of laser refractive techniques, and not just how well a particular laser works.

We compared a combination of measures of refraction and visual acuity. Fortunately, these variables are primary outcomes in almost all studies of laser vision correction. Manifest refraction spherical equivalent is the amount of refractive error that remains after ablation, and combines both the spherical and astigmatic correction. Manifest refraction spherical equivalent thus measures the ability of the laser refractive procedure to reach the target refraction. We analysed postoperative manifest refractive spherical equivalents to determine the percentage of patients whose residual refractive error fell within about 0.50 D or about 1.0 D of the target error. Visual acuity is a subjective measure of the patient's ability to resolve objects (usually letters) at under defined lighting conditions. Although this measure does not necessarily replace the patient's visual function in his or her environment, it does provide a standardised way to assess the success of the procedure. The number of patients with uncorrected visual acuities of 20/20 (normal perfect vision) or more and of 20/40 (functional vision usually allowing the patient to drive without glasses) or more was analysed in this review. A loss of best spectacle-corrected

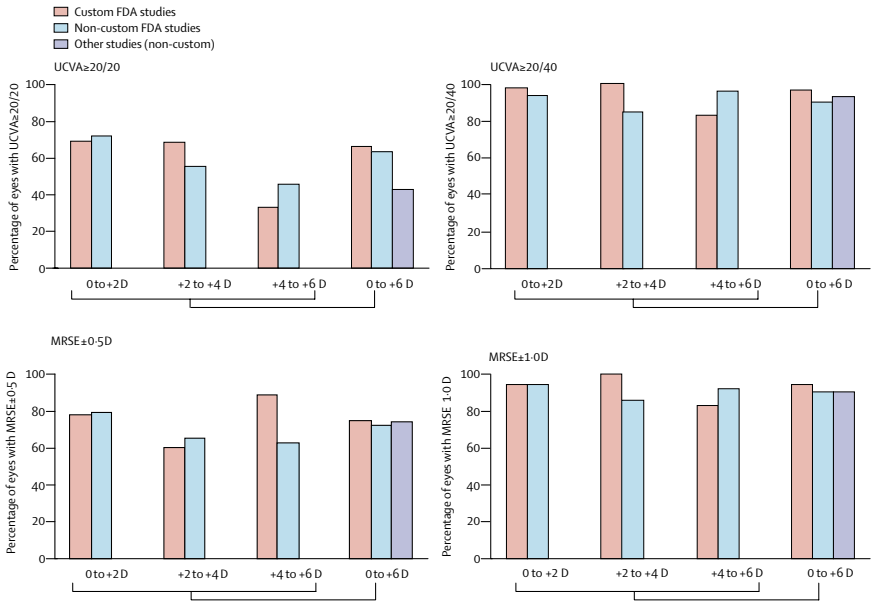


visual acuity of more than two lines on the Snellen chart was used to measure negative outcomes for the procedures. Our results are shown in figures 1–3. Published results were obtained by the following criteria: (1) randomised prospective study ( $n \geq 25$ , follow-up period  $\geq 3$  months), (2) controlled prospective study ( $n \geq 50$ , follow-up period  $\geq 3$  months), and (3) case series ( $n \geq 100$ , follow-up period  $\geq 6$  months). However, it should be noted that even though the Snellen chart-based visual acuity has been judged as the standard method of assessing the outcomes of ophthalmic surgery, the variables mentioned above might not be enough to assess the satisfactory functional visual outcomes after refractive surgery. Laser refractive surgery can cause higher-order aberrations, such as glare, halo, or night-vision disturbance, and other variables such as contrast sensitivity, and scotopic and mesopic vision. Wavefront aberrometers will probably have a greater role in measuring outcomes.



**Fig 1: Visual outcomes of LASIK for myopia at 3–6 months after surgery**

UCVA=uncorrected visual acuity. MRSE=manifest refraction spherical equivalents. For every assessment, results for low myopia with error 0 to -7 D (individual ranges and grouped) compared with high myopia with refractive error -7 D to -12 D.<sup>37–45, 50–61</sup>



**Fig 2: Visual outcomes of LASIK studies for hyperopia**

UCVA=uncorrected visual acuity. MRSE=manifest refraction spherical equivalents. Data analysed for different degrees of hyperopia and for all hyperopia.<sup>46–49,62–66</sup>

## LASIK outcomes

Low to moderate myopia (conventional laser ablation) Those with low (–4 D or less) or moderate (–4 D to –7 D) myopia represent the largest population of patients undergoing laser refractive surgery. They represent the largest proportion of the general population; also, patients with higher myopia might not qualify as candidates for laser surgery. In view of the preponderance of low to moderate myopia, it is not surprising that the first FDA-approved use of the excimer laser for LASIK was for these patients.

Grouped data from the FDA-approved laser platforms (LADAR Vision, Alcon, Fort Worth, TX, USA; EC5000, NIDEK, Gamagori, Japan; S2 & S3, VISX, Santa Clara, CA, USA; Technolas 217a, Bausch & Lomb, Rochester, NY, USA; Allegretto Wave, Wave-Light, Sterling, VA, USA)<sup>37–42</sup> for low to moderate myopia showed manifest refraction spherical equivalent within about 1.00 D of 96% and within about 0.50 D of 81%. Similarly, uncorrected visual acuities better than 20/40 were measured in 96%, although

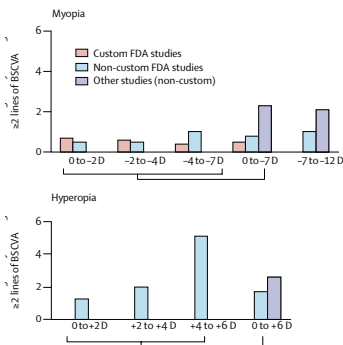
72% of patients had vision equal to or better than 20/20. A loss of best spectacle-corrected visual acuity of more than two lines was noted in just under 1.0% of patients.

Comparison of the FDA data with other studies revealed similar outcomes with respect to efficacy. Combined data from the non-FDA dataset show manifest refraction spherical equivalent within about 1.00 D of 94% and within about 0.50 D of 79%. About 95% of patients were 20/40 or better and 67% were 20/20 or better uncorrected. These other studies did, however, have a higher rate of best spectacle-corrected visual acuity loss totalling more than 2.3%. These overall excellent success rates explain the popularity of laser refractive surgery.

### High myopia (conventional laser ablation)

With the larger degree of refractive error and the concomitant need to remove more tissue in higher myopia, this group of patients is often analysed separately when measuring outcomes of refractive surgery. In the high myopia group, FDA data showed manifest refraction spherical equivalent within about 1.00 D of 80% and within about 0.50 D of 61%. Although 89% of patients were 20/40 or better, less than half (48%) achieved 20/20 or better. A loss of best spectacle-corrected visual acuity of greater than two lines was recorded in only 1% of patients.

Similarly, combined data from the non-FDA dataset showed manifest refraction spherical equivalent within about 1.00 D of 79% and within about 0.50 D of 59%. 94% of patients were 20/40 or better; 64% were 20/20 or better. Compared with FDA data, a loss of best spectacle-corrected visual acuity of more than two lines was noted in a higher rate of 2% of patients.



**Fig 3: Safety of LASIK for treatment of myopia or hyperopia**

BSCVA=best spectacle-corrected visual acuity.<sup>37-49,51,52,55-66</sup>

## Comparison of low to moderate versus high myopia

In general, we might expect less accuracy and larger wound-healing effects with the deeper ablations. As the depth decreases, the cornea might also be destabilised, and this instability can further retard the ability to reach a target refraction. With the FDA data, a comparison of manifest refraction spherical equivalent between low-to-moderate and high myopia after LASIK shows a larger residual refractive error in high myopia. The difference between the low-to-moderate myopia of 96% within about 1.00 D and high myopia with 80% was even more indicative when accuracy to within manifest refraction spherical equivalent of about 0.50 D was analysed (81% for the lower myopic group and 61% for the higher myopic group).

This trend was also noted in the analysis of FDA data on final uncorrected visual acuities. For the less myopic group, acuity of at least 20/40 was achieved in 96% of patients as compared with only 89% of the high myopia group. Again, the difference is even more pronounced when better acuities are examined. Less than half (48%) of patients with high myopia achieved acuities of 20/20 or better with LASIK; however, almost 72% of lower myopia achieved this excellent acuity level. Similar analysis of non-FDA data provided similar outcomes.

The cut-offpoint between low-to-moderate and high myopia has been used in published work as a distinction, but these degrees of myopia are somewhat arbitrary. In a subgroup analysis of the FDA data, we noted that correlation between the degree of initial refractive error and the level of residual myopia and poorer acuity was fairly linear, even with the low-to-moderate group. In general, patients with higher degrees of myopia should be told that their likelihood of reaching perfect vision is less than in patients with lower myopia.

The rate of best spectacle-corrected visual acuity loss was essentially the same for all myopic groups. This finding suggests that although the improvement in vision and refractive error might be less for high myopes, the procedure is still likely quite safe in this group. Long-term studies are needed to ascertain the true risk for the high myopes who undergo greater tissue removal. This greater tissue removal might be expected to destabilise the cornea and allow for ectasia and worsening of outcome in susceptible individuals. Data collected at 10-year or 20-year follow-up would allow for a better analysis of this potential occurrence. Wavefront-guided LASIK (custom laser ablation) for myopia.

## Wavefront aberrometers represent a major advance in

our ability to measure subtle, yet visually substantial, optical defects. The outcomes for wavefront-guided LASIK in myopia have been investigated by the FDA for three separate laser platforms. In view of the fewer numbers of non-FDA studies, the differing outcome measurements, and follow-up for these studies, only the FDA data are presented here.

Grouped data from the FDA-approved wavefront-guided laser platforms (LADAR Vision; Technolas 217z; and Star S4 and WaveScan Wavefront System, VISX, Santa Clara, CA, USA, and Bausch & Lomb Technolas 217z)<sup>43-45</sup> for low to moderate myopia showed manifest refraction spherical equivalent within about 1.00 D in 96% of eyes and within within 0.50 D in 81%. Uncorrected visual acuities better than 20/40 were measured in 98%, and 89% of patients had vision equal to or better than 20/20. A loss of best spectacle-corrected visual acuity of more than two lines was recorded in only 0.5% of patients. Wavefront-guided LASIK seems to be most successful in patients who have low myopia, especially for uncorrected visual acuities better than 20/20. 95% of the patients up to -2 D achieved 20/20 or better, as did 91% in the range -2 to -4 D.

## Comparison of wavefront-guided versus conventional laser ablation for myopia

Whether the additional information obtained with wavefront-guided treatments is translated into better ablations and improved acuity compared with conventional LASIK can be determined by comparing the FDA trials data. A marked difference in uncorrected visual acuities of 20/20 or better was seen between wavefront-guided and conventional treatments. In wavefront-guided LASIK, 89% of patients achieved this level of vision. By contrast, with conventional treatment, patients reached 20/20 or better only 72% of the time. These differences were not seen with the 20/40 or better acuity outcome.

There are no substantial differences in postoperative manifest refraction spherical equivalent between conventional and custom treatments. How can one reconcile the similar refractive outcomes in both treatments with the better uncorrected visual acuities outcomes for wavefront-guided treatments? It cannot be certain, but the manifest refraction spherical equivalent measures only spherical and astigmatic error (defocus), which is probably similar in both treatments. The higher-order aberrations, however, are treated in wavefront-guided treatments such that these aberrations are reduced to a minimum (or the rise caused by refractive surgery is ameliorated). The improved acuity is likely explained by the higher number of aberrations remaining after conventional treatments.

Some care should be taken when comparing the FDA data between wavefront-guided and conventional treatments. The data for conventional treatments were gathered with earlier generation laser platforms. Since FDA approval, improvements have been made to the lasers, the software driving the lasers, the laser-tracking devices, and our ability to identify patients who are poor candidates for LASIK. These improvements are unrelated to wavefront technology. The assessment of specific laser platforms is not the purpose of this review, but a current generation laser system (Allegretto Wavelight), which incorporates technological advances unrelated to custom ablation was approved by the FDA in 2003. Treatment results are better than seen with the older generations of laser, though still not as good as those seen with the wavefront-guided lasers in terms of final uncorrected visual acuities. The Allegretto system is wavefront optimised, in that the rise in higher-order aberrations seen after laser vision correction is reduced to a minimum by the ablation algorithm. By contrast with truly wavefront-guided systems, which use actual wavefront data obtained from the eye to be treated, wavefront-optimised systems adjust the ablation profile without actually measuring higher-order aberrations in the patient.

## Hyperopia

For hyperopic LASIK ablations, most of the laser energy is directed at the periphery of the treatment zone with a relative sparing of the central cornea. Centration and tracking are essential factors in obtaining accurate ablations without inducing astigmatism from decentration. Additionally, mechanical weakening of the peripheral cornea might allow the central cornea to bow forward, augmenting the intended laser effect. Wound healing from hyperopic treatments also seems to differ from myopic treatments. The biomechanical changes and the wound healing in hyperopic LASIK cause increased levels of regression after this procedure and limit the total refractive error that can be treated with the LASIK technique.

Grouped data from the FDA approved non-custom laser platforms (Alcon LADAR, VISX S2 & S3, Bausch & Lomb Technolas 217a, and Allegretto Wave WaveLight) showed manifest refraction spherical equivalent within about 1.00 D of 90% and within about 0.50 D of 67%.<sup>46-48</sup> Similarly, uncorrected visual acuities better than 20/40 were measured in 90%, although 63% of patients had vision equal to or better than 20/20. A loss of best spectacle-corrected visual acuity of more than two lines was recorded in just under 2% of patients. Data for non-FDA studies differed substantially from the FDA studies in the proportion of patients achieving 20/20 or better vision.<sup>62-66</sup> This lower level of acuity is noted despite a similar degree of manifest refraction spherical equivalent about 0.50 D in both types of studies. The basis of this difference is not clear.

In FDA-approved custom laser platform (VISX Star S4 & WaveScan Wavefront System),<sup>49</sup> manifest refraction spherical equivalent within about 1.00 D was 95% and within about 0.50 D was 70%. Similarly, uncorrected visual acuities better than 20/40 were measured in 97%, and 66% of patients had vision equal to or better than 20/20. A loss of best spectacle-corrected visual acuity of more than two lines was recorded in 0% of patients.

Unlike the custom versus conventional myopic treatments, it is difficult to draw conclusions on the basis of the comparison between this custom FDA study and noncustom FDA studies for 0 to +6 D hyperopia. For the lower outcome standards (manifest refraction spherical equivalent about 1.00 D and best spectacle-corrected visual acuity of 20/40 or more) the wavefront-guided treatments did show a modest improvement versus the conventional treatments. However, for manifest refraction spherical equivalent about 0.50 D and best spectacle-corrected visual acuity of 20/20 or better, the two types of treatments were equivalent. This finding suggests that although wavefront-guided treatments might prevent some worse outcomes, they do not improve the chances of obtaining the best outcomes. The problems of unpredictable wound healing and biomechanics, which are important determinants in the outcome of hyperopic LASIK, are not necessarily solved by the custom ablation.

### **Outcomes of LASIK for mixed astigmatism**

There are fewer reports available for the LASIK treatment of mixed astigmatism (the refractive condition in which rays of light in one meridian are focused in front of the eye as in myopia and rays of light in the meridian 90° away are focused behind the retina as in hyperopia) than for other problems, probably because there are fewer patients in this group overall, fewer patients in this category elect to have refractive surgery (their preoperative manifest refraction spherical equivalent can often approach zero), and fewer laser systems are approved for the treatment of this refractive condition.<sup>67-70</sup> Patients who do have mixed astigmatism and elect to have treatment have a higher degree of cylinder (poorer acuity than would be expected on the basis of the manifest refraction spherical equivalent alone), and patients with higher levels of astigmatism tend to have less predictable outcomes.

FDA trials for LASIK-treated mixed astigmatism show an improvement in uncorrected visual acuities.<sup>71</sup> Uncorrected visual acuities better than 20/40 were measured in 95%, and 61% of patients had vision equal to or better than 20/20. A loss of best spectacle-corrected visual acuity of more than two lines was recorded in 0% of patients.

## **Outcomes of LASIK for presbyopia**

Presbyopia is an age-related refractive condition in which the eye is no longer able to focus over a broad enough range to allow for both functional near and distance vision. Laser vision correction is unable to correct this condition per se, but can be harnessed to create corneal multifocality and pseudoaccommodation. Attempts to create multifocal corneas using new ablation profiles during LASIK surgery are under investigation in France and South America,<sup>72,73</sup> and hold promise as future techniques to treat presbyopia.

LASIK surgery can, however, treat the symptoms of presbyopia through the use of a technique termed monovision.<sup>74–76</sup> In monovision, the distance refraction for one eye is emmetropic and the distance correction for the second eye is myopic; one eye is set for distance vision and the other for nearer vision. In phakic patients who still have some degree of accommodation, albeit insufficient for their needs, the near eye need not be corrected (or left untreated) at a level of myopia for near alone (about  $-2.75$  D), but instead can be only mildly near-sighted. The outcomes for monovision treatment are dependent not only on the ability of the laser to accurately reach the target refraction, but also on the patient's ability to adjust to anisometropia and the slight decrement in visual acuity and depth perception that arises from the different focal points in each eye. Therefore, the preoperative use of monovision contact lenses might be useful.

There are no FDA trials for the use of LASIK for monovision. Non-FDA data suggest that about 80% of patients will make the adjustment to monovision, and that most patients will adapt to monovision within 3–4 weeks. Perhaps the most important factor for obtaining good outcomes with this technique is proper selection of patients and adequate counselling before the procedure. Patients must understand that improved functional vision, if it does arise, will come only after the adaptation period, and that it comes at some price to both near and distance acuity. When the patient is unhappy, the undercorrected eye can undergo either enhancement (re-treatment) or initial treatment (when the myopic eye was untreated) to balance the eyes. The patient will then need to use reading glasses for near tasks.

## **Outcomes of surface ablations (photorefractive keratectomy and LASEK)**

Surface ablation (photorefractive keratectomy) was the first ablative refractive surgical technique approved by the FDA. Although photorefractive keratectomy came into some disfavour during the late 1990s, surface ablation has seen a partial resurgence for the treatment of refractive error in patients with thinner corneas and low to moderate myopia, as a result of the avoidance of lamellar flap creation and



its associated risks. The improvements in the laser systems can also improve outcomes achieved by surface ablation. The LASEK procedure represents a modification of the original photorefractive keratectomy procedure in which the patient's epithelium is retained (by making an epithelial flap) instead of removed.

The original FDA studies for photorefractive keratectomy were undertaken in 1995,<sup>77</sup> and used laser systems that did not have capabilities of lasers today—eg, advanced software, accurate eye-tracking, and larger ablation zones. In view of the limitations of the lasers used in these studies, analysis of the FDA data alone for photorefractive keratectomy is not likely to yield useful results for today's patients. No FDA trial for the LASEK procedure has been done.

The available data suggest that surface ablation achieves results similar to LASIK. Table 1 provides cumulative data for photorefractive keratectomy and LASEK techniques.<sup>30,50–52,56,57,78–91</sup> Combining all myopia, photorefractive keratectomy achieves best spectacle-corrected visual acuity of 20/20 or more in 61% of patients and of 20/40 or more in 94%, and LASEK achieves best spectacle-corrected visual acuity of 20/20 or more in 74% of patients and of 20/40 or more in 94%. For manifest refraction spherical equivalent, photorefractive keratectomy has a postoperative value of about 0.50 D in 71% of cases and LASEK in 74% of cases. From a refractive standpoint, the techniques seem very similar.

	Myopia		Hyperopia	
	PRK <sup>(10-52,56,57,78-85)</sup>	LASEK <sup>(78,80-88)</sup>	PRK <sup>(10,89-91)</sup>	LASEK <sup>(9)</sup>
Visual range	-1 to -13.0 D	-1 to -12.5 D	+1 to +5 D	+2 to +5 D
UCVA =20/20	2559/4184 (61.1%)	471/637 (73.9%)	474/630 (75.2%)	79/108 (73.1%)
UCVA =20/40	3877/4112 (94.3%)	361/382 (94.5%)	594/682 (87.1%)	98/108 (90.7%)
Within about 0.5 D of MRSE	2955/4158 (71.3%)	451/610 (73.9%)	481/682 (70.5%)	82/108 (75.9%)
Within about 1.0 D of MRSE	3748/4158 (90.1%)	482/538 (89.6%)	581/682 (85.2%)	99/108 (91.7)
Loss of =two lines of BCVA	3/517 (0.6%)	13/610 (2.1%)	14/682 (2.1%)	0/108 (0.0%)

UCVA=uncorrected visual acuity. MRSE=manifest refraction spherical equivalent. BCVA=best spectacle-corrected visual acuity. Data are number (%) unless otherwise indicated. For PRK studies, data published after January, 2000, only were collected.

**Table 1: Cumulated outcomes of photorefractive keratectomy (PRK) and LASEK for myopia and hyperopia**

In comparative studies, LASIK and surface ablation have similar outcomes. The lower values for best spectacle-corrected visual acuity and manifest refraction spherical equivalent listed above for the surface ablation techniques might be the result of inclusion of high myopia. These higher myopia treatments, as discussed in the LASIK outcomes section, in general have poorer and less predictable results. Deep ablations for high myopia via surface ablation also have a greater tendency to produce stromal haze during the wound-healing process and thus might lead to poorer results. Indeed, most surgeons prefer not to do surface ablations in higher

myopia; when they do treat these patients on the surface, they often use wound-healing biomodulators such as mitomycin C. We advise caution in using these biomodulators, since each has its own complications, and the long-term sequelae of their use for refractive surgery are not well understood. Indeed, evidence suggests the loss of stromal keratocytes after application of mitomycin C.<sup>92</sup>

## **Complications and management**

Serious complications from refractive surgery are rare, as evidenced by the low rate of loss of best spectacle-corrected visual acuity. However, as with any surgery, complications might occur either intraoperatively or postoperatively.<sup>93</sup> Risk-benefit calculations of surgery are somewhat different for refractive surgery, since procedures are generally done electively in healthy eyes with excellent visual potential.

### **Intraoperative complications**

The creation of an intralamellar flap during the LASIK procedure increases the risk of intraoperative complications. The complications of LASIK are listed in table 2.<sup>94–116</sup> In general, difficulties associated with intra operative flaps arise because of issues related to micro keratome function—eg, malfunctions of the micro keratome assembly (loss of suction, poor blade oscillation, or interruption of keratome movement) or abnormally steep (button-hole formation) or flat (free-cap) patient cornea. The femtosecond laser has fewer problems in terms of creating irregular cuts, and managing irregular cuts created with the laser is less difficult. However, femtosecond laser has the potential to induce diffuse lamellar keratitis. Use of topical corticosteroids keeps the incidence and severity of diffuse lamellar keratitis to a manageable level. Depending on the severity and type of complication associated with flap creation, a surgeon can either ablate the cornea as planned or abort the procedure with the possibility of a future surface ablation.

For surface ablation, intraoperative complications are rare, and complications that do arise are usually not serious. If a LASEK epithelial sheet is torn or deranged, the procedure can revert to photorefractive keratectomy.

	FDA trials*	Non-FDA studies†
Epithelial defect <sup>94-98</sup>	0.50%	5.0-22.6%
Lamellar keratitis <sup>99-105</sup>	0.99%	0.2-3.2%
Haze <sup>95,106,107</sup>	0.57%	1.8-6.2%
Flap folds <sup>99,100</sup>	1.00%	0.2-1.1%
Thin flap <sup>93,100,108</sup>	0.42%	0.08-0.75%
Free-cap <sup>93,100,108</sup>	3.40%	0.08-1.00%
Irregular flap <sup>93,100</sup>	n/a	0.09-0.2%
Buttonholed flap <sup>93,100,108</sup>	n/a	0.13-0.56%
Incomplete flap <sup>93,100,108</sup>	n/a	0.23-0.75%
Dislodged flap <sup>93,100</sup>	0.22%	1.1-2.0%
Epithelial ingrowth <sup>99,100,109-111</sup>	0.14%	0.33-9.1%
Debris <sup>106,112,113</sup>	3.31%	1.9-100%
Infectious keratitis <sup>100,102,114,116</sup>	0.0%	0-0.2%
Ectasia <sup>115</sup>	0.0%	0.2%

n/a=not available. \*Include studies of wavefront-guided LASIK for myopia, LASIK for myopia, and LASIK for hyperopia. †Include complications reported in studies of 1000 people or more and in reports focusing on specific complications. Data are proportion of patients affected.

**Table 2: LASIK complications**

## Postoperative complications

Dry eye is the most frequent complication after refractive surgery, particularly in LASIK surgery, in which the corneal nerves are severed during the creation of the flap. Re-innervation in the subepithelial and anterior stroma is reduced by almost half, even 3 years after LASIK.<sup>117</sup> The condition is often transient and tends to improve over weeks to months. For symptomatic patients, topical treatments—such as artificial tears—are used and punctal occlusion, a procedure whereby a plug is inserted in the lacrimal punctum to reduce tear outflow from the ocular surface to the nose via the lacrimal drainage system, is done for more severe cases.

The LASIK flap re-adheres initially as a result of deturgescence of the cornea, but actual collagen deposition and wound healing is quite slow (this, in part, allows the cornea to remain free from scarring). As such, the flap might be displaced in the days, weeks, or even months after the procedure. The risk of flap slippage is greatest in the immediate postoperative period, and can be caused by eye rubbing or lid squeezing. After several months, a substantial shearing force with a vector tangential to the ocular surface is usually needed to displace a flap. Displaced flaps should be lifted and irrigated, and striae should be ironed out.

Epithelial ingrowth into the lamellar interface might occur if the flap edge is not well opposed. The ingrowth has the potential to reduce visual acuity and cause melting of the stroma as a result of enzymes secreted from the epithelial cells. If epithelial ingrowth occurs in the visual axis, or signs of stroma melting are noticed, irrigation and scraping of the flap interface should be done.

Postoperative scarring and haze is more common after surface ablation than LASIK, particularly in deeper ablations for higher degrees of myopia. Often a fine reticular haze can be seen at the slit lamp, but there are no visual consequences. Visually pronounced haze might occur in 1–2% of patients with high myopia. This haze can be treated by either intraoperative or postoperative application of mitomycin C or transforming growth factor- $\beta$ .<sup>118,119</sup>

Infection is uncommon since patients are kept on broad-spectrum antibiotics for a week after surgery. The relatively protected intralamellar space created during LASIK, however, does represent a potential haven for pathogens implanted at the time of surgery. Although many LASIK infections are caused by typical flora found on the ocular surface and lids, there is a greater incidence of keratitis caused by atypical organisms, such as mycobacterium and fungi.<sup>114</sup> Treatment can consist of topical antibiotics, but the flap might also need to be lifted and the corneal bed and flap irrigated with antibiotics. Infections after surface ablation are extremely uncommon and are generally well treated with broad-spectrum topical antibiotics after culture and removal of bandage contact lenses.

Diffuse lamellar keratitis is a clinical condition characterised by collections of white blood cells within the flap interface. The cause of this inflammation is not known, but it might be a result of immune reactions to antigens within the interface or because of trauma at the time of surgery. Diffuse lamellar keratitis is more common after the use of the femtosecond laser to create the flap. In slit-lamp examinations, diffuse lamellar keratitis is noted as a wide interface, extending or confining infiltration in the early stages after the operation. If this complication is resistant to intensive topical anti-inflammatory treatment, flap lifting and irrigation should be considered.<sup>103</sup>

Undercorrection is frequent with primary LASIK, and overcorrection is often noted after re-treatments (so-called enhancement). If the laser equipment's nomogram is not yet stabilised, especially at the beginning of use, those unexpected corrections will occur. To treat undercorrection, enhancement is needed.

Regression is defined as a return toward the original refractive error 3–6 months after refractive surgery. It was a frequent complication with the previous generation of refractive surgeries, such as radial keratotomy and photorefractive keratectomy, but seems to arise infrequently after myopic LASIK. However, regression is reported at much higher rates in hyperopic LASIK.

Halo and glare are frequent complications after refractive surgery, particularly if the patient has large pupils or if a small ablation diameter was used. These symptoms

are most noticeable at night or in dark places when the pupil dilates and more light rays enter the eye through the untreated peripheral cornea. Fortunately, despite a high rate of glare and halos immediately after surgery, these symptoms usually dissipate over time. Now that we can take wavefront measurements, higher-order wavefront aberrations are increasingly blamed. In the past, symptoms were treated with a topical miotic or tinted contact lens with an artificial pupil. Currently, attention has turned to wavefront-guided enhancement surgery as a means to solve severe glare and halos.

Corneal ectasia is a dreaded late-onset complication after laser refractive surgery. In this progressive condition, the cornea bows anteriorly, creating myopia and astigmatism. The cause of postsurgical ectasia is probably loss of biomechanical stability after excessive ablation of a normal cornea (leaving a residual corneal bed of less than 250  $\mu\text{m}$ ) or a reasonable ablation of a cornea, which is predisposed to corneal ectasia (most common forme fruste keratoconus). This complication's average onset is 12–14 months after LASIK.<sup>116</sup> According to the few available long-term reports, the incidence of post-LASIK ectasia is low.<sup>116</sup> An increasing awareness of the rate of ectasia and better ways to detect abnormal corneas before surgery should keep the rates low. Management of this severe complication might include hard gas-permeable contact lens wear, intracorneal ring segments, or keratoplasty. Soft contact lenses are not suitable because they cannot correct the irregular astigmatism.

## Conclusions and future directions

Laser refractive surgery is currently the mainstay of refractive surgery. Over the past decade, millions of individuals worldwide have reduced their dependence on spectacles and contact lenses because of the success of LASIK and surface ablation. Advances in these procedures continue to make the procedures not only more effective, but also safer. The excimer laser will continue to be a primary means of refractive surgery, even as phakic and accommodative intra-ocular lenses assume a larger share of refractive surgery.

The advances in laser refractive surgery will continue to be driven by the available technology. Improvements in laser design, eye-tracking, and laser algorithms have all been incremental improvements in laser refractive surgery. The advent of wavefront-guided surgery has been in many ways revolutionary. Future work will identify which components of the wavefront map are important in providing good vision. Even more importantly, the ability of laser algorithms to effectively treat these aberrations both for primary and secondary ablations will need to be improved.

An excimer laser can precisely do ablations, yet the refractive outcomes after surgery are not always so accurate. A better understanding of the role of wound healing in the final refractive outcomes is needed. We await biomodulators of wound healing that allow for more precise refractive outcomes.

The combination of multiple refractive surgery modalities is termed bioptics (this term was coined by Roberto Zaldivar) and can allow surgeons to avail themselves of the benefits of each procedure, and at the same time reduce to a minimum the known liabilities and limitations.<sup>120</sup> We will probably see laser refractive surgery increasingly combined with other modes of refractive surgery, such as phakic and accommodative intra-ocular lens. Refractive surgery will be seen not as a single procedure for a single problem, but rather as a set of refractive procedures to treat the overall vision requirements of a particular patient.

### **Conflict of interest statement**

*Dimitri T Azar is a consultant for Bausch and Lomb and Thermal Vision and has received travel support from Intralase, Alcon, Allergan/ AMO, Santen, and VISX. The other authors declare that they have no conflicts of interest.*

### **Funding sources and roles**

*This study was supported by a Grant EY10101 from the National Eye Institute (DTA), the Research to Prevent Blindness Lew Wasserman Fund (DTA), the Bausch and Lomb Japan/MEEI Research Fellowship Award (TS), the Japan Eye Bank Association (TS), and the MEEI/SERI Joint Clinical Research Center Fellowship (MIR). These funding sources provide research support for the authors, but have no affiliation with any company or product.*

## **References**

1. Waring GO, 3rd. Corneal structure and pathophysiology. In: Leibowitz H, ed. *Corneal disorders*. Philadelphia: WB Saunders, 1984: 3–25.
2. Schwiegerling J. Theoretical limits to visual performance. *Surv Ophthalmol* 2000; 45: 139–46.
3. Maeda N. Evaluation of optical quality of corneas using corneal topographers. *Cornea* 2002; 21 (7 suppl): S75–78.
4. Da Vinci L. *Codex of the eye*. Manuscript D, circa 1508.
5. Donders FC. *On the anomalies of accommodation and refraction of the eye*. London: The Hatton Press for the Sydenham Society, 1864.
6. Schiötz HA. Ein fall von hochgradigem hornhautastigmatismus nach staarextraction: besserung auf operativem Wege. *Archiv für Augenheilkunde* 1885; 15: 179–81.
7. Faber E. Operative behandelung von astigmatisme. *Nederl Tijdschr Geneesk* 1895; 31: 495–96.

8. Lucciola J. *Traitement chirurgical de l'astigmatisme*. *Arch Ophthalmol* 1886; 16: 630–38.
9. Lans L. *Experimentelle untersuchungen über entstehung von astigmatismus durch nicht perforirende corneawunden*. *Arch Ophthalmol* 1898; 45: 117–52.
10. Sato T. *Crosswise incisions of Descemet's membrane for the treatment of advanced keratoconus*. *Acta Soc Ophthalmol (Jpn)* 1942; 46: 469–70.
11. Durnev VV. *Characteristics of surgical correction of myopia after 16 and 32 peripheral anterior radial non-perforating incisions*. In: Fyodorov SN, ed. *Surgery of anomalies in ocular refraction*. Moscow: The Moscow Research Institute of Ocular Microsurgery, 1981: 33–35.
12. Barraquer JI. *Queratoplasia refractive*. *Estudios Inform* 1949; 2: 10–21.
13. Barraquer JI. *Keratomileusis for the correction of myopia*. *Arch Soc Am Oftal Optom* 1964; 5: 27–48.
14. Taboada J, Archibald CJ. *An extreme sensitivity in the corneal epithelium to far UV-ArF excimer laser pulses*. *Proceedings of the Aerospace Medical Association, 52 Annual Meeting 1981, Washington, DC*:8–9.
15. Trokel SL, Srinivasan R, Braren B. *Excimer laser surgery of the cornea*. *Am J Ophthalmol* 1983; 96: 710–15.
16. Seiler T, Wollensak J. *In vivo experiments with the excimer laser: technical parameters and healing processes*. *Ophthalmologica* 1986; 192: 65–70.
17. L'Esperance FA Jr, Taylor DM, Del Pero RA, et al. *Human excimer laser corneal surgery: preliminary report*. *Trans Am Ophthalmol Soc* 1988; 86: 208–75.
18. McDonald MB, Kaufman HE, Frantz JM, Shofner S, Salmeron B, Klyce SD. *Excimer laser ablation in a human eye*. *Arch Ophthalmol* 1989; 107: 641–42.
19. Barraquer JI. *Queratoplastia refractiva*. Bogota: Instituto Barraquer de America, 1970.
20. Ruiz L, Rowsey JJ. *In situ keratomileusis*. *Invest Ophthalmol Vis Sci* 1988; 29: S392.
21. Pallikaris IG, Papatzanaki ME, Stathi EZ, Frenschock O, Georgiadis A. *Laser in situ keratomileusis*. *Lasers Surg Med* 1990; 10: 463–68.
22. Buratto L, Ferrari M, Genisi C. *Myopic keratomileusis with the excimer laser: one-year follow up*. *Refract Corneal Surg* 1993; 9: 12–19.
23. Dhaliwal DK, Romanowski EG, Yates KA, Hu D, Goldstein M, Gordon YJ. *Experimental laser-assisted in situ keratomileusis induces the reactivation of latent herpes simplex virus*. *Am J Ophthalmol* 2001; 131: 506–07.
24. Kasparova EA, Kasparov AA. *Six-year experience with excimer laser surgery for primary keratoconus in Russia*. *J Refract Surg* 2003; 19 (suppl 2): S250–54.
25. Hammond MD, Madigan WP, Bower KS. *Refractive surgery in the United States Army, 2000–2003*. *Ophthalmology* 2005; 112: 184–90.
26. Wilson SE, Lin DT, Klyce SD, et al. *Topographic changes in contact lens-induced corneal warpage*. *Ophthalmology* 1990; 97: 734–44.
27. Klyce SD. *Night vision after LASIK: the pupil proclaims innocence*. *Ophthalmology* 2004; 111: 1–2.

28. Kezirian GM, Stonecipher KG. Comparison of the IntraLase femtosecond laser and mechanical keratomes for laser in situ keratomileusis. *J Cataract Refract Surg* 2004; 30: 804–11.
29. Jackson WB, Casson E, Hodge WG, Mintsoulis G, Agapitos PJ. Laser vision correction for low hyperopia: an 18-month assessment of safety and efficacy. *Ophthalmology* 1998; 105: 1727–38.
30. Williams DK. One-year results of laser vision correction for low to moderate hyperopia. *Ophthalmology* 2000; 107: 72–75.
31. Nagy ZZ, Munkacsy G, Popper M. Photorefractive keratectomy using the meditec MEL 70 G-scan laser for hyperopia and hyperopic astigmatism. *J Refract Surg* 2002; 18: 542–50.
32. Taneri S, Feit R, Azar DT. Safety, efficacy, and stability indices of LASEK correction in moderate myopia and astigmatism. *J Cataract Refract Surg* 2004; 30: 2130–37.
33. Pallikaris IG, Naoumidi, II, Kalyvianaki MI, Katsanevaki VJ. Epi-LASIK: comparative histological evaluation of mechanical and alcohol-assisted epithelial separation. *J Cataract Refract Surg* 2003; 29: 1496–501.
34. Laube T, Wissing S, Theiss C, Brockmann C, Steuhl KP, Meller D. Decreased keratocyte death after laser-assisted subepithelial keratectomy and photorefractive keratectomy in rabbits. *J Cataract Refract Surg* 2004; 30: 1998–2004.
35. Yeh PC, Azar DT. Wavefront-guided custom LASIK and LASEK: techniques and outcomes. In: Foster CS, Azar DT, Dohlman CH, eds. *Smolin and Thoft's the cornea*. Philadelphia: Lippincott Williams & Wilkins, 2004: 1257–68.
36. Yeh SI, Azar DT. The future of wavefront sensing and customization. *Ophthalmol Clin North Am* 2004; 17: 247–60.
37. US FDA. LADARVision® Excimer Laser System. P970043/S005. May 9, 2000. <http://www.fda.gov/cdrh/pdf/p970043s005.html> (accessed Nov 11, 2005).
38. US FDA. TECHNOLAS® 217A Excimer Laser System. P990027. Feb 23, 2000. <http://www.fda.gov/cdrh/pdf/p990027.html> (accessed Nov 11, 2005).
39. US FDA. TECHNOLAS® 217A Excimer Laser System. P990027/S2. May 17, 2002. <http://www.fda.gov/cdrh/pdf/p990027S002.html> (accessed Nov 11, 2005).
40. US FDA. Nidek EC-5000 Excimer Laser System. P970053/S002. April 14, 2000. <http://www.fda.gov/cdrh/pdf/p970053s002.html> (accessed Nov 11, 2005).
41. US FDA. VISX STAR S2 Excimer Laser System. P990010. Nov 19, 1999. <http://www.fda.gov/cdrh/pdf/p990010.html> (accessed Nov 11, 2005).
42. US FDA. WaveLight ALLEGRETTO WAVE™ Excimer Laser System. P020050. Oct 7, 2003. <http://www.fda.gov/cdrh/PDF2/p020050.html> (accessed Nov 11, 2005).
43. US FDA. LADARVision® Excimer Laser System. P970043/S10. May 9, 2000. <http://www.fda.gov/cdrh/pdf/p970043s010.html> (accessed Nov 11, 2005).
44. US FDA. Bausch & Lomb TECHNOLAS® 217z Zyoptix System for Personalized Vision Correction. P990027S006. Oct 10, 2003. <http://www.fda.gov/cdrh/pdf/p990027s006.html> (accessed Nov 11, 2005).



45. US FDA. STAR S4 Active Trak™ Excimer Laser System and WaveScan Wave Front® System. P930016/S016. May 5, 2003. <http://www.fda.gov/cdrh/pdf/p930016s016.html> (accessed Nov 11, 2005).
46. US FDA. TECHNOLAS® 217A Excimer Laser System. P990027/ S004. Feb 25, 2003. <http://www.fda.gov/cdrh/pdf/p990027S004.html> (accessed Nov 11, 2005).
47. US FDA. VISX STAR S2 and S3 Excimer Laser Systems. P930016/ S012. April 27, 2001. <http://www.fda.gov/cdrh/pdf/p930016s012.html> (accessed Nov 11, 2005).
48. US FDA. WaveLight ALLEGRETTO WAVE™ Excimer Laser System. P030008. Oct 10, 2003. <http://www.fda.gov/cdrh/PDF3/p030008.html> (accessed Nov 11, 2005).
49. US FDA. STAR S4™ Excimer Laser System with Variable Spot Scanning (VSS™) and WaveScan WaveFront® System. P930016/ S017. Dec 14, 2004. <http://www.fda.gov/cdrh/pdf/p930016s017.html> (accessed Nov 11, 2005).
50. Lee JB, Kim JS, Choe C, Seong GJ, Kim EK. Comparison of two procedures: photorefractive keratectomy versus laser in situ keratomileusis for low to moderate myopia. *Jpn J Ophthalmol* 2001; 45: 487–91.
51. el Danasoury MA, el Maghraby A, Klyce SD, Mehrez K. Comparison of photorefractive keratectomy with excimer laser in situ keratomileusis in correcting low myopia (from -2.00 to -5.50 diopters): a randomized study. *Ophthalmology* 1999; 106: 411–21.
52. El-Maghraby A, Salah T, Waring GO 3rd, Klyce S, Ibrahim O. Randomized bilateral comparison of excimer laser in situ keratomileusis and photorefractive keratectomy for 2.50 to 8.00 diopters of myopia. *Ophthalmology* 1999; 106: 447–57.
53. Kaya V, Oncel B, Sivrikaya H, Yilmaz OF. Prospective, paired comparison of laser in situ keratomileusis and laser epithelial keratomileusis for myopia less than -6.00 diopters. *J Refract Surg* 2004; 20: 223–28.
54. Lin JM, Tsai YY. Laser in situ keratomileusis for different degrees of myopia. *Acta Ophthalmol Scand* 2005; 83: 40–45.
55. Knorz MC, Neuhann T. Treatment of myopia and myopic astigmatism by customized laser in situ keratomileusis based on corneal topography. *Ophthalmology* 2000; 107: 2072–76.
56. Hersh PS, Brint SF, Maloney RK, et al. Photorefractive keratectomy versus laser in situ keratomileusis for moderate to high myopia: a randomized prospective study. *Ophthalmology* 1998; 105: 1512–23.
57. Steinert RF, Hersh PS, Summit technology PRK-LASIK study group. Spherical and aspherical photorefractive keratectomy and laser in-situ keratomileusis for moderate to high myopia: two prospective, randomized clinical trials.. *Trans Am Ophthalmol Soc* 1998; 96: 197–227.
58. Malecaze FJ, Hulin H, Bierer P, et al. A randomized paired eye comparison of two techniques for treating moderately high myopia: LASIK and Artisan phakic lens. *Ophthalmology* 2002; 109: 1622–30.

59. El Danasoury MA, El Maghraby A, Gamali TO. Comparison of irisfixed Artisan lens implantation with excimer laser in situ keratomileusis in correcting myopia between  $-9.00$  and  $-19.50$  diopters: a randomized study. *Ophthalmology* 2002; 109: 955–64.
60. Kim TI, Yang SJ, Tchah H. Bilateral comparison of wavefrontguided versus conventional laser in situ keratomileusis with Bausch and Lomb Zyoptix. *J Refract Surg* 2004; 20: 432–38.
61. Sekundo W, Bonicke K, Mattausch P, Wiegand W. Six-year followup of laser in situ keratomileusis for moderate and extreme myopia using a first-generation excimer laser and microkeratome. *J Cataract Refract Surg* 2003; 29: 1152–58.
62. Esquenazi S. Five-year follow-up of laser in situ keratomileusis for hyperopia using the Technolas Keracor 117C excimer laser. *J Refract Surg* 2004; 20: 356–63.
63. Varley GA, Huang D, Rapuano CJ, et al. LASIK for hyperopia, hyperopic astigmatism, and mixed astigmatism: a report by the American Academy of Ophthalmology. *Ophthalmology* 2004; 111: 1604–17.
64. Salz JJ, Stevens CA. LASIK correction of spherical hyperopia, hyperopic astigmatism, and mixed astigmatism with the LADARVision excimer laser system. *Ophthalmology* 2002; 109: 1647–58.
65. Rashad KM. Laser in situ keratomileusis for the correction of hyperopia from  $+1.25$  to  $+5.00$  diopters with the Technolas Keracor 117C laser. *J Refract Surg* 2001; 17: 113–22.
66. Cobo-Soriano R, Llovet F, Gonzalez-Lopez F, Domingo B, Gomez- Sanz F, Bavierra J. Factors that influence outcomes of hyperopic laser in situ keratomileusis. *J Cataract Refract Surg* 2002; 28: 1530–38.
67. Albarrán-Diego C, Muñoz G, Montés-Micó R, Alió JL. Bitoric laser in situ keratomileusis for astigmatism. *J Cataract Refract Surg* 2004; 30: 1471–78.
68. Handzel A, Kenikstul N, Handzel T. Laser in situ keratomileusis for astigmatism greater than  $-3.50$  D with the Nidek EC-5000 excimer laser. *J Refract Surg* 2003; 19 (2 suppl): S241–42.
69. Alió JL, Javaloy J, Osman AA, Galvis V, Tello A, Haroun HE. Laser in situ keratomileusis to correct post-keratoplasty astigmatism; 1-step versus 2-step procedure. *J Cataract Refract Surg* 2004; 30: 2303–10.
70. Norouzi H, Rahmati-Kamel M. Laser in situ keratomileusis for correction of induced astigmatism from cataract surgery. *J Refract Surg* 2003; 19: 416–24.
71. Visx Technology. News and events. May 31, 2005. [http://www.visx.com/professionals/news\\_events/](http://www.visx.com/professionals/news_events/) (accessed Nov 11, 2005).
72. Telandro A. Pseudo-accommodative cornea: a new concept for correction of presbyopia. *J Refract Surg* 2004; 20 (suppl 5): S714–17.
73. Bauerberg JM. Centered vs. inferior off-center ablation to correct hyperopia and presbyopia. *J Refract Surg* 1999; 15: 66–69.

74. Cantu R, Rosales MA, Tepichin E, Curioca A, Montes V, Bonilla J. Advanced surface ablation for presbyopia using the Nidek EC-5000 laser. *J Refract Surg* 2004; 20 (5 suppl): S711–13.
75. Miranda D, Krueger RR. Monovision laser in situ keratomileusis for pre-presbyopic and presbyopic patients. *J Refract Surg* 2004; 20: 325–28.
76. Jain S, Ou R, Azar DT. Monovision outcomes in presbyopic individuals after refractive surgery. *Ophthalmology* 2001; 108: 1430–33.
77. US FDA. ALCON Apex & Apex Plus. P930034. <http://www.fda.gov/cdrh/pdf/p930034.pdf> (accessed Oct 25, 1995).
78. Hashemi H, Fotouhi A, Foudazi H, Sadeghi N, Payvar S. Prospective, randomized, paired comparison of laser epithelial keratomileusis and photorefractive keratectomy for myopia less than  $-6.50$  diopters. *J Refract Surg* 2004; 20: 217–22.
79. Lee JB, Seong GJ, Lee JH, Seo KY, Lee YG, Kim EK. Comparison of laser epithelial keratomileusis and photorefractive keratectomy for low to moderate myopia. *J Cataract Refract Surg* 2001; 27: 565–70.
80. Pop M, Payette Y. Photorefractive keratectomy versus laser in situ keratomileusis: a control-matched study. *Ophthalmology* 2000; 107: 251–57.
81. Shah S, Chatterjee A, Smith RJ. Predictability and outcomes of photoastigmatic keratectomy using the Nidek EC-5000 excimer laser. *J Cataract Refract Surg* 2002; 28: 682–88.
82. MacRae SM, Peterson JS, Koch DD, Rich LF, Durrie DS. Photoastigmatic refractive keratectomy in myopes. Nidek US Investigators Group. *J Refract Surg* 2000; 16: 122–32.
83. Kapadia MS, Wilson SE. One-year results of PRK in low and moderate myopia: fewer than 0.5% of eyes lose two or more lines of vision. *Cornea* 2000; 19: 180–84.
84. Tole DM, McCarty DJ, Couper T, Taylor HR. Comparison of laser in situ keratomileusis and photorefractive keratectomy for the correction of myopia of  $-6.00$  diopters or less. Melbourne Excimer Laser Group. *J Refract Surg* 2001; 17: 46–54.
85. Kim JK, Kim SS, Lee HK, et al. Laser in situ keratomileusis versus laser-assisted subepithelial keratectomy for the correction of high myopia. *J Cataract Refract Surg* 2004; 30: 1405–11.
86. Partal AE, Rojas MC, Manche EE. Analysis of the efficacy, predictability, and safety of LASEK for myopia and myopic astigmatism using the Technolas 217 excimer laser. *J Cataract Refract Surg* 2004; 30: 2138–44.
87. Lee HK, Lee KS, Kim JK, Kim HC, Seo KR, Kim EK. Epithelial healing and clinical outcomes in excimer laser photorefractive surgery following three epithelial removal techniques: mechanical, alcohol, and excimer laser. *Am J Ophthalmol* 2005; 139: 56–63.
88. Claringbold TV, 2nd. Laser-assisted subepithelial keratectomy for the correction of myopia. *J Cataract Refract Surg* 2002; 28: 18–22.


89. Aufrata R, Rehurek J. Laser-assisted subepithelial keratectomy and photorefractive keratectomy for the correction of hyperopia: results of a 2-year follow-up. *J Cataract Refract Surg* 2003; 29: 2105–14.
90. Nagy ZZ, Krueger RR, Suveges I. Photorefractive keratectomy for astigmatism with the Meditec MEL 60 laser. *J Refract Surg* 2001; 17: 441–53
91. Nagy ZZ, Palagyi-Deak I, Kovacs A, Kelemen E, Forster W. First results with wavefront-guided photorefractive keratectomy for hyperopia. *J Refract Surg* 2002; 18: S620–23.
92. Netto MV, Mohan RR, Ambrosio R Jr, Hutcheon AE, Zieske JD, Wilson SE. Wound healing in the cornea: a review of refractive surgery complications and new prospects for therapy. *Cornea* 2005; 24: 509–22.
93. Melki SA, Azar DT. LASIK complications: etiology, management, and prevention. *Surv Ophthalmol* 2001; 46: 95–116.
94. Davidorf JM, Zaldivar R, Oscherow S. Results and complications of laser in situ keratomileusis by experienced surgeons. *J Refract Surg* 1998; 14: 114–22.
95. Shah MN, Misra M, Wilhelmus KR, Koch DD. Diffuse lamellar keratitis associated with epithelial defects after laser in situ keratomileusis. *J Cataract Refract Surg* 2000; 26: 1312–18.
96. Kohnen T, Terzi E, Mirshahi A, Bühren J. Intraindividual comparison of epithelial defects during laser in situ keratomileusis using standard and zero-compression Hansatome microkeratome heads. *J Cataract Refract Surg* 2004; 30: 123–26.
97. Kenyon KR, Paz H, Greiner JV, Gipson IK. Corneal epithelial adhesion abnormalities associated with LASIK. *Ophthalmology* 2004; 111: 11–17.
98. Tekwani NH, Huang D. Risk factors for intraoperative epithelial defect in laser in situ keratomileusis. *Am J Ophthalmol* 2002; 134: 311–16.
99. Lin RT, Maloney RK. Flap complications associated with lamellar refractive surgery. *Am J Ophthalmol* 1999; 127: 129–36.
100. Stulting RD, Carr JD, Thompson KP, Waring GO 3rd, Wiley WM, Walker JG. Complications of laser in situ keratomileusis for the correction of myopia. *Ophthalmology* 1999; 106: 13–20.
101. Noda-Tsuruya T, Toda I, Asano-Kato N, Hori-Komai Y, Fukumoto T, Tsubota K. Risk factors for development of diffuse lamellar keratitis after laser in situ keratomileusis. *J Refract Surg* 2004; 20: 72–75.
102. Thammano P, Rana AN, Talamo JH. Diffuse lamellar keratitis after laser in situ keratomileusis with the Moria LSK-One and Carriazo-Barraquer microkeratomes. *J Cataract Refract Surg* 2003; 29: 1962–68.
103. Hoffman RS, Fine IH, Packer M. Incidence and outcomes of LASIK with diffuse lamellar keratitis treated with topical and oral corticosteroids. *J Cataract Refract Surg* 2003; 29: 451–56.
104. Johnson JD, Harissi-Dagher M, Pineda R, Yoo S, Azar DT. Diffuse lamellar keratitis: incidence, associations, outcomes, and a new classification system. *J Cataract Refract Surg* 2001; 27: 1560–66.

105. Stulting RD, Randleman JB, Couser JM, Thompson KP. The epidemiology of diffuse lamellar keratitis. *Cornea* 2004; 23: 680–88.
106. Lindstrom RL, Hardten DR, Houtman DM, et al. Six-month results of hyperopic and astigmatic LASIK in eyes with primary and secondary hyperopia. *Trans Am Ophthalmol Soc* 1999; 97: 241–60.
107. Price FW Jr, Willes L, Price M, Lyng A, Ries J. A prospective, randomized comparison of the use versus non-use of topical corticosteroids after laser in situ keratomileusis. *Ophthalmology* 2001; 108: 1236–45.
108. Nakano K, Nakano E, Oliveira M, Portellinha W, Alvarenga L. Intraoperative microkeratome complications in 47,094 laser in situ keratomileusis surgeries. *J Refract Surg* 2004; 20 (5 suppl): S723–26.
109. Asano-Kato N, Toda I, Hori-Komai Y, Takano Y, Tsubota K. Epithelial ingrowth after laser in situ keratomileusis: clinical features and possible mechanisms. *Am J Ophthalmol* 2002; 134: 801–07.
110. Wang MY, Maloney RK. Epithelial ingrowth after laser in situ keratomileusis. *Am J Ophthalmol* 2000; 129: 746–51.
111. Walker MB, Wilson SE. Incidence and prevention of epithelial growth within the interface after laser in situ keratomileusis. *Cornea* 2000; 19: 170–73.
112. Yildirim R, Devranoglu K, Ozdamar A, Aras C, Ozkiris A, Ozkan S. Flap complications in our learning curve of laser in situ keratomileusis using the Hansatome microkeratome. *Eur J Ophthalmol* 2001; 11: 328–32.
113. Vesaluoma M, Perez-Santonja J, Petroll WM, Linna T, Alio J, Tervo T. Corneal stromal changes induced by myopic LASIK. *Invest Ophthalmol Vis Sci* 2000; 41: 369–76.
114. Chang MA, Jain S, Azar DT. Infections following laser in situ keratomileusis: an integration of the published literature. *Surv Ophthalmol* 2004; 49: 269–80.
115. Gimbel HV, van Westenbrugge JA, Penno EE, Ferensowicz M, Feinerman GA, Chen R. Simultaneous bilateral laser in situ keratomileusis: safety and efficacy. *Ophthalmology* 1999; 106: 1461–68.
116. Rad AS, Jabbarvand M, Saifi N. Progressive keratectasia after laser in situ keratomileusis. *J Refract Surg* 2004; 20(5 Suppl): S718–22.
117. Calvillo MP, McLaren JW, Hodge DO, Bourne WM. Corneal reinnervation after LASIK: prospective 3-year longitudinal study. *Invest Ophthalmol Vis Sci* 2004; 45: 3991–96.
118. Azar DT, Jain S. Topical MMC for subepithelial fibrosis after refractive corneal surgery. *Ophthalmology* 2001; 108: 239–40.
119. Thom SB, Myers JS, Rapuano CJ, Eagle RC Jr, Siepser SB, Gomes JA. Effect of topical anti-transforming growth factor- $\beta$  on corneal stromal haze after photorefractive keratectomy in rabbits. *J Cataract Refract Surg* 1997; 23: 1324–30.
120. Zaldivar R, Davidorf JM, Oscherow S, Ricur G, Piezzi V. Combined posterior chamber phakic intraocular lens and laser in situ keratomileusis: bioptics for extreme myopia. *J Refract Surg* 1999; 15: 299–308.

# Quality of vision after refractive surgery

| Dimitri Azar, United States |

**Quality of Vision after Refractive Surgery**



**Dimitri T. Azar, MD**  
 B.A. Field Endowed Chair,  
 Professor and Head,  
 Department of Ophthalmology  
 and Visual Sciences,  
 Illinois Eye and Ear Infirmary,  
 University of Illinois at Chicago

**Non-Custom LASIK**

1. Measurement of spherocylindrical error
2. Flap dissection with microkeratome &
3. photoablation with excimer laser

Number of LASIK Procedures in US

1998	430,000
1999	800,000
2000-2007 (projected)	1.5-2 mil./yr

Complication rate 0.5% - 2%

Mechanical complications relate to the flap  
 Optical complications relate to decentration, optical zone size, positive asphericity, and uncorrected HOA

VISX Laser Technology Advancements

Iris Registration  
 Multifocal Ablations

B&L Laser Technology Advancements

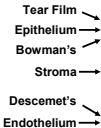
Multifocal Ablations

Allegretto Laser Technology Advancements

Mixed Astigmatism Approval  
 Instantaneous Pachymetric monitoring

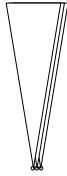Femtosecond Optical Delivery System

- Glass Lens applanates cornea to flatten eye & maintain precise distance from laser head to focal point



**Mechanical complications may be reduced with newer technologies**

- Laser is set to desired depth
  - Defined distance from bottom of glass applanation surface
- Pulses delivered in a prescribed pattern creating a horizontal or vertical cleavage plane in the cornea

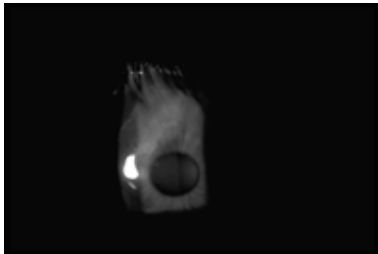


**Optical complications may be reduced with custom LASIK and newer technologies of laser delivery**

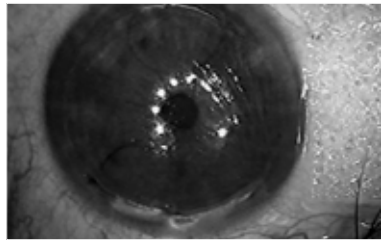
**LASIK Limitations**

- Potential Flap-related Complications
- Custom corneal limitations
- Ectasia

**Epithelial Cysts**



**Striae**

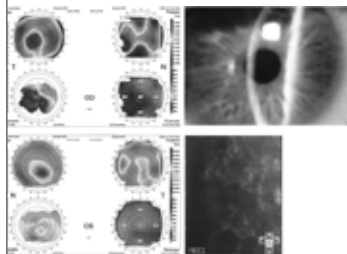


**Corneal Ectasia in Myopia**

- Preexisting KC
- Deep flap
- High myopia
- Deep laser ablation

(Ectasia is more likely to occur after LASIK)

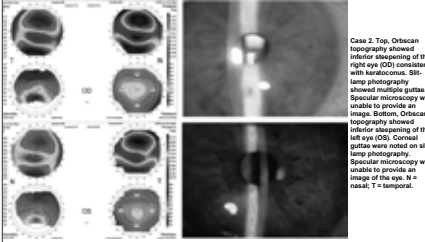
**Potential Complications in Patients with Coexistent Keratoconus and Fuchs' Dystrophy**



Case 1. Top. Orbscan topography showed advanced inferior steepening consistent with keratoconus. Middle. Cornea. Slit lamp photography showed keratoconus. Bottom. Specular microscopy was unable to provide an image of the eye due to corneal edema. Bottom. Orbscan topography showed inferior steepening consistent with keratoconus. Specular microscopy of the left eye (OS) revealed multiple guttae, with inability to perform cell counts. R = nasal; T = temporal.

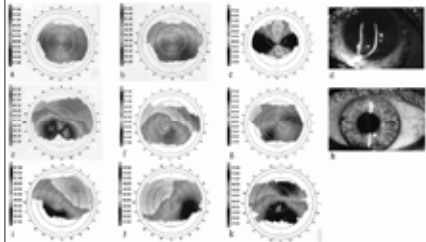
Arkunias U, Azar DT. Ophthalmology. 2006 Dec;113(12):2187-97.

### Potential Complications in Patients with Coexistent Keratoconus and Fuchs' Endothelial Dystrophy



Jurkunas JJ, Azar DT. Ophthalmology. 2006;Dec;113(12):2187-87.

### Ectatic Disorders Associated with a Claw-Shaped Pattern on Corneal Topography



Bo BW, Jurkunas UV, Harissi-Dagher M, Poothullil AM, Toboigy FM, Azar DT. Am J Ophthalmol. 2007 Jul;144(1):154-156.

### Surface Ablation?

- Potential Flap-related Complications
- Custom corneal limitations
- Ectasia

### Surface Ablation, Combined with MMC, May Overcome Several Limitations of Phakic IOLs

- Shallow AC
- Low initial endothelial cell counts
- Progressive endothelial cell loss
- Cataract formation
- Serious Intraoperative/Postoperative Complications

### Control-Matched Comparison of LASEK and LASIK

Retrospective, nonrandomized, control-matched study  
The charts of 2257 eyes that underwent LASEK or LASIK treatment were reviewed.

Inclusion criteria: patients who were 21 years of age or older having between -0.75 and -6.00 diopters (D) of myopia with up to -2.25 D of astigmatism.

One hundred twenty-two LASEK-treated eyes were matched with 122 LASIK-treated eyes having preoperative spheres, cylinders, and SE within ±0.50 D.

Both groups had similar preoperative best spectacle-corrected visual acuity (BSCVA), laser platform, and follow-up durations.

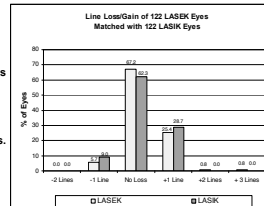
Toboigy FM, Ghanem RC, Sayegh RR, Hallak JA, Azar DT. Am J Ophthalmol. 2006; 142(6): 901-8

### Control-Matched Comparison of LASEK and LASIK

Postoperative results:  
Mean SE was -0.15 ± 0.40 D for LASEK and -0.37 ± 0.45 D for LASIK

Mean logMAR of BSCVA was -0.03 ± 0.06 (20/19) for LASEK and -0.02 ± 0.05 (20/19) for LASIK.

No eye lost 2 or more lines of BSCVA in both groups.



Toboigy FM, Ghanem RC, Sayegh RR, Hallak JA, Azar DT. Am J Ophthalmol. 2006; 142(6): 901-8

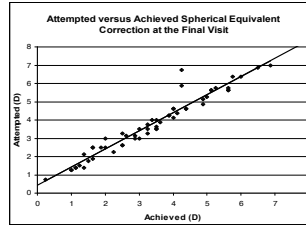


## Control-Matched Comparison of LASEK and LASIK for Low to Moderate Myopia

### Conclusions:

- Although there were some differences in the visual and refractive results favoring LASEK, they were not clinically significant.
- Both procedures seemed safe, effective, and predictable for the treatment of low and moderate myopia.
- Nomogram adjustment may be necessary for LASIK surgeons adopting surface ablation.

Epi-LASIK Attempted versus achieved spherical equivalent correction



## Surface Ablation

### ADVANTAGES:

- Surface ablation is a viable alternative to LASIK especially in young patients with thin pachymetry, steep K, and/or corneal irregularities.
- Microkeratome and flap- related complications are avoided.
- Surface ablation is a reasonable alternative to phakic IOLs in patients with low endothelial cell counts, shallow AC, early lens opacities, and/or high astigmatism.

### LIMITATIONS:

- The long-term risks of prophylactic MMC are unknown.

## LASIK in the Presbyopic Age Group: Safety, Efficacy and Predictability in 40-69 Year Old Patients

### Conclusions:

- Despite a trend towards worse final BSCVA and higher retreatment rates in older patients, a greater risk of visual loss after LASIK was not observed with increasing age.
- LASIK for myopia and hyperopia has reasonable safety, efficacy and predictability profiles in the presbyopic age group.

Ghanem RC, de la Cruz J, Tobaligy FM, Ang LP, Azar DT. Ophthalmology. 2007 Jul;114(7):1303-10

AFFERENT ARM



Corneal Topography/  
Wavefront Analyzer

+

EFFERENT ARM



Scanning Laser

=

**Custom Ablation**




## What are the Optical Limits to Corneal Refractive Surgery?



## Comparison of Outcomes of Custom and Non-custom LASIK

- FDA trials of LVC
- Subgroups: 0 to -2D, -2 to -4D, -4 to -7D, 0 to +2D, +2 to +4, & +4 to +6D
- Pooled data of approved lasers (3 custom and 5 non-custom) rather than head-to-head comparisons of individual lasers
- Literature Search (past 10 years); data pooled
- Outcomes: %  $\geq$  20/20; %  $\geq$  20/40; %  $\pm$  0.50D; %  $\pm$  1D; % loss of  $\geq$  2 Snellen lines

Sakimoto T, Rosenblatt MI, Azar DT -- Lancet 4/2006



## Limitations in Wavefront Analysis: Measurement Steps

- Wavefronts reconstructed/analyzed
  - higher order Zernike polynomial or Fourier representation of wavefront generated.
  - Effective clinical prescription generated and compared to phoropter.
  - Repeat measurements compared for consistency.

## Scanning and Tracking Laser Technology Limitations

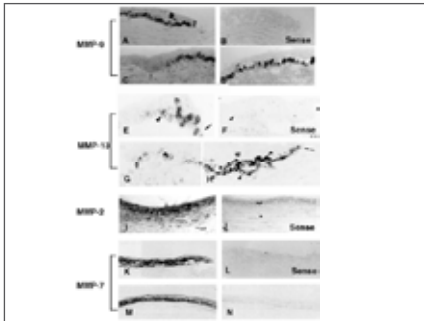
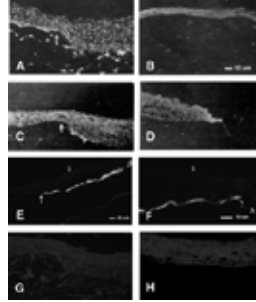
- Avoidance of Eye drift during surgery
- Tracking of cornea in 3 dimensions: x, y, and rotational
- Differentiation of rotational vs. translational movement (eye mvt vs head mvt)



## Additional Limitations of Wavefront-guided Excimer Laser Ablations

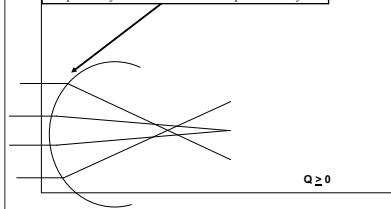
The refractive outcomes may be altered by surgically-induced HOA:

- Wound healing
- Biomechanical changes after surgery (collagen relaxation, ectasia)



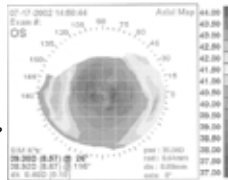
## Corneal Asphericity

Spherical surface (Shape factor:  $Q = 0$ );  
or Oblate surface (Shape factor:  $Q > 0$ ):  
Peripheral rays are bent more than the para-axial rays

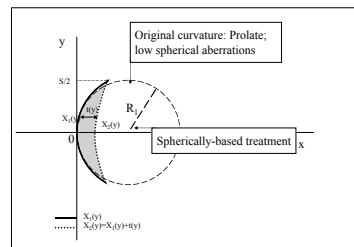


## Myopic LASIK:

Central area flatter than  
Peripheral untreated zone  
Is the treatment zone oblate?

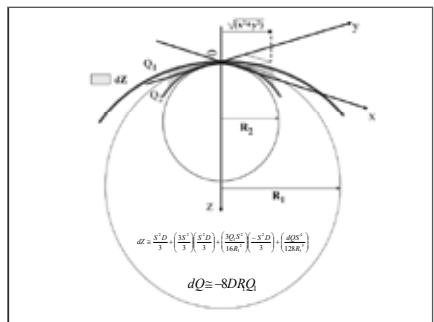
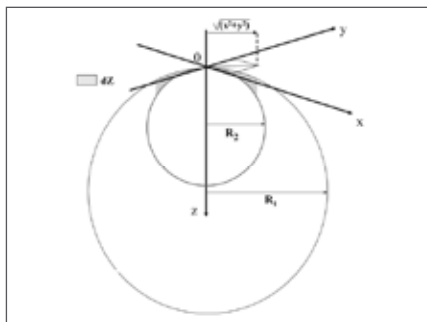
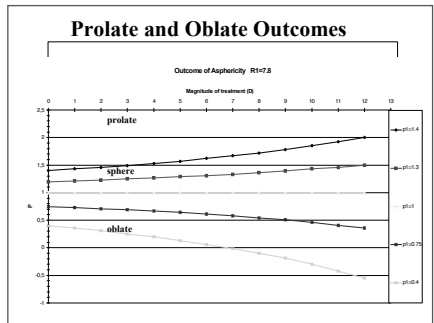
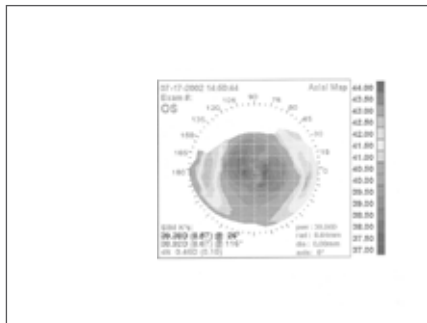
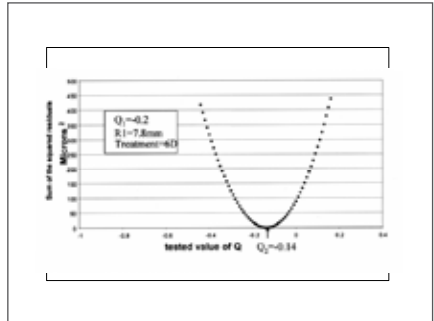
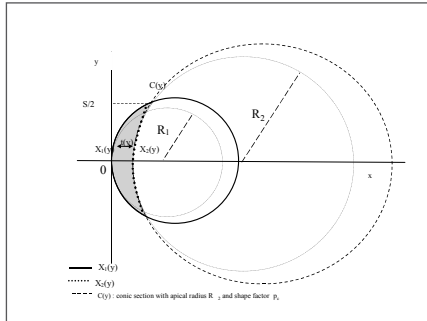


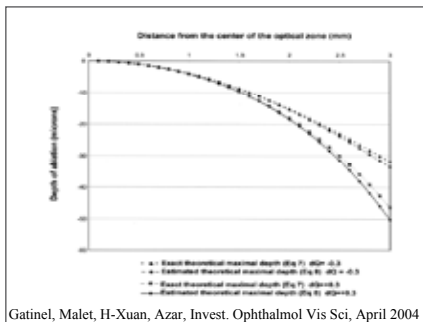

## Preoperative Corneal Asphericity



Gatinel and Azar

Invest. Ophthalmol Vis Sci





Gatinel, Malet, H-Xuan, Azar, Invest. Ophthalmol Vis Sci, April 2004

## CONCLUSIONS

- Recent improvements in LVC include improved technology, patient selection, surface ablation (Epi-LASIK), monovision, and customized wavefront-guided LASIK.
- Despite improved outcomes of custom LVC, biomechanical changes and WH interfere with the ability to eliminate optical aberrations
- Other limitations include inability to measure and render all HOA at all wavelengths, inability to predict the surgically-induced aberrations, and inability to perfectly position Rx on the corneal plane.

Thank you for your attention

Dimitri T. AZAR, M.D.

*Dimitri T. Azar, MD  
B.A. Field Endowed Chair,  
Professor and Head,  
Department of Ophthalmology and Visual Sciences,  
Illinois Eye and Ear Infirmary,  
University of Illinois, Chicago  
dazar@uic.edu*





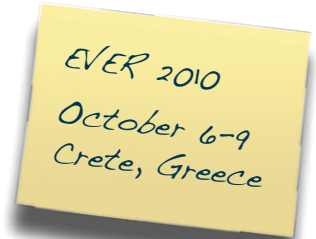Sept 30 - Oct 3, 2009 • Portoroz, Slovenia



## European Association for Vision and Eye Research

### JOIN EVER in Portoroz - Slovenia

- Largest annual European eye research meeting
- Keynote lectures
- Special interest symposia
- Free paper sessions and posters
- Workshops and courses
- Lunchtime Commercial Interest Symposia
- New attractive location every three years



### BECOME an active member

#### Your benefits :

- Reduced fee for annual meeting
- Organizing Special Interest Symposia (SIS) during the annual meeting
- Voting rights for the election of Board Members
- Free access to Acta Ophthalmologica
- Travel grants
- Quarterly E-Newsletter

**Registration deadline: September 1, 2009**

#### EBO Review Courses

- From clinical analysis to final diagnosis: semiology is the key
- Ophthalmic oncology

**21 CME CREDITS**

**[www.ever.be](http://www.ever.be)**

EVER 2009 hosts:

ARVO - CONCORDIA - EBO - EURETINA - EVI - FRO - ISCEV - OOG - SOIE

EVER 2009





EUROPEAN PROFESSORS OF OPHTHALMOLOGY

# EUPO COURSE 2010

## RETINA



October 1-3, 2010 - Athens, Greece

[www.euppo.eu](http://www.euppo.eu)

## CORNEA, CONJUNCTIVA and REFRACTIVE SURGERY

### Programme

Friday, June 12, 2009

→ *Room B*

09:25 Introduction

09:30 **First morning session:** Morphology, anomalies and dystrophies

11:00 *Break*

11:30 **Second morning session:** Examination and inflammation

13:00 *Lunch*

14:30 **First afternoon session:** Keratoplasty and keratoprosthesis

16:00 *Break*

16:30 **Second afternoon session:** Allergy, Eye-lids, Keratoconus

**18:15 EUPO Party**

Saturday, June 13, 2009

→ *Room Elicium 2*

08:15 **Morning session:** Bacterial, viral and fungal keratitis

09:45 *Break*

**10:15 Opening Ceremony of the SOE Congress**

11:15 *Break*

**13:15 Keynote lecture of European Congress of Ophthalmology**

→ *Auditorium*

14:30 **First afternoon session:** Inflammation, Tumors, Dry Eye

16:00 *Break and Exhibition Visit*

16:30 **Second afternoon session:** Refractive Surgery

18:00 End of session