

European University Professors of Ophthalmology

EUPO 2010

October 1-3, 2010 • Athens, Greece

RETINA

Course book




www.eupo.eu

EUPO 2010

October 1-3, 2010 • Athens, Greece

Retina • Course book

Course director: Prof. Michael Moschos



Dear colleagues,

It is a great pleasure for us to welcome you to the beautiful and historical city of Athens, host of the 2010 Course of the European Professors of Ophthalmology (EUPO). The course is devoted to the Retina and many distinguished speakers will give an overview of theoretical and practical knowledge on diagnosis and treatment of retinal diseases.

The invited lecturers come from different countries of Europe and it is a honour for us to have all them in Athens. We think that the interesting scientific program, as well as the outstanding EUPO party, promise the success of the course.

For once more we welcome you and we would like to wish you a very pleasant stay in Athens, a city which is characterized by its beauty and hospitality,

Prof. Michael Moschos
Local organizer

The sequence of the EUPO courses

| | | |
|------|-------------------------|--|
| 2010 | Athens | Retina |
| 2009 | Amsterdam (SOE) | Cornea, Conjunctiva and Refractive surgery |
| 2008 | Geneva | Neuro-ophthalmology and strabismus |
| 2007 | Vienna (SOE) | Glaucoma and uveitis |
| 2006 | Ghent | Retina |
| 2005 | Berlin (SOE) | Cornea |
| 2004 | Nijmegen | Neuro-ophthalmology and strabismus |
| 2003 | Madrid (SOE) | Glaucoma and uveitis |
| 2002 | Erlangen | Retina |
| 2001 | Istanbul (SOE) | Cornea |
| 2000 | Leuven | Neuro-ophthalmology and strabismus |
| 1999 | Stockholm (SOE) | Glaucoma and uveitis |
| 1998 | Amsterdam (ICO) | Chorioretina |
| 1997 | Budapest (SOE) | Cornea, conjunctiva, lids, orbit |
| 1996 | Athens | Neuro-ophthalmology and strabismus |
| 1995 | Milano (SOE) | Uveitis, lens, glaucoma |
| 1994 | Montpellier | Retina |
| 1993 | Santiago de Compostella | The external eye |
| 1992 | Brussels (SOE) | Neuro-ophthalmology and strabismus |
| 1991 | Torino | Uveitis, lens, glaucoma |
| 1990 | Bonn | Chorioretina |
| 1989 | Leuven | The external eye and orbit |
| 1988 | Nijmegen | |

European University Professors of Ophthalmology

EUPO Board

Gabriel van Rij
President



Werner Spileers
Secretary General
Treasurer



EUPO Office: www.eupo.eu

available on www.eupo.eu



2006
Retina

2007
Uveitis

2008
Neuro-Ophthalmology
and Strabismus

2009
Cornea,
Conjunctiva and
Refractive surgery



Congress venue



Eugenides Foundation
387, Sygrou Avenue P. Faliro



Congress Secretariat:



AKTINA CITY Congress & Events
PROFESSIONAL CONGRESS ORGANIZERS - Member of IAPCO
9 Xenofontos Street, GR-105 57, Athens, Greece
Telephone: +30 210 32 32433, Fax: +30 210 3232338

PROGRAMME

FRIDAY, October 1, 2010

15:00-19:00 **Registration**

19:00-20:00 **Welcome Cocktail**

SATURDAY, October 2, 2010

09:00 **Welcome address by Prof. Constatinos Stefanadis, President of the Medical School of Athens University**

09:05 **Introduction by Prof. Gabriel van Rij, President EUPO**

First morning session

| Moderators: Gabriel van Rij - Luc Missotten | Course | Page |
|--|--------|------|
| 09:15 The retina Luc Missotten, Belgium | 1 | 11 |
| 09:35 Retina blood flow Constantin Pournaras, Switzerland | 2 | 13 |
| 09:55 Fluorescein angiography, clinical interpretation Gisèle Soubrane, France | 3 | 19 |
| 10:15 OCT, Clinical interpretation Dimitrios Brouzas, Greece | 4 | 21 |
| 10:35 Laser treatment in retinal diseases Stavros Dimitrakos, Greece | 5 | 29 |
| 10:55 Coffee break | | |

Second morning session

| Moderators: Alma Patrizia Tormene - Michael Moschos | Course | Page |
|---|--------|------|
| 11:30 Principles of clinical electrophysiology Alma Patrizia Tormene, Italy | 6 | 35 |
| 11:50 Clinical value of mfERG in macular diseases Marilita Moschos, Greece | 7 | 45 |
| 12:10 Retinal Ischemia Marina Zueva, Russia | 8 | 49 |
| 12:30 The role of VEGF in retinal disease Jose Cunha-Vaz, Portugal | 9 | 57 |
| 12:50 Central serous chorioretinopathy Vasilios Kozobolis, Greece | 10 | 63 |
| 13:10 Lunch | | |

SATURDAY, October 2, 2010

First afternoon session

| Moderators: Ursula Schmidt-Erfurth - Francesco Bandello | Course | Page |
|---|--------|------|
| 14:30 Diabetic macular edema <i>Ursula Schmidt-Erfurth, Austria</i> | 11 | 69 |
| 14:50 Proliferative diabetic retinopathy Ioannis Ladas, Greece | 12 | 71 |
| 15:10 Pathophysiology of CRVO Periklis Brazitikos, Greece | 13 | 77 |
| 15:30 Current treatment of CRVO Francesco Bandello, Italy | 14 | 89 |
| 15:50 Retinopathy of prematurity Georgia Chrousou, Greece | 15 | 91 |
| 16:10 Coffee break | | |

Second afternoon session

| Moderators: Isabelle Ingster Moati - Murat Oncel | Course | Page |
|---|--------|------|
| 16:40 Macular edema Wojciech Lubinski, Poland | 16 | 97 |
| 17:00 Macular hole Murat Oncel, Turkey | 17 | 103 |
| 17:20 HIV Retinitis Christos Kalogeropoulos, Greece | 18 | 105 |
| 17:40 Age related macular degeneration Miltiadis Tsilibaris, Greece | 19 | 111 |
| 18:00 Toxic retinopathies Isabelle Ingster, France | 20 | 115 |
| 18:20 End of session | | |

20:00 **EUPO Party details on page 8**

SATURDAY, October 2, 2010

EUPO Party



Classical Vouliagmeni Suites
8, Panos & Chlois streets, 16671 Vouliagmeni

SUNDAY, October 3, 2010

First morning session

| Moderators: Eberhart Zrener - Agnes Farkas | | Course | Page |
|--|--|--------|------|
| 09:00 | Retinitis pigmentosa Maria Stefaniotou, Greece | 21 | 125 |
| 09:20 | Stargardt Macular Dystrophy – Fundus Flavimaculatus Agnes Farkas, Hungary | 22 | 131 |
| 09:40 | Hypotonic Maculopathy Keith Martin, UK | 23 | 137 |
| 10:00 | Leber congenital amaurosis Sotiris Gartaganis, Greece | 24 | 141 |
| 10:20 | New Emerging Concepts of Treating Retinal Degeneration Eberhart Zrenner, Germany | 25 | 147 |

Second morning session

| Moderators: Slobodanka Latinovic - Chrysanthi Koutsandrea | | Course | Page |
|---|---|--------|------|
| 11:10 | Pneumatic retinopexy Slobodanka Latinovic, Serbia | 26 | 153 |
| 11:30 | Vitrectomy for RD Haritoglou Christos, Germany | 27 | 159 |
| 11:50 | Intraocular foreign bodies Chrysanthi Koutsandrea, Greece | 28 | 169 |
| 12:10 | Idiopathic Epiretinal Membrane (IERM) Panos Theodossiadis, Greece | 29 | 175 |
| 12:30 | Fundus imaging in ocular oncology Leonidas Zografos, Switzerland | 30 | 181 |
| 12:50 | End | | |
| 13:10 | Lunch | | |

1

The retina

Luc Missotten, Belgium

The retina is a part of the central nervous system brought forward in the eye.

We will study

- the barriers that protect this delicate tissue from external influences.
- the photoreception mechanism in rods and cones
- the analysis of the signal by various neurons in the retina and the transmission of the information to the brain.
- the regional differences in the retina.

In each chapter we pay attention to the clinical importance of the structures.

Recommended literature:

- The Organization of the Retina and Visual System
Kolb, H., E. Fernandez and R. Nelson. 2002. Webvision:
<http://www.webvision.med.utah.edu>
- How the Retina Works
H. Kolb 2003 American Scientist
<http://www.americanscientist.org/issues/num2/2003/1/how-the-retina-works/4>

***Prof. Dr. L. Missotten
Ophthalmology U.Z. St. Rafael
Kapucijnenvoer, 33
B-3000 Leuven Belgium***

2

Retina blood flow

Constantin Pournaraz, Switzerland

OCULAR CIRCULATION

Knowledge of the anatomy and the regulatory mechanisms of the various ocular vascular beds is crucial for understanding the pathophysiologic changes occurring during the evolution of several systemic and local diseases threatening vision. The delivery of metabolic substrates and oxygen to the retina in higher mammals, including humans and other primates, is accomplished by two separate vascular systems, the retinal and the choroidal systems.

The retinal and choroidal vessels differ morphologically and functionally from each other. The OA gives off 2 to 3 main ciliary arteries (CAs), i.e. the nasal and the temporal, which supply the corresponding hemispheres of the choroid via branches of the posterior CAs (PCAs) and recurrent branches of the anterior ciliary arteries (ACAs). The ACAs arise from the extraocular muscular arterial branching from the OA. The central retinal artery (CRA) enters the optic nerve approximately 10 to 15 mm behind the globe, from where it assumes its central position in the optic nerve up to the optic disk.

The retinal circulation is an end-arterial system without anastomoses. The CRA at the optic disk it divides into two major branches. These in turn divide into arterioles extending outward from the optic disk, each supplying one quadrant of the retina, although multiple branchings of the retinal arterioles towards the peripheral retina may occur. Retinal arteries and veins divide by dichotomous and side-arm branchings. In approximately 25% of human eyes, a cilioretinal artery emerging from the temporal margin of the optic disk supplies the macular region, exceptionally feeding the foveal region .

The terminal vessels, namely the precapillary arterioles and the postcapillary venules, are linked through the capillary bed, the venous system presenting a similar arrangement as the arterioles' distribution. The central retinal vein (CRV) leaves the eye through the optic nerve to drain venous blood into the cavernous sinus.

Vascular supply of the choroid

The vasculature of the choroid derives from the OA via branches of the 2 to 3 nasal and temporal main CAs and the ACAs, which supply the corresponding hemisphere of the choroid. The main CAs branch into 10 to 20 short PCAs, which enter into the globe at the posterior pole and assume a paraoptic and perimacular

pattern before branching peripherally in a wheel-shaped arrangement, and 2 long PCAs. Secondary and tertiary branches of the short PCAs are subsequently divided into the major choroidal arteries in paraoptic and perimacular pattern.

Fine structure of retinal and choroidal vessels

Retinal arteries differ from arteries of the same size in other organs in that they have an unusually well developed smooth muscle layer and lack an internal elastic lamina. The smooth muscle cells are oriented both circularly and longitudinally, each being surrounded by a basal lamina that contains an increasing amount of collagen toward the adventitia.

The capillary wall is composed of three distinct elements: endothelial cells, intramural pericytes and a basement lamina. The endothelial cells present at their thickest areas a nucleus bulging into the vessel lumen and express several cytoplasmic processes. Tight junctional complexes are found along the opposing surfaces of adjacent cells. The continuous endothelial cell layer is surrounded by a basal lamina within which there is a discontinuous layer of intramural pericytes in almost a one-to-one ratio with the endothelial cells. The recognition that pericytes are highly contractile cells, coupled with their uniquely high representation in the retinal microvasculature has led to the hypothesis that these cells play an important role in the regulation of retinal blood flow.

Transport through blood-retinal barriers

Optimal cell function requires an appropriate, tightly regulated environment. This regulation is determined by cellular barriers, which separate functional compartments, maintain their homeostasis, and control transport between them. The close interrelationship of epithelia and vascular endothelium with extracellular structures, namely extracellular matrix and glycocalyx, may modulate the dynamic responsiveness of barrier cells. Two major pathways control the passage through barriers, namely the transcellular pathway involving vesicles, specific carriers, pumps, and channels and the paracellular pathway through the intercellular cleft.

The endothelium of intraretinal blood vessels is considered as the main component of the inner blood-retinal barrier (BRB) resembling the blood-brain barrier in that both separate blood from neural parenchyma. The presence of a complex network of tight junctions, the absence of fenestrations and a relative paucity of caveolae make up the tightness of the iBRB. Numerous transport systems account for the selectivity of the barrier, such as the transport system for glucose across the retinal capillary endothelial cells of the inner BRB, which is mediated by

the sodium-independent glucose transporter GLUT1. The outer blood-retina barrier (BRB) is composed of three structural entities, the fenestrated endothelium of the choriocapillaris, Bruch's membrane, and the retinal pigment epithelium (RPE).

TECHNIQUES FOR MEASURING OCULAR BLOOD FLOW

A number of techniques have been developed to obtain quantitative information on the physiology, pharmacology and pathology of the blood circulation in the different ocular vascular beds.

The Retinal Vessel Analyzer (RVA) has simplified markedly the measurement of retinal vessels diameter (D), allowing also the quasi-continuous recording of D -changes evoked by various physiological maneuvers (dynamic measurements).

Bidirectional laser Doppler velocimetry (BLDV) allows the measurement of absolute blood velocity. Retinal BF (in $\mu\text{l}/\text{min}$) in the main retinal vessels is calculated from the centerline velocity (V_{max}) of the red blood cells (rbc) combined with D -measurements of these vessels and calculating the instantaneous

$BF_{mean} = \pi \frac{D^2}{4} V_{mean}$. V_{mean} represents an average over the vessel cross-section. For a parabolic velocity profile, $V_{mean} = V_{max}/2$.

Laser Doppler flowmetry (LDF) allows the measurement of the change in flux of rbc in the superficial layer of the ONH, the subfoveal choroid and the iris. The change in flux is proportional to the change in BF if this change is not accompanied by a change in hematocrit.

General hemodynamic considerations: BF through a blood vessel depends upon the perfusion pressure (PP), the pressure that drives blood through the vessel and the resistance (R) generated by the vessels. For an incompressible uniform viscous liquid flowing through a cylindrical tube (length L) with radius (r), BF is given by the Hagen-Poiseuille law: $BF = PP/R$, where $R = \eta L/2\pi r^4$. Many factors make it difficult to directly apply this law to a microvascular bed. These include the η -dependence on local hematocrit, the changes in the velocity profile of the rbc and shear rate at branchings and junctions and others.

Retinal BF: Retinal BF represents only about 4% of total ocular BF. In primates, total retinal BF obtained by the microspheres technique was reported to be between 25 to 50 ml/min/100g. In humans, recent measurements of total retinal BF (40.8 – 52.9 $\mu\text{l}/\text{min}$) using Fourier-Domain OCT are in the range of values obtained by BLDV.

Choroidal BF: In animals, choroidal BF is higher than in most tissues with estimates ranging from 500 to 2000 ml/min/100gtissue . There is no technique allowing reasonably precise measurements of choroidal *BF* in humans. The anatomical organization and dense vascularization of the choroid, as well as this high choroidal *BF*, optimize the partial pressure and concentration gradients for efficient diffusive exchange across the relatively long distance between the choroid and the retina for efficient delivery of oxygen and nutrients and the removal of carbon dioxide and metabolic waste. Thus about 65% of the oxygen and 75% of the glucose consumed by the monkey retina is delivered by the choroidal vessels.

Blood flow regulation

Correctly regulated hemodynamics and delivery of oxygen and metabolic substrates, as well as intact blood-retinal barriers are necessary requirements for the maintenance of retinal structure and function.

Retinal blood flow is autoregulated by the interaction of *myogenic* and *metabolic* mechanisms through the release of vasoactive substances by the vascular endothelium and retinal tissue surrounding the arteriolar wall. Autoregulation is achieved by adaptation of the vascular tone of the resistance vessels (arterioles, capillaries) to changes in the perfusion pressure or metabolic needs of the tissue. This adaptation occurs through the interaction of multiple mechanisms affecting the arteriolar smooth muscle cells and capillary pericytes.

Mechanical stretch and increases in arteriolar transmural pressure induce the endothelial cells to release contracting factors affecting the tone of arteriolar smooth muscle cells and pericytes. Close interaction between nitric oxide (NO), lactate, arachidonic acid metabolites, released by the neuronal and glial cells during neural activity and energy-generating reactions of the retina strive to optimize blood flow according to the metabolic needs of the tissue. NO, which plays a central role in neurovascular coupling, may exert its effect, by modulating glial cell function involved in such vasomotor responses.

During the evolution of ischemic microangiopathies, impairment of structure and function of the retinal neural tissue and endothelium affect the interaction of these metabolic pathways, leading to a disturbed blood flow regulation. The resulting ischemia, tissue hypoxia and alterations in the blood barrier trigger the formation of macular edema and neovascularization. Hypoxia-related VEGF expression correlates with the formation of neovessels. The relief from hypoxia results in arteriolar constriction, decreases the hydrostatic pressure in the capillaries and venules, and relieves endothelial stretching. The reestablished oxygenation of the

inner retina downregulates VEGF expression and thus inhibits neovascularization and macular edema.

Correct control of the multiple pathways, such as retinal blood flow, tissue oxygenation and metabolic substrate support, aiming at restoring retinal cell metabolic interactions, may be effective in preventing damage occurring during the evolution of ischemic conditions.

Constantin J. Pournaras, Switzerland

3

Fluorecein angiography, clinical interpretation

Gisèle Soubrane, France

The role of fluorescein angiography (FA) in managing AMD

FA is presently the gold-standard in the diagnostic examination and follow-up of CNV due to AMD.

Red-free, red light, blue light and autofluorescence.

Detailed interpretation of CNV is the basis to select the most suitable management strategy and therapy for patients with CNV due to AMD.

FA - Resulting classification.

The role of indocyanine green angiography (ICG-A) in diagnosis and management of AMD. ICG-A - additive information:

- early recognition of occult CNV
- conversion to precise network
- association to classic CNV
- localisation of CNV within a PED
- identification of clinically unexpected PED
- recognition of chorioretinal anastomosis

Conclusions

FA is still mandatory to diagnose and select the most effective management strategy and therapy.

ICG-A is a necessary adjunct to diagnosis, particularly in cases of occult CNV and in difficult cases.

The confrontation of FA, ICG and nowadays OCT imaging might improve the clinician understanding of the disease and thus select the most adapted treatment.

***Professeur Gisele Soubrane, MD, PhD, FEBO, FARVO
Paris, France***

4

OCT, clinical interpretation

Dimitrios Brouzas, Greece

Optical coherence tomography (OCT) is a non Invasive optical imaging technique. It captures two-dimensional images from within optical scattering media. Optical coherence tomography is an interferometric technique, depending on the properties of the light source (superluminescent diodes or ultrashort pulsed lasers) and has achieved sub-micrometer resolution.

Commercially available optical coherence tomography systems are employed in diverse applications. Optical coherence tomography is a rapidly emerging medical imaging technology that has applications in many clinical specialties. In ophthalmology, OCT is a powerful diagnostic technology because it enables visualization of the cross sectional structure of the retina and anterior eye with higher resolutions than any other non-invasive imaging modality. Furthermore, OCT image information can be quantitatively analyzed, enabling objective assessment of features such as macular edema or retinal nerve fiber layer thickness. OCT enables earlier and more sensitive detection of disease as well as improved monitoring of disease progression and response to therapy.

OCT is analogous to ultrasound mode imaging, but uses light waves instead of sound waves. A beam of light is directed to the target and the echo delay and magnitude of back reflected and backscattered light is measured, giving axial information similar to an ultrasound A scan. The light beam is then scanned in the transverse direction to generate a cross sectional image similar to an ultrasound B scan. OCT images can be displayed in grey scale or false color and represent a cross section through the tissue.

Although OCT is the optical analog to ultrasound, the technology of OCT is radically different. OCT imaging was challenging because the speed of light is much faster than the speed of sound. The direct electronic detection of these high speed echoes is impossible and this type of high resolution time measurement can only be performed using correlation techniques. OCT measures the echo time delay of light by using interferometry, correlating echoes of light from the retina with light which has traveled a known reference path delay.

Light in time domain OCT system is divided into two arms: a sample arm and a reference arm. The combination of reflected light from the sample arm and reference reference arm gives rise to an interference pattern, but only if light from both arms have travelled the “same” optical distance (“same” meaning a difference of

less than a coherence length). By this way, a reflectivity profile of the sample can be obtained.

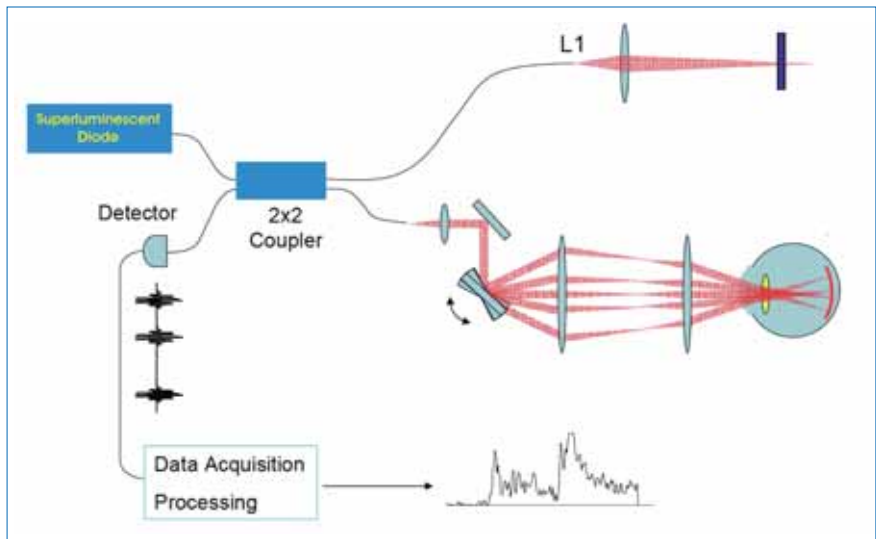


Fig 1: Time Domain OCT system.

Areas of the sample that reflect back a lot of light will create greater interference than areas that don't. Any light that is outside the short coherence length will not interfere. This reflectivity profile, called an A-scan, contains information about the spatial dimensions and location of structures within the item of interest. A cross-sectional tomography (B-scan) may be achieved by laterally combining a series of these axial depth scans (A-scan). En face imaging (C-scan) at an acquired depth is possible depending on the imaging engine used.

The axial image resolution in OCT depends upon the resolution with which echo time delays of light can be measured. This axial image resolution is determined by the bandwidth of the light source used for imaging. Standard resolution OCT systems use superluminescent diode light sources which have bandwidths that support 10- μm axial resolution imaging. However, using advanced femtosecond laser light sources, axial image resolutions can be dramatically improved. This ultrahigh resolution OCT (UHR) significantly improves image quality, and enables visualization of individual retinal layers.

in vivo ocular eye measurements and imaging of human eye, starting in late 80s from various groups world wide ^{[1][2][3]}. OCT was developed at the Massachusetts

Institute of Technology in 1990 and was first reported in 1991 [4]. First in vivo OCT images – displaying retinal structures – were published in 1993 [5][6]. Ultrahigh resolution OCT ophthalmic imaging was reported in 2001 [7].

Optical coherence tomography is one of a class of optical tomographic techniques. A relatively recent implementation of optical coherence tomography, frequency-domain optical coherence tomography, provides advantages in signal-to-noise ratio, permitting faster signal acquisition [8][9].

OCT has critical advantages over other medical imaging systems. Medical ultrasonography, magnetic resonance imaging (MRI) and confocal microscopy are not suited to morphological tissue imaging: the first two have poor resolution; the last lacks millimeter penetration depth [7][10].

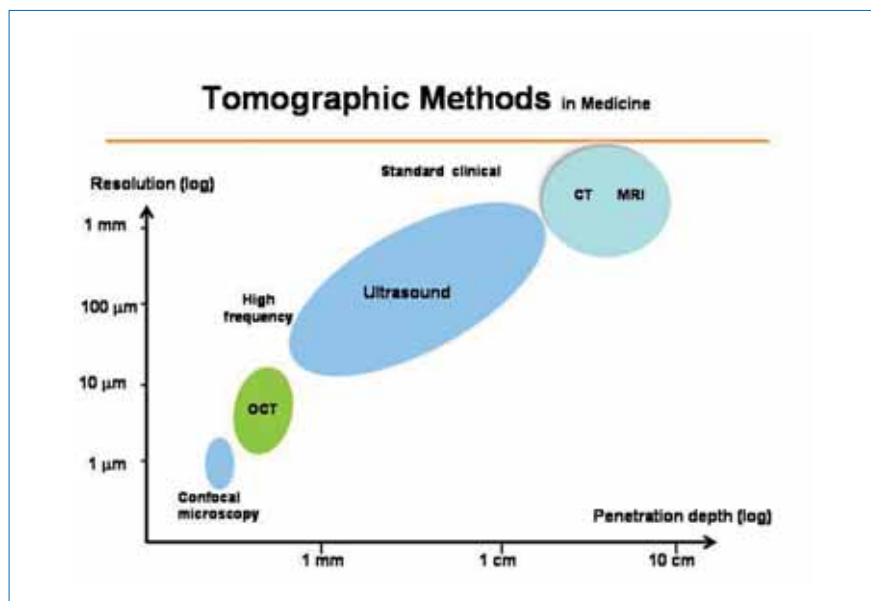


Fig 2: OCT vs. other tomographic methods

OCT is a powerful diagnostic tool for a variety of ocular diseases. In many cases, a definite diagnosis may be established directly from the OCT images.

In cornea images we differentiate the corneal epithelium, Bowman's layer, stroma, Descemet's membrane and endothelium. A view of angle region shows the iris contour and epithelium, the corneoscleral limbus and the anterior chamber angle.

The vitreoretinal interface is demarcated by the non-reflective vitreous and the backscattering surface of the retina. A highly reflective red layer delineates the posterior boundary of the retinal pigment epithelium and choriocapillaris. Below the choriocapillaris there is a relative weak scattering return from the deep choroid and sclera due to attenuation of the signal after passing through the retina and choriocapillaris. A dark layer just anterior to choriocapillaris represents the outer segments of retinal photoreceptors. The inner margin of the retina shows an area of bright back scattering, a red layer that corresponds to the retinal nerve fiber layer (RNFL). Retinal thickness is important in the assessment of many macular diseases. The accumulation of intraretinal fluid increases the retinal thickness and changes the scattering properties of the tissue. Inflammatory infiltrates and fibrosis are highly reflective, hard exudates and hemorrhages are highly reflective and block the reflection from the deeper retinal layers.

Vitreous inflammatory infiltrates, vitreous condensation or hemorrhage give significant back-scatter signal. The reflection from the posterior hyaloid is typically weak because vitreous has the same refraction index with fluid. An epiretinal membrane is easily recognized if it is detached from the retina otherwise the distinction depends in optical reflectivity differences.

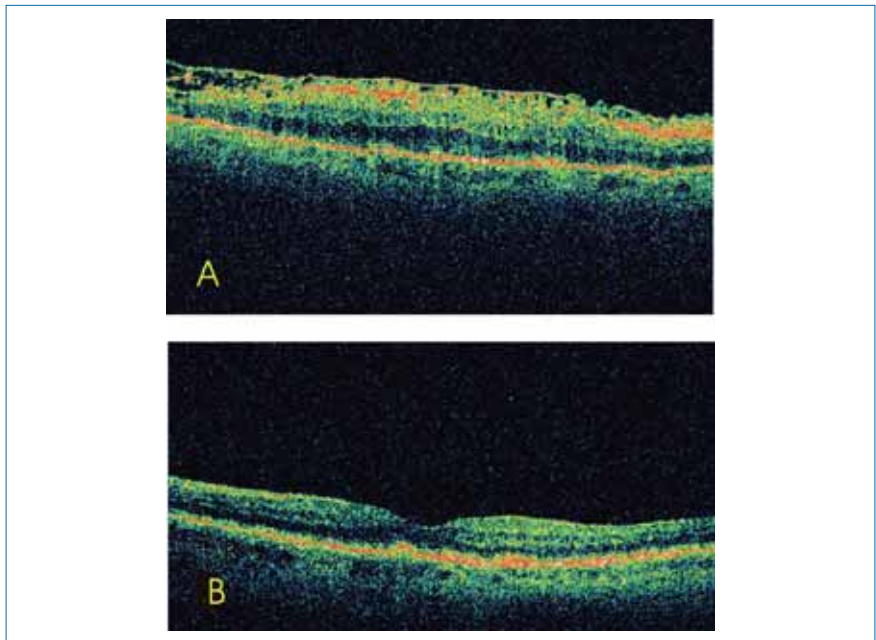


Fig 3

OCT can effectively distinguish macular pathologies. OCT can assess the status of vitreoretinal interface. It is effective in staging macular holes and permits measurements of hole diameter and the extent of surrounding subretinal fluid accumulation. Also OCT can monitor the progression or the recovery after macular surgery.

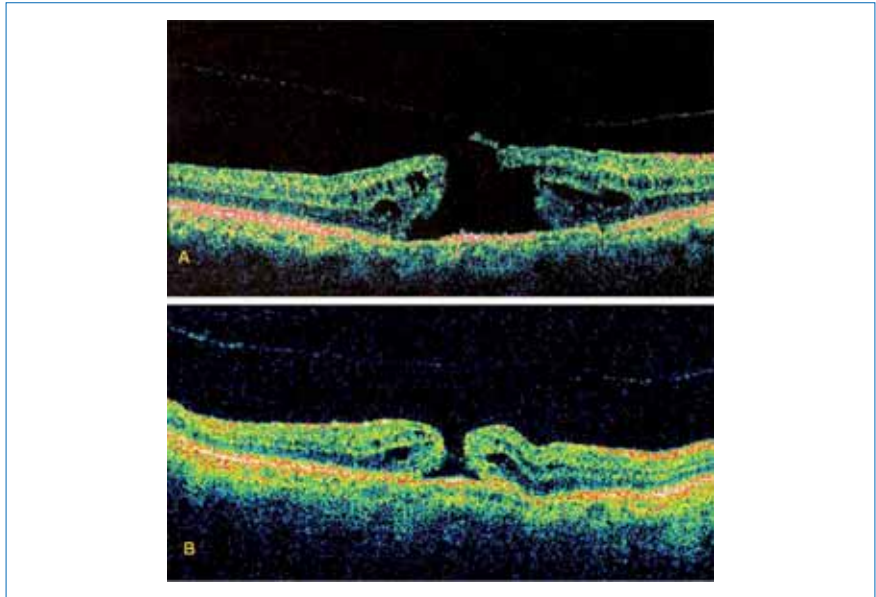


Fig 4: Epiretinal membrane A) Before and B) after surgery.

In retinal vascular occlusions and diabetic retinopathy OCT is useful in monitoring the development of macular edema and resolution of macular thickness after treatment.

In central serous chorioretinopathy (CSCR) OCT is highly sensitive to shallow elevation of neurosensory retina. It can distinguish CSCR from pigment epithelium detachment. OCT can provide additional diagnostic information in cases that occult choroidal neovascularization must be excluded.

In subretinal neovascularization there are abnormalities in the choriocapillaries and pigment epithelium. OCT is effective in quantification of subretinal, intraretinal and sub-pigment epithelium fluid. Also provides an objective means of following edema through successive examinations to evaluate the effectiveness of treatment.

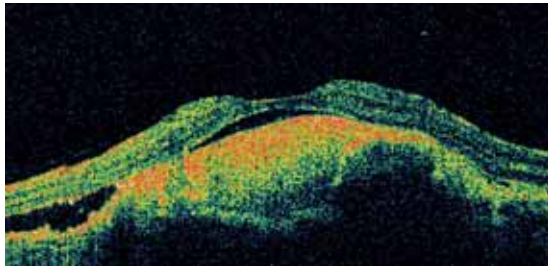


Fig 5: Macular hole A) Stage 2, the posterior vitreous face is attached. B) Stage 3, the posterior vitreous face is detached.

In chorioretinal inflammatory diseases migration of inflammatory cells into the retina and vitreous increases the concentration of optical scatters. OCT localizes the infiltrates to specific retinal layers and provides a means to track the extent of inflammation. OCT images through fovea allow accurate evaluation of macular edema and monitor the effectiveness of treatment.

For diagnosis of glaucoma and early detection of glaucomatous progression there are several types of scanning patterns useful in evaluating the optic nerve head providing information on cupping. The nerve fiber layer thickness and the degeneration in the peripapillary area may also be important in the diagnosis and post-treatment follow up of glaucoma. A useful way of assessing RNFL in this area is to image the retina by circular OCT tomograms centered on the optic nerve head. Each tomogram is displayed unwrapped corresponding to a clockwise scan around the optic disc. These measurements compared to standard normal values or values obtained from previous examinations combined with automated image analysis, provide objective assessment of glaucoma and glaucoma progression.

OCT can provide additional information in cases of optic nerve diseases such as optic atrophy, papilledema or optic disc pit.

OCT is a dynamically evolving new imaging technology with already significant contribution to diagnosis, follow up and understanding of many ocular diseases. Also OCT role in macular surgery is priceless.

References

1. Fercher AF, Roth E. "Ophthalmic laser interferometry. Proc. SPIE 1986;658: 48-51.
2. Fercher AF, Mengedoht K, Werner W. "Eye-length measurement by interferometry with partially coherent light.". Optics letters 1988;13: 186-8.
3. Naohiro Tanno, Tsutomu Ichikawa, Akio Saeki: "Lightwave Reflection Measurement," Japanese Patent # 2010042 (1990).
4. Huang D, Swanson EA, Lin CP, Schuman JS, Stinson WG, Chang W, Hee MR, Flotte T, et al. (). "Optical coherence tomography.". Science 1991;254: 1178-81.
5. Fercher AF, Hitzenberger CK, Drexler W, Kamp G, Sattmann H. " In Vivo Optical Coherence Tomography," Am. J. Ophthalmol. 1993;116:113-114.
6. Swanson EA, Izatt JA, Hee MR, Huang D, Lin CP, Schuman JS, Puliafito CA, FujimotoJG. "In vivo retinal imaging by optical coherence tomography". Optics Letters 1993;18: 1864.
7. Drexler W, Morgner U, Ghanta RK, Kärtner FX, Schuman JS, Fujimoto, JG. Ultrahigh-resolution ophthalmic optical coherence tomography. Nature Medicine 2001;7:502-7.
8. Schmitt JM. "Optical coherence tomography (OCT): a review". IEEE Journal of Selected Topics in Quantum Electronics 1999;5: 1205.
9. Fercher A. "Measurement of intraocular distances by backscattering spectral interferometry". Optics Communications 1995;117: 43.
10. Kaufman SC, Musch DC, Belin MW, Cohen EJ, Meisler DM, Reinhart WJ, Udell IJ, Van Meter WS. "Confocal microscopy: a report by the American Academy of Ophthalmology". Ophthalmol. 2004;111: 396-406.

5

Laser treatment in retinal diseases

Stavros Dimitrakos, Greece

Aim of the lecture: To initiate beginners in Ophthalmology to the principles of laser photocoagulation in retinal diseases, to the rationale and the techniques used in clinical practice and to provide fundamental guidelines for safe and efficient treatment.

History: During the past 50 years ophthalmologists conduct light through the ocular transparent media in order to burn structures of the fundus. A refinement of the technique consists in the use of a single frequency of electromagnetic radiation, within or outside the visible spectrum, by means of L.A.S.E.R. (Light Amplification by Stimulated Emission of Radiation).

I. BASIC KNOWLEDGE ON THERMAL LASER APPLICATIONS:

Laser frequencies and their biological effect: Laser is emitted from noble gas (Neon, Argon, Krypton, Xenon) tubes or from appropriate solid state Diodes, as visible light of a precise color or as invisible radiation, guided by a coaxial visible Laser, usually a Neon-red beam. If this radiation is properly conducted through the transparent media and focused on the ocular fundus, its energy is absorbed by the pigments of the fundus structures, such as, hemoglobin, oxyhemoglobin, xanthophyll, lipofuscin and melanin and transformed into heat. Fundus pigments capture Lasers depending on the complementarity of their absorption/emission frequencies. For example, red hemoglobins, yellow xanthophyll and orange lipofuscin capture more energy from blue or green Argon- than from red Krypton-Lasers. Thus Krypton Laser penetrates deeper into the outer retina and the choriocapillaris. Melanin captures completely any frequency.

Laser treatment indications in retinal and choroidal disease: Most common indications for Laser coagulation are the following:

1. Ischemic retinal angiopathies with inner blood-retinal barrier breakdown and capillary occlusion, such as Diabetic Maculopathy, with clinically significant macular edema and Pre-proliferative (ischemic) or Proliferative (neovascular) Diabetic Retinopathy, respectively.
2. Symptomatic retinal breaks secondary to vitreous traction.
3. Retinal macroaneurysms and extrafoveal subretinal new vessels.

How Laser burns act on the structures of the ocular fundus. Wavelength, pulse duration and spot size: Laser radiation passes through the clear ocular

media and focuses on the fundus, using appropriate optical devices. Corneal opacities and cataract may impede the flow of the radiation, especially of shorter wavelengths, thus requiring increased energy input. The radiation reaching the fundus is captured by the above mentioned pigments and transformed into heat, especially after the impact with melanin within the retinal pigment epithelium (RPE) and the choroid. The applied burn coagulates all structures surrounding the focus in three dimensions, depending on radiation wavelength, duration of energy delivery and spot size. Shorter wavelengths induce superficial burns; longer wavelengths penetrate deeper into the choriocapillaris. On the other hand, despite the fact that energy delivery equals to the product of Laser pulse power and pulse duration ($E=P \cdot t$, or Joule = Watt*sec), the biological effect of equal energy on the fundus tissues may be different. Considering constant energy delivery, short pulses of 0.1 sec penetrate deeper, longer pulses of 0.2-0.5 sec spread at the retina-RPE interface causing a burn fading towards its periphery. Similarly, a spot size of less than 250 μm induces more homogenous and deep penetrating burns than a spot size greater than 250 μm due to the fading effect toward the burn periphery. Finally, isolating media, such as air or silicone oil in contact to the retina, enhance the burn, as they do not absorb heat in the manner vitreous fluid does.

Complications: Laser photocoagulation of the fundus includes immediate hazards by inadvertent use, such as burns on the foveola, the papillomacular bundle and beneficial by-pass vessels and anastomoses, as well as, later complications, such as abnormal vitreo-retinal adhesions, fibroblast stimulation and remote ILM shrinking on the fovea.

II. ELEMENTARY KNOWLEDGE ON LASER APPLICATION TECHNIQUES:

Focusing a Laser beam on the fundus structures: In order to focus the aiming Laser beam at the same plane as the illuminating beam of the slit lamp, one should project a very fine slit on the focusing device of the slit lamp then adjust the ocular lenses of the biomicroscope switching them from the + to the - position. A Laser beam of 50 μm of diameter should be focused on the center of the fine slit until it reaches its minimal size and its maximal brightness. The Laser beam is consequently focused on the fundus simultaneously with the slit lamp.

Laser energy delivery parameters: The optimal spot size ranges between 200 – 250 μm , giving homogenous burns and diminishing the risk of hemorrhages or choroidal new vessel formation. A pulse duration of 200 μs gives homogenous burns and is safe even placed near the fovea. Such a pulse permits a power reduction by 50%, compared to a pulse of a shorter duration, to achieve the same energy delivery and the same burn intensity, and last but not least a diminished

discomfort for the patient. The laser operator should never forget that patient discomfort during photocoagulation, depends proportionally on the power delivered and inverse proportionally on the retinal thickness and water content at the treated site. Burns are more painful if placed at retinal periphery.

Strategies for the laser treatment: Depending on the area and extent as well as on the density of the laser burns, laser photocoagulation is characterized as focal, grid pattern or panretinal when used for the treatment of vascular retinal diseases. Coagulation is also used to surround retinal breaks under the vitreous base, without surrounding retinal detachment or to occlude retinal or choriocapillaris vessels in cases of retinal aneurysms or subretinal neovascularization (e.g. wet age related macular degeneration).

Useful tips for beginners:

Preparation for the treatment:

- Both patient and physician must be seated comfortably.
- Patient information about the nature of the treatment and the evidence based knowledge (e.g. ETDRS visual acuity), the aims and results of the Laser treatment and patient's informed consent must be available.
- Check devices, filters, aiming beam
- Appropriate laser spot size, power and duration must be set.
- Immobilize the ocular globe with a contact lens in order to diminish Bell's phenomenon (patient shutting the eyes as a reaction to pain).

Proper biomicroscopy of the fundus and laser application

- Always acquire an overview of the fundus and match biomicroscopy with angiography findings
- Retinal thickness relates to burn intensity and pain (macular thickness is greater than peripheral retinal thickness): Set and reset Laser power if necessary.
- Keep in mind that efficient burns are always less than those indicated by the shot count.
- Tilt the contact lens, exert pressure on the globe, use scleral indentation on the ora serrata and equator in order to achieve treatment of retinal breaks in the extreme retinal periphery.

Follow-up of the treatment issues:

- Compare best-corrected visual acuity (B.C.V.A.) before and after treatment

Literature

1. Diabetic Retinopathy Study Group: Photocoagulation treatment of proliferative diabetic retinopathy: the second report of the Diabetic Retinopathy Study (DRS) findings. *Ophthalmology*. 1978;85:82-106
2. Early Treatment Diabetic Retinopathy Study Group. Report No. 1: Photocoagulation for diabetic macular edema. *Arch Ophthalmol*. 1985;103:1796-1806
3. Mainster MA. Decreasing retinal photocoagulation damage: principles and techniques. *Semin Ophthalmol*. 1999;14:200-209
4. Diabetic Retinopathy Study Group: Photocoagulation of proliferative diabetic retinopathy: relationship of adverse treatment effects to retinopathy severity. DRS Report Number 5. *Dev Ophthalmol*. 1981;2:248-261
5. Henricsson M, Heiji A. The effect of panretinal photocoagulation on visual acuity, visual field and on subjective visual field impairment in preproliferative and early proliferative diabetic retinopathy. *Acta Ophthalmol Otolaryngol*. 1977; 83:476-487
6. Bandello R, Brancato R, Menchini U, et al. Light panretinal photocoagulation (LPRP) versus classic panretinal photocoagulation (CPRP) in proliferative diabetic retinopathy. *Seminars in Ophthalmol*. 2001;16:12-18
7. Sliney DH, Marshall J. Tissue specific damage to the retinal pigment epithelium: mechanisms and therapeutic implications. *Lasers Light Ophthalmol*. 1992; 5: 17-28
8. Friberg TR. Infrared micropulsed laser treatment for diabetic macular edema – subthreshold vs. threshold lesions. *Semin Ophthalmol*. 2001;16:25-30
9. Stefansson E. The therapeutic effects of retinal laser treatment and vitrectomy. A theory based on oxygen and vascular physiology. *Acta Ophthalmol Scand*. 2001;79:435-440
10. Mori K, Gehlbach P, Ando A, et al. Regression of ocular neovascularization in response to increased expression of pigment epithelium-derived factor. *Invest Ophthalmol Vis Sci*. 2002;43:2428-2434

***Professor and Head of the 2nd Department of Ophthalmology
Medical School, Aristotle University, Thessaloniki, Greece***

6

Principles of clinical electrophysiology

Alma Patrizia Tormene, Italy

1. Introduction

Electrophysiological eye tests aim to quantify the functionality of diverse parts of the visual system.

Because the conditions of adaptation to the light in which the test is carried out, just as different stimuli or different recording methods, can modify the characteristics of the response, the International Society for Clinical Electrophysiology of Vision periodically publishes or reviews the established criteria adopted for obtaining “standard” tests, i.e. tests considered to be fundamental for electrofunctional clinical diagnosis. (www.iscev.org).

All the currently available instrumentation is suitable for obtaining standard tests; using a common standard allows laboratories to compare the results they obtain. Each electrofunctional test is carried out using recording electrodes that are positioned as close as possible to the “generator” of the potential, reference electrodes and an earthed electrode.

Trace averaging techniques and filters are required to reduce noise and obtain the best quality traces possible to facilitate interpretation of results. ^[1]

Electrofunctional tests must however be associated with clinical objectivity and used alongside other imaging methods and ophthalmological functions so as to obtain the most detailed anatomo-functional picture possible of ocular pathologies.

2. Electroretinography

Electroretinography should be distinguished in Flash techniques: Full Field Flash Electroretinography (ERG) and Electroretinograms that are obtained using structured light stimuli: pattern ERG (PERG) and multifocal ERG (mfERG). ^[2]

2.1. Full Field Flash ERG

This involves recording the response to a short exposure to a light source, a flash: the flash is generated inside a cupola (Ganzfeld bowl) so as to ensure homogeneous illumination of the retina. The test must be done with the pupil dilated.

The light passes through the optic media and the retina activating photopigments in the photoreceptors and, consequently, inducing intraretinal transmission.

The transmission of an electrical “current” from the outer layers of the retina to the inner spreads towards the cornea and is recorded by the electrodes positioned on the surface of the eye (contact lens, fibre, gold foil or HKloop).

L'ERG full field is a mass electrical response generated by both the neural and non-neural retina cells of the whole retina. The specific characteristics of the diverse photo-receptors mean that, by exploiting retinal dark or light adaptation and flash stimulation intensity and frequency, electrical responses can be obtained from different “groups” of cells.

L'ERG full field is an objective measure of functionality of the retina and does not require any particular patient cooperation. This method can offer clinical information regarding pathologies that affect large groups of retinal cells (e.g. heredo-degenerative retinal diseases) but cannot offer much information about smaller areas of the retina (e.g. maculopathies).

Full field ERG standards cover 5 different ERGs (Fig. 1)

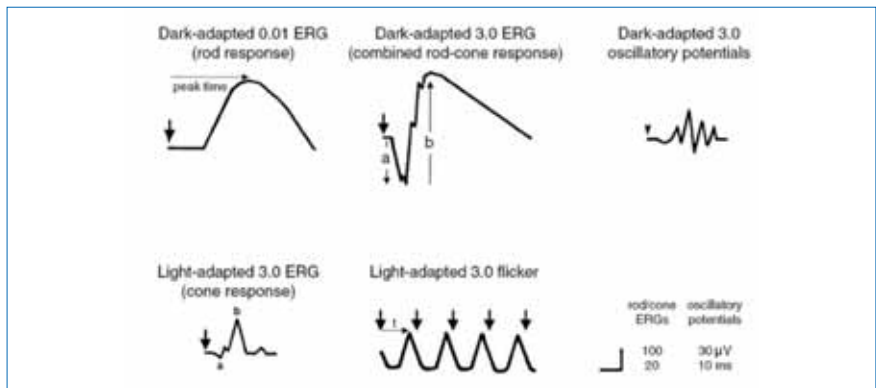


Fig. 1: ERG standard (ISCEV)

ERG Rod Response: after 20 minutes adaptation in the dark the retina is stimulated with a series of low intensity flashes of light (0.01 cd.s.m^{-2}). Retinal response comes mainly from the rods.

ERG Combined Rod and Cone Response: after adapting to the dark, the stimulation is with a high intensity flash (flash standard: 3.0 cd.s.m^{-2}), the retinal response obtained comes from both photoreceptor groups: cones and rods.

The trace is composed of a negative component (“a” wave) and a positive component (“b” wave). The a wave derives from the photoreceptors, while the b wave is the result of the transmission from external to internal layers of the retina (bipolar and Muller cells).

ERG Oscillatory Potentials: suitable filtration of low frequencies has highlighted a series of waves that can be found in the rising branch of the b wave which reveal

the activity at the level of intermediate retina and, in particular in the amacrin cells.

ERG Cone response: after 10 minutes adapting to the light ($30 \text{ cd}\cdot\text{m}^{-2}$) and with a high intensity flash (flash standard: $3.0 \text{ cd}\cdot\text{s}\cdot\text{m}^{-2}$) response can be obtained from the cones in the retina

ERG flicker response: a series of high intensity, high frequency flashes (30Hz) are used to determine response of those cells able to repolarise fastest: the cones.

ERG traces can be used to evaluate

- a amplitude: from the base line to its trough.
- b amplitude: from the trough of the a wave to the peak of the b wave.
- a and b implicit time (or peak latency): from the stimulus to the peaks of the two waves.

2.2. ERG produced by structured stimuli

2.2.a. Pattern ERG (PERG)

PERG is the response that is evoked by a structured stimulus (checkerboard) that covers 10° - 16° of retinal area. The retina is conditioned by being adapted to room light, the patient's pupil must not be dilated and the retina must optimum optical correction for the stimulation distance.

The most widely adopted stimulation used in clinical tests is the Transient pattern reversal stimulation with a temporal frequency of $< 3 \text{ Hz}$ (< 6 reversal per second).^[3]

The trace shows three waves: N35, P50, N95 whose amplitude and implicit time (peak latency) can be measured. (Fig. 2)

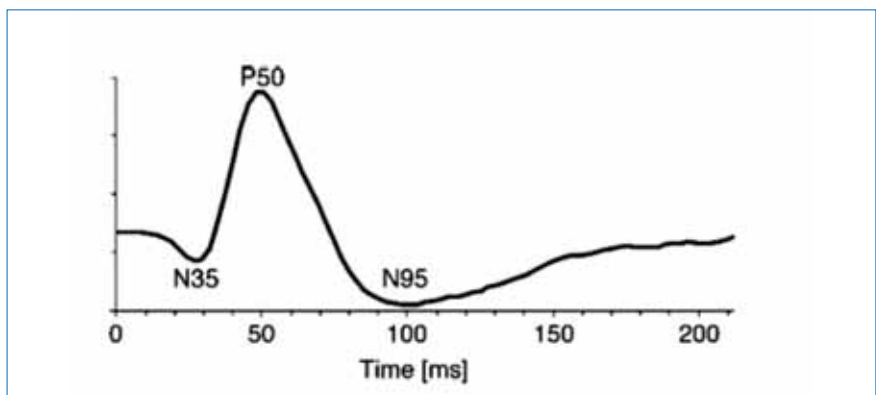


Fig. 2: Standard PERG transient pattern reversal

The first part of the trace (N35-P50) is influenced by ganglion cells functioning and by the external layers of the retina, wave N95 involves only ganglion cell functioning.

2.2.b. ERG multifocal (mfERG)

The mfERG response is evoked using a structured stimulus, an array of hexagonal elements, which are projected in the central 40°-60° degrees. Stimulation follows a pseudo-random sequence called the m-sequence and traces are the result of mathematical analysis of electrical variations that are created in the various areas of the retina being stimulated. [4]

The pupil must be dilated and the patient is examined in room light.

A series of waves will be obtained (usually 61 or 103 depending on the number of elements in the pattern) which correspond to the response from the retina areas that have been stimulated. (Fig. 3)

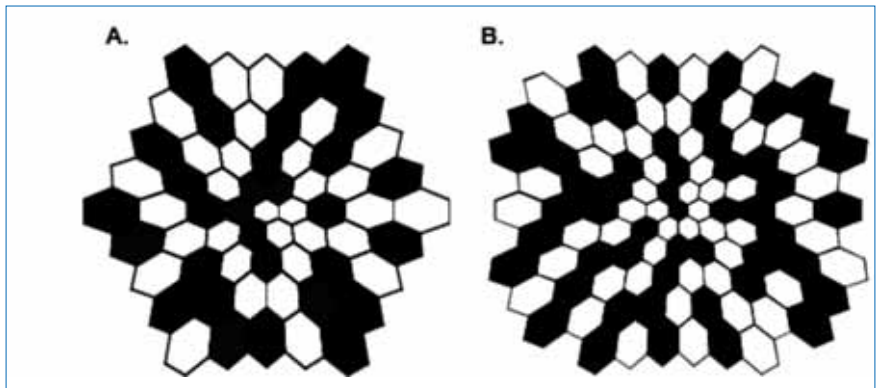


Fig. 3: mfERG: stimulus of 61 (A) and 103 (B) elements

Each trace has three waves N1-P1-N2.

Diverse mathematical analyses can be made of these traces (3D graphics, concentric rings, quadrants etc). (Fig. 4)

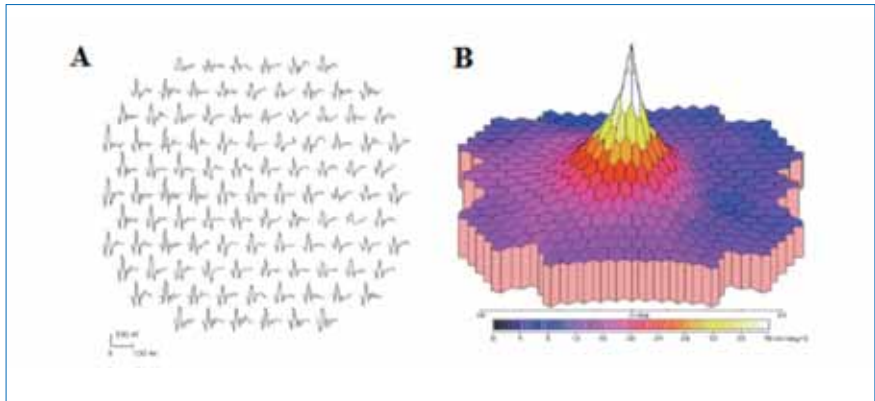


Fig. 4: Example of response to a 103 element stimulus: A: plot, B: 3D

The mfERG is a retinal response mediated by cones (cone driven retina).

3. Electro-oculography (EOG)

There is a difference of potential of about 6 mV (standing potential) between the inner and the outer retina. This potential is reduced after adaptation to the dark and increases during adaptation to light. Variations in this potential are the result of the functionality of the pigment epithelium in relation to photoreceptor activity. [5]

The spread of the charge from the posterior pole to the anterior pole of the eye renders the cornea positive with respect to the posterior part of the eyeball.

Thus we could see the eye as a dipole, with the anterior part positive and the posterior part negative.

When the eye carries out movements of a defined amplitude (in a Ganzfield bowl, looking at two leds, which light up alternately, and are placed 30° apart) and the movements are recorded by two electrodes placed close to the canthi of each eye, it reveals a difference in potential. This difference decreases during adaptation to the dark to a minimum (dark trough) which is usually reached after 20 minutes of adaptation; during adaptation to light (100 dc/m²) it increases to a maximum (light peak) which is usually reached after 15 minutes of adaptation to light. (Fig. 5)

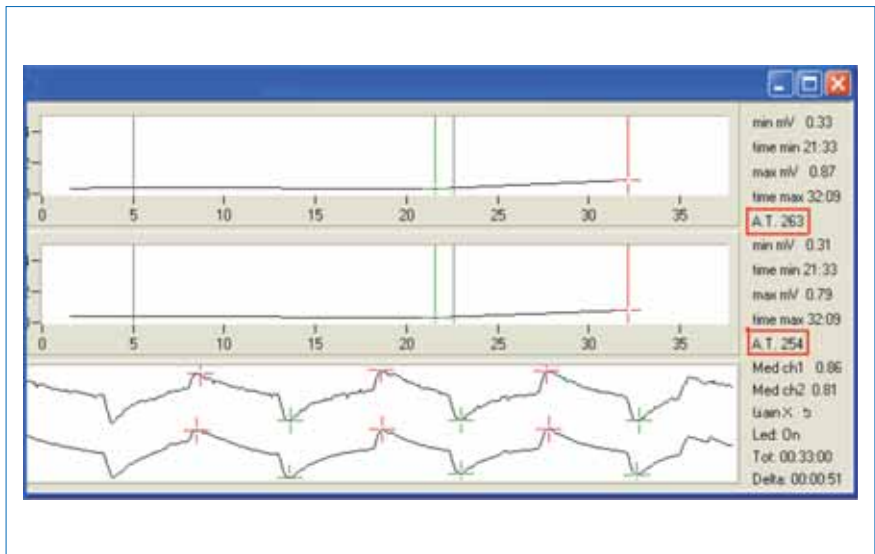


Fig. 5: graphic of EOG: Upper part: the trace obtained from diverse recordings made both in the dark and in the light. Lower part: saccadic movements. On the right the Arden ratio (AT) of the two eyes.

The light peak/dark trough relation ($LP/DT = \text{Arden ratio}$) indicates the functionality of the photoreceptors-pigment epithelium. In normal subjects the ratio is greater than 1.8 (180%).

4) Visual Evoked Potentials (VEPs)

Visual Evoked Potentials are signals that originate at the level of the occipital cortex when the retina is stimulated.

They are the result of a retinal stimulus being transmitted to the occipital cortex. VEPs can be obtained using flash stimuli (**flash VEPs**) or with structured stimuli (**pattern VEPs**).

Recording electrodes are placed on the skin at the level of the occipital cortex and the subject must be able to stare at the pattern with optimum optical correction. [6] Because of differences between individuals, flash VEP can only offer information as to whether there is, or is not, transmission.

Pattern VEPs are obtained by checkerboard stimulation in which the alternation can either be pattern reversal (dark elements alternating with light elements) or be pattern onset/offset (the checkerboard appears and disappears). Total luminance is however kept constant (isoluminant).

There are various waves in the traces of flash VEPs.

The most robust components of flash VEPs are the N2 and P2 peaks (Fig. 6):

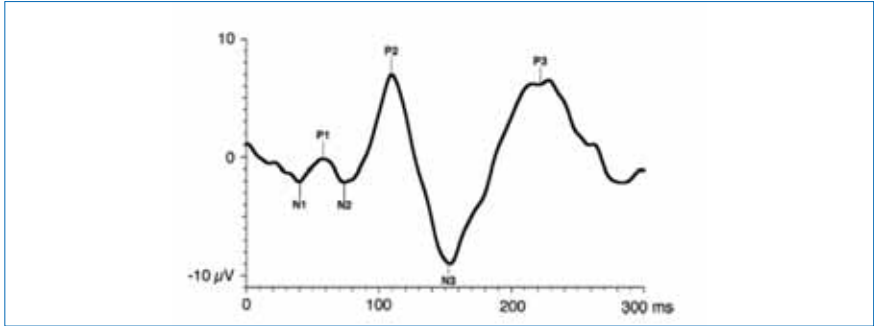


Fig. 6: Flash VEP Trace.

There are 3 waves in VEP transient pattern reversal: N 75, P100, N 135 (Fig. 7)

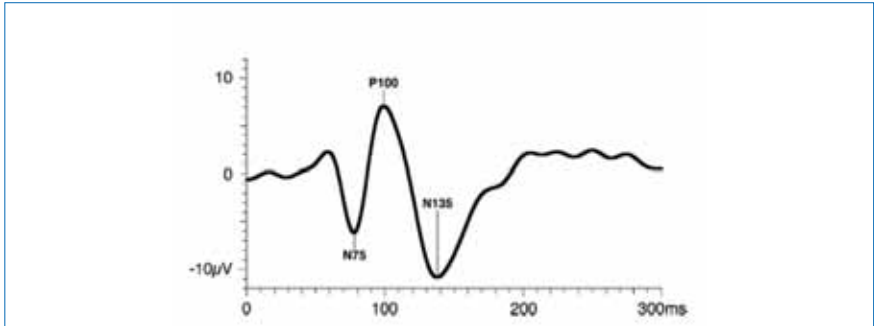


Fig. 7: VEP transient pattern reversal trace

The most important waves in onset/offset VEPs are called C1, C2, C3 (Fig. 8).

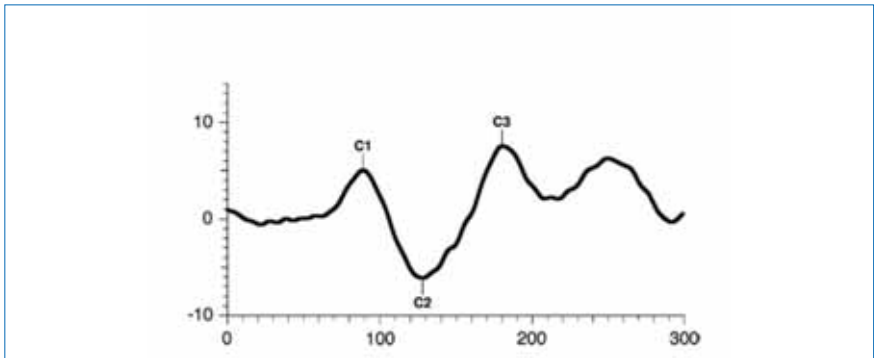


Fig. 8: Onset/offset VEP trace

Amplitude and implicit time (or peak latency) are revealed by the diverse components which offers information regarding the extent of the response and about the time the response takes to travel from the retina to the occipital cortex.

Onset/offset VEPs are less influenced by the level of patient cooperation when staring and offer useful information in the event of a malingering subject or in subjects with nystagmus.

References

1. Brigell M, Bach M, Barber C, Moskowitz A, Robson J. **Guidelines for calibration of stimulus and recording parameters used in clinical electrophysiology of vision.** Doc Ophthalmol 2003;107:185–193
2. Marmor MF, Fulton AB, Holder GE, Miyake Y, Brigell M, Bach M. **Standard for clinical electroretinography (2008 update).** Doc Ophthalmol 2009;118:69–77
3. Holder GE, Brigell MG, Hawlina M, Meigen T, Vaegan, Bach M. **ISCEV standard for clinical pattern electroretinography - 2007 update.** Doc Ophthalmol 2007, 114: 111-116
4. Hood DC, Bach M, Brigell M, Keating D, Kondo M, Lyons JS, Palmowski-Wolfe AM. **ISCEV Guidelines for clinical multifocal electroretinography (2007 edition) [www:iscev.org/](http://www.iscev.org/)**
5. Brown M, Marmor MF, Vaegan, Zrenner E, Brigell M, Bach M. **ISCEV Standard for Clinical Electro-oculography (EOG) 2006.** Doc Ophthalmol 2006 113: 205-212
6. Odom JV, Bach M, Brigell M, Holder GE, McCulloch DL, Tormene AP, Vaegan. **ISCEV standard for clinical visual evoked potentials (2009 update).** Doc Ophthalmol 2010;120:111-119

Alma Patrizia TORMENE
Ophthalmic Clinic – Department of Neurosciences
Padua University
Padua Italy

Notes

7

Clinical value of mfERG in macular diseases

Marilita Moschos, Greece

In 1849 Dubois-Reymond discovered in Fish eyes an electric potential using an electrode placed behind the eye, and in 1933 Granit put the bases of the Clinical Electrophysiology of Vision.

Since then the development of Clinical Electrophysiology was continuous and the changes of different components of Electroretinogram (ERG) were better interpreted.

Although the remarkable evolution of electrophysiological study of the retina, the Full-field ERG, is a mass potential, the result of the summed electrical activity of all the retinal cells. Therefore a pathological scotopic or photopic ERG is an indicator of an extensive, congenital or acquired, degeneration of cones or rods, but it is unable to prove the existence of a lesion in a limited retinal area, even if this area is the macula.

The cones of the macula account for only 7% approximately of the total cone population. As a result, cone responses from the macula contribute for less than 10% of the full-field cone ERG, and diseases limited to the macula typically are not detected with standard ERG. For this reason specialized techniques, like foveal or Pattern ERG, have been developed in order to record local responses to focal stimuli within the macula, but each of these methods had to overcome many problems related with the low amplitude and responses to stray light.

In 1992 Sutter and Tran ⁽¹⁾ introduced a multifocal-ERG (mf-ERG) system that can stimulate multiple retinal areas simultaneously and detect each response independently. With this method they have succeeded in constructing an ERG topography of fine resolution, which allows a functional mapping of the retina

The stimulus consists of 61 or 103 hexagons covering a visual field of 30 or 50 degrees around the macula and the responses are mapped geographically to produce a functional map of the retina, similar to the one of the visual fields testing. The response density (amplitude per unit retinal area, nV/deg²) of each local response was estimated as the dot product between the normalized response template and each local response. The mf-ERG stimuli location and anatomic areas corresponded roughly as follows: ring 1 to the fovea, ring 2 to the parafovea, ring 3 to the perifovea, ring 4 to the near periphery and ring 5 to the central part of the middle periphery. The amplitude of each group was scaled to reflect the angu-

lar size of the stimulus hexagon, which produces the response. These averages give a more accurate view of the relative response densities of each group. The retinal response density decreases with eccentricity, although there is no further decrease from ring 4 to ring 5 (Figure 1).

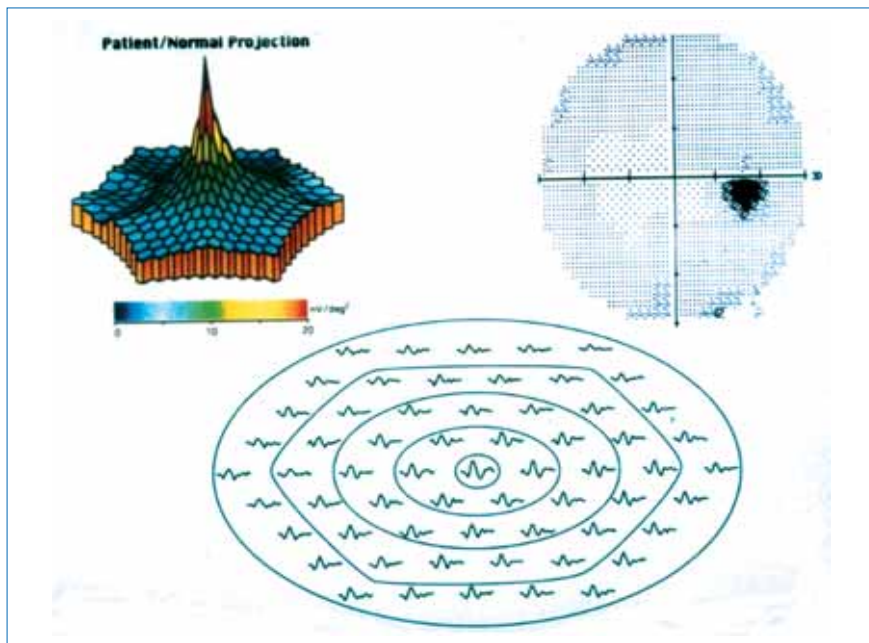


Figure 1. Normal mf-ERG. In the 3-Dimension plot the top corresponds to the fovea.

It is interesting that we may average solely the electrical responses of one of these rings or of the quadrants and measure separately the electrical activity of any retinal area.

In contrast to a single response using the Focal or the Pattern ERG, the mf-ERG indicates not only the central loss of function in maculopathies but also allows a detailed description of the extent of the lesion.

The reduction of central retinal activity can be detected in all kinds of maculopathies as in Stargardt disease, in cone dystrophy, Vitelliform maculopathies, juvenile retinoschisis, macular hole, epiretinal membrane ⁽²⁾, central serous chorioretinopathy ⁽³⁾ age-related macular degeneration (AMD) ⁽⁴⁾, diabetic retinopathy, central retinal vein occlusion (CRVO) ⁽⁵⁾, and others. This leads to a crater or volcano like appearance in the three dimensional plot.

Since some years the anti-VEGF like bevacizumab, ranibizumab or Pegaptanib are used widely for choroidal neovascularization due to AMD, CRVO or diabetic maculopathy. For monitoring the evolution of these diseases, OCT study and VA measurement are mainly used. OCT gives information only for the decrease or not of the macular edema, and VA is a subjective method unreliable for the evaluation of little improvement of vision especially in old people. For this reason it seems that in these cases, the study of electrical activity of the macula with mf-ERG may be more reliable for the assessment of macular function.

In conclusion the mf-ERG is a reliable objective diagnostic method not only for the detection and evaluation of macular function even in eyes without clinical symptoms, but also to monitor the evolution of a macular disease treated surgically or pharmaceutically.

References

1. Sutter EE, Tran D. The field topography of ERG components in man. I. the photopic luminance response. *Vision Res* 1992; 433-466.
2. Moschos M, Apostolopoulos M, Ladas I, Theodossiadis P, Mallias J, Moschos MM: The assessment of macular function by multifocal ERG before and after epiretinal membrane surgery. *Retina* 2001; 21: 590-595.
3. Moschos MM, Brouzas D, Koutsandrea C, Baltatzis S, Loukianou E, Papantonis F, Moschos M: Assessment of Central Serous Chorioretinopathy by Optical Coherence Tomography and multifocal ERG. *Ophthalmologica* 2007; 221: 292-298.
4. Koutsandrea C, Moschos MM, Brouzas D, Loukianou E, Apostolopoulos M, Moschos M: Intraocular Triamcinolone Acetonide for pseudophakic cystoid macular edema ; an OCT and MFERG study. *Retina* 2007; 27: 159-164.
5. Moschos MM, Moschos M: Intraocular bevacizumab for macular edema due to CRVO. A multifocal-ERG and OCT study. *Doc Ophthalmol* 2008; 116: 147-152.

Marilita M. Moschos, MD, PhD

Department of Ophthalmology, University of Athens, Greece

8

Retinal Ischemia

Marina Zueva, Russia

Ischemia refers to blood flow to cells and organs that is not sufficient to provide adequate oxygenation, and to maintain their normal function. Retinal ischemia results in irreversible morphologic and functional changes due to the deprivation of glucose and oxygen, followed by a cascade of biochemical responses involving glutamate release, water and ion transport, and activation of apoptosis-signaling pathways. Hypoxia is an integral part of ischemia and plays a vital role in pathophysiology of a large number of retinal diseases, and may occur as the ocular complication of a systemic disease. Retinal ischemia-hypoxia underlies central retinal artery occlusion and ischemic central retinal vein thrombosis; it is implicated in diabetic retinopathy (DR), age-related macular degeneration (AMD), glaucoma, retinopathy of prematurity (ROP).

Oxygen supply to the retina, and the vascular and neuronal networks cross-talk

Retina consumes oxygen more rapidly than other tissues, and the structural and functional integrity of the retina depends on a regular oxygen supply. Oxygen is delivered to the retina via two vascular systems: the retinal and choroidal blood supplies, which differently provide with nourishment retinal neurons. The retinal circulation is characterized by a low level of blood flow and high oxygen extraction. It provides oxygen to the inner two thirds of the retina, including the bipolar and ganglion cell layers. The choroidal circulation is characterized by high level of blood flow and low oxygen extraction and supplies the outer parts of the retina including retinal pigment epithelium, photoreceptors and parts of bipolar cells. Inner layers of the retina show highest sensitivity to hypoxia, whereas the outer retina is more resistant.

There is the balanced interplay of the neural retina and the vasculature that nourishes it, and therefore, retinal diseases in different extent affect both the neuronal and vascular nets.

Molecular mechanisms of ischemia and their role in pathophysiology of retinal diseases

In the retina, neuronal death and neovascularization (NV) are two most important pathological consequences of ischemia. In ischemia, the oxygen and glucose supply to the retina is blocked, disrupting cellular energy metabolism. Ischemia could injure the neurons by different mechanisms or their combinations. Asso-

ciated with ischemia molecular mechanisms underlying retinal diseases include oxidative stress, excitotoxicity, acidosis, the action of cytokines etc. These mechanisms overlap their pathways. Hypoxia induces transcriptional activator hypoxia-inducible factor-1 α (HIF-1 α) and its target genes vascular endothelial growth factor (VEGF) and nitric oxide synthase (NOS), whose overproduction was implicated in neuronal death.

Retinal ganglion cells (RGCs) are known to be more sensitive to ischemia than other retinal neurons. Evidence suggests that apoptosis is a prominent mode of ischemic cell death. There is a cell-specific sensitivity to ischemic injury, which may reflect variability in the balance of excitatory and inhibitory neurotransmitter receptors on a given cell. Retinal hypoxia results in increased release of VEGF, glutamate, inflammatory cytokines, reactive oxygen species (ROS) and other factors, which cause the RGCs loss through various mechanisms such as disruption of blood retinal barrier, excitotoxicity and accumulation of intracellular Ca²⁺.

In glaucoma, the RGCs are the primary cell types involved in glaucomatous injury to the retina. Various components in the optic nerve head may be affected by oligoemia/hypoxia because of an alteration in the microcirculation. Besides that, different other cell type alterations related to retinal ischemia sequel in pathophysiology of glaucoma are identified.

Abnormal vessel growth is observed in a number of eye diseases. Hypoxia and ischemia play an important role in choroidal NV development in AMD. Proliferative DR is characterized by retinal NV. NV also occurs in sickle cell retinopathy, branch vein occlusion retinopathy, ROP.

The molecular basis of NV involves the interplay of controlling factors. Retinal ischemia leads to NV through a VEGF. Other players include the fibroblast growth factor (FGF) family, tumor necrosis factor- α (TNF- α), insulin-like growth factor I (IGF-I), hepatocyte growth factor (HGF), angiopoietins. In the retina, angiogenesis is regulated by two counterbalancing systems: angiogenic stimulators, such as VEGF, and angiogenic inhibitors, such as angiostatin, transforming growth factor beta (TGF- β), and pigment epithelium-derived factor (PEDF). Under pathological conditions, breaking the balance between the positive and negative regulators of angiogenesis results in a higher VEGF/PEDF ratio, and as a result, endothelial cells over-proliferate, leading to retinal NV.

Another important factor playing critical role in ROP is IGF-I. IGF-I was shown to act indirectly as a permissive factor by allowing maximal VEGF stimulation of vessel growth. Lack of IGF-1 in preterm infants prevents normal retinal vascular

growth in phase I of ROP, despite the presence of VEGF. As infants mature, rising levels of IGF-1 in phase II of ROP allows VEGF stimulated pathological neovascularization.

Retinal neurons vulnerability to ischemia-hypoxia

RGCs are more sensitive to ischemia than other retinal neurons. Parvocellular RGCs appeared to be more resistant to ischemia as compared to magnocellular RGCs. Molecular bases of this difference could lie in the density of glutamate receptors on these neurons - the magnocellular neurons are more susceptible to NMDA toxicity. However, in glaucoma, recent works reported no evidence for specific magnocellular damage, and in electroretinography, the pattern ERG (PERG) to large stimulus checks is known to be relatively spared in early stages of glaucoma in contrast to the PERG to small check sizes.

Besides RGCs, all classes of neurons are susceptible to ischemia. Photoreceptors have the highest oxygen requirements of any cell in the body, and are involved in different hypoxic-ischemic diseases of the retina. Light-adapted photoreceptors are less sensitive due to diminished metabolic demands, and rods are more sensitive than cones. Amacrine cells in the inner retina are also sensitive to ischemia and glutamate excitotoxicity.

Electrophysiological visualization of ischemic damage to the retina

Electrophysiological methods allow us to estimate the alterations in different structures that contribute to visual function by recording evoked potentials of the retina and cortex. These methods serve for the objective monitoring of visual functions, and help us to understand the pathologic mechanisms in retinal and optic nerve hypoxia. Various components of electroretinogram (ERG) have different cellular origins, and ERG is a valuable tool for the assessment of blood flow-dependent and ischemia-dependent neural activity.

In different ocular pathologies, the ERG b/a-wave amplitude ratio and power density of the oscillatory potentials (OPs) provides the most accurate assessment of the degree of retinal ischemia. The OP power measurement appears to be a reliable method in detecting of preclinical signs in diabetic and hypertensive retinopathy. OPs are reduced also in patients with early glaucoma and optic nerve disease.

Retinal glial cells undergo an activation process in DR, glaucoma and other pathologies related to ischemia. Because Muller cells do not contribute to the ERG generation at more than 2 Hz, the ratio of the single-flash ERG b-wave amplitude to

the flicker ERG amplitude (the glial index, Kg) is used as a criterion of Muller cells' activity and glio-neuronal interactions. The Kg presented an objective mark of reactive gliosis in the retina, and of retinal ischemia.

Ganglion cell death could not be assessed by conventional ERG, and we have to pay a special attention to ERG tests that specifically reflect the RGCs (and inner retina) function. The PERG, which reflects ganglion cell activity itself, and the photopic negative response (PhNR) are most sensitive of these tests (especially in the early glaucoma). Another useful method is visual evoked potentials (VEP). The different modifications of OPs, PERG, PhNR and VEP methods have been using now, including based on the multifocal technique.

Summary

Retinal ischemia provokes a destructive cascade of events, which can result in RGCs loss and NV in a number of retinal pathologies. Knowledge of underlying molecular mechanisms of post-ischemic retinal disorders, which are still being elucidated, is necessary for understanding the pathophysiology of such diseases as DR, glaucoma, ROP, and plays an important role for the elaboration of new therapeutic strategies. Electrophysiology may help in early diagnosis, monitoring the course of the diseases, understanding of pathophysiological mechanisms, and may serve as a useful addition to morphologic evaluations in studies of neuroprotection.

References

1. Agarwal R., Gupta S.K., Agarwal P., Saxena R., Agrawal S.S. Current concepts in the pathophysiology of glaucoma. *Indian J Ophthalmol.* 2009; 57: 257-266.
2. Bach M., Hoffman M.B. Update on the Pattern Electroretinogram in Glaucoma. *Optom Vis Sci.* 2008; 85: 386-395.
3. Balasubramanyam M., Rema M., Premanand C. Biochemical and molecular mechanisms of diabetic retinopathy. *Current Sci.* 2002; 83(12): 1506-1514.
4. Bhutto I.A., McLeod D.S., Hasegawa T. et al. Pigment epithelium-derived factor (PEDF) and vascular endothelial growth factor (VEGF) in aged human choroid and eyes with age-related macular degeneration. *Exp Eye Res.* 2006; 82(1): 99-110.
5. Chen H., Wu D., Huang S. et al. The photopic negative response of the flash electroretinogram in retinal vein occlusion. *Doc Ophthalmol.* 2006; 113: 53-59.
6. Chen H., Zhang M., Huang S. and Wu D. The photopic negative response of flash ERG in nonproliferative diabetic retinopathy. *Doc Ophthalmol.* 2008; 117: 129-135.
7. Chen J., Smith L.E.H. Retinopathy of prematurity. *Angiogenesis.* 2007; 10: 133-140.
8. Derwent J.K., Linsenmeier R.A. Effects of Hypoxemia on the a- and b-waves of the electroretinogram in the cat retina. *Invest Ophthalmol Vis Sci.* 2000; 41: 3634-3642.
9. Drasdo N., Aldebasi Y.H., Chiti Z. et al. The S-cone PhNR and pattern ERG in primary open angle glaucoma. *Invest Ophthalmol Vis Sci.* 2001; 42: 1266-1272.
10. Falsini B., Riva C., Logean E. Flicker-evoked changes in human optic nerve blood flow: relationship with retinal neural activity. *Invest Ophthalmol Vis Sci.* 2002; 43: 2309-2316.
11. Feigl B., Brown B., Lovie-Kitchin J. et al. Functional loss in early age-related maculopathy: the ischaemia postreceptoral hypothesis (perspective). *Eye.* 2007; 21: 689-696.

12. Feig B., Stewart I.B., Brown B., Zele A.J. Local neuroretinal function during acute hypoxia in healthy older people. *Invest Ophthalmol Vis Sci.* 2008; 49: 807-813.
13. Harrison W.W., Viswanathan S., Malinovsky V.E. Multifocal Pattern Electoretinogram: Cellular Origins and Clinical Implications. *Optom Vis Sci.* 2006; 83: 473-485.
14. Fulton A.B., Akula J.D., Mocko J.A. et al. Retinal degenerative and hypoxic ischemic disease. *Doc Ophthalmol.* 2009; 118(1): 55-61.
15. Gotoh Y., Machida S., Tazawa Y. Selective loss of the photopic negative response in patients with optic nerve atrophy. *Arch Ophthalmol.* 2004; 122: 341-346.
16. Harwerth R.S., Carter-Dawson L., Smith E.L. III et al. Neural Losses Correlated with Visual Losses in Clinical Perimetry. *Invest Ophthalmol Vis Sci.* 2004; 45: 3152-3160.
17. Kaur C., Sivakumar V., Foulds W.S. Early response of neurons and glial cells to hypoxia in the retina. *Invest Ophthalmol Vis Sci.* 2006; 47: 1126-1141.
18. Kaur C., Foulds W.S., Ling E-A. Hypoxia-ischemia and retinal ganglion cell damage. *Clin Ophthalmol.* 2008; 2(4): 879-889.
19. Kizawa J., Machida S., Kobayashi T. et al. Changes of oscillatory potentials and photopic negative response in patients with early diabetic retinopathy. *Jpn J Ophthalmol.* 2006;50:367-373.
20. Kortuem K., Geiger L.K., Levin L.A. Differential susceptibility of retinal ganglion cells to reactive oxygen species. *Invest Ophthalmol Vis Sci.* 2000; 41: 3176-3182.
21. Machida S., Gotoh Y., Tanaka M. et al. Predominant loss of the photopic negative response in central retinal artery occlusion. *Am J Ophthalmol.* 2004; 137: 938-940.
22. Neufeld A.H., Kawai S., Das S. et al. Loss of retinal ganglion cells following retinal ischemia: the role of inducible nitric oxide synthase. *Exp Eye Res.* 2002; 75: 521-528.
23. Nishizawa Y. Glutamate release and neuronal damage in ischemia. *Life Sci.* 2001;69:369-381.

24. Osborne N.N., Casson R.J., Wood J.P. et al. Retinal ischemia: Mechanisms of damage and potential therapeutic strategies. *Prog Retin Eye Res.* 2004; 23: 91-147.
25. Parisi V., Miglior S., Manni G. et al. Clinical ability of pattern electroretinograms and visual evoked potentials in detecting visual dysfunction in ocular hypertension and glaucoma. *Ophthalmology.* 2006; 113: 216-228.
26. Rangaswamy N., Zhou W., Harwerth R., Frishman L.J. Effect of experimental glaucoma in primates on oscillatory potentials of the slow-sequence mfERG. *Invest Ophthalmol Vis Sci.* 2006; 47: 753-767.
27. Sattler R., Tymianski M. Molecular mechanisms of glutamate receptor-mediated excitotoxic neuronal cell death. *Mol Neurobiol.* 2001; 24(1-3): 107-129.
28. Sharma R.K. Molecular neurobiology of retinal degeneration. *Handbook of Neurochemistry and Molecular Neurobiology. Sensory Neurochemistry*, Edited by Lajtha A. and Johnson D.A., Springer-Verlag: Berlin Heidelberg, 2007. pp. 47-92.
29. Van Dam P.S. Oxidative stress and diabetic neuropathy: pathophysiological mechanisms and treatment perspectives. *Diabetes Metab Res Rev.* 2002; 18: 176-184.
30. Viswanathan S., Frishman L.J., Robson J.G. et al. The photopic negative response of the flash electroretinogram in primary open angle glaucoma. *Invest Ophthalmol Vis Sci.* 2001; 42: 514-522.
31. Wakili N., Horn F.K., Junemann A.G. et al. The photopic negative response of the blue-on-yellow flash-electroretinogram in glaucomas and normal subjects. *Doc Ophthalmol.* 2008; 117: 147-154.
32. Yucel Y.H., Zhang Q., Weinreb R.N. et al. Effects of retinal ganglion cell loss on magno-, parvo-, koniocellular pathways in the lateral geniculate nucleus and visual cortex in glaucoma. *Prog Retin Eye Res.* 2003; 22: 465-481.
33. Zacchigna S., de Almodovar C.R., Lafuste P., Carmeliet P. Vascular and neuronal development: intersecting parallelisms and crossroads. *Therapeutic Neovascularization – Quo Vadis?* Edited by Deindl E., Kupatt C., Springer: Netherlands, 2007. pp. 159-189.

Marina Zueva, Russia

Angiogenesis, the formation of new blood vessels from existing vessels, occurs through a multi-step process, including: production of angiogenic growth factors by diseased tissue, binding of angiogenic growth factors to receptors on existing vascular endothelial cells (EC), activation of EC gene expression of pro-angiogenic molecules, EC invasion of surrounding tissue, EC migration and proliferation, formation of vascular tubes by EC, and stabilization of new blood vessels by mural cells. Each of these steps is potentially vulnerable to pharmacologic targeting, and anti-angiogenic therapies directed at various steps are under investigation.

Under normal conditions, the vasculature is quiescent except during processes such as wound healing and the menstrual cycle, presumably due to a balance between inducers and inhibitors of angiogenesis. A critical step in the initiation of angiogenesis arises from changes in the tissue milieu which leads to an imbalance between inducers and inhibitors, either from increased levels of inducers, decreased levels of inhibitors, or both. Hypoxia in the retina is thought to alter this balance largely by increasing levels of pro-angiogenic growth factors. An important mediator of this process is hypoxia-inducible factor 1 (HIF-1), which is a heterodimer of α and β subunits. HIF-1 is a transcriptional regulator which is induced by hypoxia and which activates the transcription on an array of hypoxia-inducible genes (Duh, 2008). Activated endothelial cells proliferate and subsequently form vascular tubes. These immature vessels undergo further remodelling, with subsequent formation of a new basement membrane as well as recruitment of mural cells (pericytes or smooth muscle cells) to form a mature vessel. The recruitment of these mural cells is particularly important for the stabilization of the new blood vessels, and plays a critical role in the development of vessel resistance to regression.

More recently, it has become appreciated that in addition to preexisting vascular endothelium progenitor cells from the circulation may also play a role in retinal neovascularization. When hematopoietic stem cells (HSCs) containing a population of endothelial progenitor cells (EPCs) were administered by intravitreal injection into neonatal mouse eyes, there was stable incorporation of some of these cells into the developing retinal vasculature. Therefore, it is possible that EPCs may also play an important part in proliferative diabetic retinopathy, which may have therapeutic implications.

It has long been known that retinal neovascularization is strongly associated with retinal ischemia, based on clinical observations of ischemic retinopathies includ-

ing diabetic retinopathy. Retinal capillary nonperfusion precedes neovascularization in these retinopathies. The degree of capillary nonperfusion correlates with the risk of neovascularization in branch retinal vein occlusion. In 1948, Michaelson proposed that a diffusible angiogenic “factor X” released from areas of hypoxic retina, is responsible for neovascularization in diabetic retinopathy, as well as in other ischemic retinopathies.

In the 1990s, VEGF emerged as a strong candidate for “factor X”, and subsequent research has strongly established VEGF as a major stimulator of retinal neovascularization in the ischemic retinopathies, including proliferative retinopathy.

Interest of VEGF’s role in eye disease arose from early studies of VEGF’s systemic role, including its contribution to tumor angiogenesis. VEGF is a homodimeric glycoprotein that is both a vasopermeability and an angiogenesis factor. It was initially denoted as vasopermeability factor (VPF) based on its ability to increase microvascular permeability. VEGF is mitogenic primarily for vascular endothelium cells. The expression of VEGF has been found to be greatly increased in rapidly growing, highly vascularized tumors, and inhibition of VEGF with a monoclonal antibody inhibited tumor growth *in vivo*. The characteristics of VEGF suggest that it might play a major role in mediating the microvascular complications observed in diabetic retinopathy, since they are also characterized by tissue ischemia, angiogenesis, and vascular permeability.

VEGF is produced by many cell types within the eye, including retinal pigment epithelial cells, pericytes, endothelial cells, glial cells, Muller cells, and ganglion cells. In the context of diabetic retinopathy, VEGF upregulation was first appreciated in the proliferative stage. In the mid-1990s, clinical studies demonstrated significantly increased intraocular concentrations of VEGF in specimens from patients with proliferative retinopathies, including diabetic retinopathy. VEGF concentrations were significantly elevated in both the vitreous and aqueous of patients with active proliferative diabetic retinopathy. In contrast, VEGF concentrations were low in a control group of patients with no neovascular disorder, and in diabetic patients with no retinopathy, nonproliferative retinopathy, or quiescent proliferative retinopathy.

Although upregulation of VEGF in diabetic retinopathy was first reported in the proliferative phase, it has become increasingly appreciated that VEGF levels may be also elevated in nonproliferative diabetic retinopathy. Increased VEGF levels have also been demonstrated in the vitreous of patients with nonproliferative diabetic retinopathy, particularly in the setting of macular edema.

VEGF in ocular neovascularization

An extensive series of clinical and preclinical investigations has confirmed that VEGF plays a central role in promoting ocular neovascularization. Clinical studies have demonstrated elevated ocular levels of VEGF in patients with anterior segment neovascularization, retinal vein occlusion, neovascular glaucoma, retinopathy of prematurity, and proliferative diabetic retinopathy. In other studies, increased expression of VEGF was detected within the macula of patients with age-related macular degeneration and in choroidal neovascular membranes (Do et al, 2008).

Clinical application of Anti-VEGF drugs

Currently, there are three VEGF inhibitors commonly used in the treatment of proliferative retinopathies and AMD: pegaptanib (Macugen, OSI/Eyetech), bevacizumab (Avastin, Genentech), and ranibizumab (Lucentis, Genentech). While both pegaptanib and ranibizumab are approved for AMD in U.S. and many European countries, neither of the agents is a yet approved for the treatment of diabetes-related eye disease (Ip et al, 2008).

Review of available literature to date suggests that anti-VEGF pharmacotherapy, delivered by intravitreal injection, is a safe and effective treatment for neovascular AMD, for up to 2 years of follow-up for pegaptanib and for up to 1 year of follow-up for ranibizumab. There is level I evidence to support this conclusion for pegaptanib and ranibizumab, although the data suggest that vision outcomes with ranibizumab are superior to those with pegaptanib, and there is no definitive evidence to suggest a difference in safety between the drugs. There is level II and level III evidence that suggests bevacizumab, delivered by intravitreal injection, may be a safe and effective treatment for neovascular AMD, but the possibility that vision outcomes and safety may be inferior to those for ranibizumab has not been ruled out. Bevacizumab was introduced for ophthalmic use after FDA approval of pegaptanib and after the start of clinical trials for ranibizumab, and it has the least information available on safety and follow-up.

Pegaptanib has the longest follow-up available of the 3 anti-VEGF drugs in current use. Follow-up data to date demonstrate that pegaptanib has an acceptable safety profile in terms of ocular and nonocular adverse events. The disadvantage of pegaptanib is that, although the drug is effective at slowing the rate of visual acuity loss, treatment with pegaptanib is unlikely to result in a significant improvement in visual acuity.

Ranibizumab, like pegaptanib, has been subjected to a randomized clinical trial. The ANCHOR and MARINA studies demonstrate that ranibizumab is an effective treatment for neovascular AMD, although long term safety and efficacy data were lacking when this Ophthalmic Technology Assessment was written. Unlike pegaptanib, ranibizumab not only avoids substantial visual acuity loss (15 letters or more), but also increases the change for visual acuity gain (15 letters or more) in more than 25% of treated patients.

Ranibizumab is a commonly used anti-VEGF agent in the treatment of neovascular AMD because of its efficacy with respect to visual acuity improvement and acceptable safety profile with level I evidence to date. However vigilance with respect to safety must be maintained. In addition, there have been barriers to widespread adoption of this therapy. These include the high cost of the drug, the inability of some patients to pay for it, and the availability of a lower cost alternative (bevacizumab) that has not yet been proven to be non-inferior with respect to efficacy and safety.

References

1. Duh E. Retinal Neovascularization and the role of VEGF. In: Diabetic Retinopathy. Elia Duh, Humana Press, 2008, chapter 15, pp.353-373.
2. Michaelson IC. The mode of development of the vascular system of the retina, with some observations on its significance for certain retinal disease. Trans Ophthalmol Soc UK 1948;68:137-80.
3. Do D, Haller J, Adamis A, Striata C, Nguyen Q, Shah S, Jousseaume A. Anti-VEGF therapy as an emerging treatment for diabetic retinopathy. In: Diabetic Retinopathy. Elia Duh, Humana Press, 2008, chapter 17, pp.401-422.
4. Ip M, Scott I, Brown G, Brown M, Ho A, Huang S, Recchia F. Anti-vascular endothelial growth factor pharmacotherapy for age-related macular degeneration. Ophthalmology 2008;115:1837-1846.

J. Cunha-Vaz, Portugal

CSC is one of the 10 most common diseases of the posterior segment of the eye and a frequent cause of mild to moderate visual impairment. It is a sporadic disorder of the outer blood-retinal barrier, characterized by a localized detachment of the sensory retina at the macula, secondary to focal retinal pigment epithelium (RPE) defects. Any disorder that can destabilize this complex balance of forces at the level of the RPE will have an effect on retinal and retinal pigment epithelial adhesion.

The development of an isolated pigment epithelium detachment (PED) is thought to originate in the disintegration of the cellular connection between the RPE and the collagenous layer of Bruch membrane alone.

Although essential for maintaining the PED during a period of time by restricting fluid movement into the subretinal space, the outer blood-retinal barrier, however, may become compromised if the PED persists, and an associated serous retinal detachment originating in the area of the initial PED may be the consequence.

It is usually a self-limited disease typically affecting young or middle aged men with type A personality.

Definition-Staging: ACTIVE CSC is characterized by detachment of the neurosensory retina caused by accumulation of serous fluid between the photoreceptor outer segments and the RPE in combination with monofocal or multifocal changes in the RPE. The retinal detachment usually involves the fovea but exceptions to this rule can be found. Typical acute CSC is characterized by a duration of symptoms and / or retinal detachment of less than 6 months. The diagnosis of CHRONIC CSC requires multifocal or diffuse RPE depigmentation combined with a serous detachment of the retina. INACTIVE CSC, defined by the retina being fully attached, may be diagnostically challenging, but often a history characteristic of acute CSC dating back years or decades can be elicited.

As with other lesions of the RPE and/or Bruch's membrane, subretinal neovascularisation of choroidal origin may appear as a complication of CSC, however the risk is low^(9,10)

Symptoms: presentation is with unilateral blurred vision associated with a relative positive scotoma, micropsia, metamorphopsia and occasionally macropsia. The dark spot, which is the subjective representation of a relative scotoma in the centre of the visual field is usually most prominent in the morning immediately after awakening. The spot can often be made visible later in the day by blinking. In contrast to acute CSC, patients with sequels of CSC or chronic CSC may have blurred vision, but rarely (if ever) complain of seeing a dark spot.

There is also a delay in retinal recovery time after exposure to bright light, loss of colour saturation and diminished contrast sensitivity. Occasionally the condition is extrafoveal and asymptomatic. The elevation of the sensory retina gives rise to an acquired hypermetropia with disparity between the subjective and objective refraction of the eye.

Biomicroscopy: The subretinal fluid in CSC is commonly clear, but granular or fibrinous deposits may be present in the subretinal space.

Other characteristics include the absence of the normal foveal light reflex and a distinct visibility of the yellow foveal xanthophyll.

Abnormalities of the RPE are present, by definition, in CSC. When most prominent, these abnormalities are seen as one or more yellow spots or a small pigment epithelial detachment. The RPE detachment can occasionally be seen to be ruptured, the rupture being the site of profuse angiographic leakage. Unlike degenerative conditions such as retinitis pigmentosa, geographic RPE atrophy does not occur in CSC, whereas hypopigmented RPE is a frequent finding, characterized biomicroscopically by translucency without transparency. The subretinal material may disappear but it often leaves an imprint of permanent RPE hypopigmentation. Fluorescein angiography: shows one of the following patterns:

- Smoke-stack appearance is the most common
- Ink-blot appearance is less common

ICG: early phase shows dilated choroidal vessels at the posterior pole. The mid stages show multiple areas of hyperfluorescence due to choroidal hyperpermeability.

OCT: it can demonstrate shallow serous detachments that are difficult to diagnose using slit-lamp biomicroscopy ⁽⁸⁾. It shows an elevation of full-thickness sensory retinal layer from the highly reflective RPE layer, separated by an optically empty zone. OCT is also useful in determining whether reattachment has occurred after treatment.

VISUAL PROGNOSIS: Acute CSC that resolves spontaneously or following treatment has a good long-term prognosis for visual function. Chronic CSC frequently results in considerable irreversible visual acuity loss, despite some functional improvement early after reapposition of the retina and a subsequent phase of slow visual recovery. Recurrences develop in one third to half of cases after the first acute episode, 10% having three or more recurrences. About half of the patients experience recurrence within 1 year of the primary episode. These episodes tend to reduce final visual acuity, stereopsis, colour vision and central visual field function.

EXTRAOCULAR CONDITIONS THAT MAY INDUCE/AGGRAVATE CSC

- emotional stress, patients generally in good health and perfectly sane dealing with personal problems (type A personality)
- administration of steroids (orally or by inhalation).
- pregnancy, most often present in the third trimester and resolves within 1-2 months of delivery
- CSC has been described in relation to a large number of other systemic conditions, the majority of which are associated with glucocorticoid treatment of conditions such as systemic lupus erythematosus and in relation to endogenous hypercortisolism
- organ transplantation
- untreated hypertension
- An elevated prevalence of *Helicobacter pylori* infection in patients with CSC has been described compared to the background population

DIFFERENTIAL DIAGNOSIS OF SENSORY MACULAR DETACHMENT

- congenital optic disc anomalies
- choroidal tumours
- unilateral acute idiopathic maculopathy
- CNV
- Harada disease

TREATMENT

The high spontaneous remission rate favours conservative management, lifestyle counselling and discontinuation of glucocorticoid medication as first-line therapeutic options. If detachment persists for more than 3 months, photocoagulation or photodynamic therapy should be considered.

Acetazolamide: Systemic acetazolamide treatment promotes the resorption of subretinal fluid, however there is no evidence that treatment promotes healing of the RPE lesion, long-term preservation of visual function, or a reduced rate of recurrence.

References

1. Marmor MF: Structure, function, and disease of the retinal pigment epithelium. In *The Retinal Pigment Epithelium*. Edited by Marmor MF, Wolfensberger TJ. New York: Oxford University Press; 1998:3–9.
2. Wolfensberger TJ, Chiang RK, Takeuchi A, et al.: Inhibition of membrane-bound carbonic anhydrase enhances subretinal fluid absorption and retinal adhesiveness. *Graefes Arch Clin Exp Ophthalmol* 2000, 238:76–80.
3. Marshall J, Hussain AA, Starita C, et al.: Aging and Bruch membrane. In *The Retinal Pigment Epithelium*. Edited by Marmor MF, Wolfensberger TJ. New York: Oxford University Press; 1998:669–692.
4. Yoon YH, Marmor MF: Retinal pigment epithelium adhesion to Bruch's membrane is weakened by hemicholinium-3 and sodium iodate. *Ophthalmic Res* 1993, 25:386–392.
5. Chiang RK, Yao XY, Takeuchi A, et al.: Cytochalasin D reversibly weakens retinal adhesiveness. *Curr Eye Res* 1995, 14:1109–1113.
6. Faschinger C & Brunner H (1982): Gesichtsfelduntersuchung mit dem Computer- Perimeter Octopus nach Lasertherapie bei Chorioretinitis centralis serosa (Typ 1 nach Wessing). *Klin Monatsbl Augenheilkd* 181: 376–378.
7. Faurchou S, Rosenberg T & Nielsen N (1977): Central serous retinopathy and presenile disciform exudative macular degeneration. Is there an aetiological relationship between these two exudative conditions of the macula? *Acta Ophthalmol (Copenh)* 55: 515–524.
8. Bandello F, Incorvaia C, Parmeggiani F & Sebastiani A (2000): Idiopathic multiple serous detachments of the retinal pigment epithelium followed by bilateral central serous chorioretinopathy: a case report. *Ophthalmologica* 214: 362–367.
9. Gomez-Ulla F, Vazquez JM, Rodriguez-Cid MJ, Des J & Gonzalez F (2000): Central serous chorioretinopathy following pigment epithelium detachment: fluorescein and indocyanine green angiography follow-up. *Acta Ophthalmol Scand* 78: 232–234.

10. Wang M, Sander B, Lund-Andersen H & Larsen M (1999): Detection of shallow detachments in central serous chorioretinopathy. *Acta Ophthalmol Scand* 77: 402–405
11. Wong R, Chopdar A & Brown M (2004): Five to 15 year follow-up of resolved idiopathic central serous chorioretinopathy. *Eye* 18: 262–268.
12. Polak BC, Baarsma GS & Snyers B (1995): Diffuse retinal pigment epitheliopathy complicating systemic corticosteroid treatment. *Br J Ophthalmol* 79: 922–925.
13. Quillen DA, Gass DM, Brod RD, Gardner TW, Blankenship GW & Gottlieb JL (1996): Central serous chorioretinopathy in women. *Ophthalmology* 103: 72–79.
14. Bouzas E & Mastorakos G (1994): Central serous retinopathy in systemic lupus erythematosus: a manifestation of the disease or of its treatment? *Br J Ophthalmol* 78: 420–421.
15. Cotticelli L, Borrelli M, D'Alessio AC et al. (2006): Central serous chorioretinopathy and *Helicobacter pylori*. *Eur J Ophthalmol* 16: 274–278.
16. Sharma T, Shah N, Rao M et al. (2004): Visual outcome after discontinuation of corticosteroids in atypical severe central serous chorioretinopathy. *Ophthalmology* 111: 1708–1714.

Vasilios Kozobolis, Greece

Notes

11

Diabetic macular edema

Ursula Schmidt-Erfurth, Austria

Text not received

Notes

Proliferative diabetic retinopathy (PDR) is characterized by neovascularization (NV), new blood vessels that arise from the retinal and optic disc vessels and proliferate along the retinal surface or into the vitreous. Roughly 50% of patients with very severe nonproliferative diabetic retinopathy (NPDR) progress to PDR within 1 year. With sufficient capillary dropout there is ischemia of the inner retina and release of VEGF. VEGF is the triggering factor of the development of retinal NV. Other growth factors may also be involved in angiogenesis.

When proliferative vessels arise at or within 1 disc diameter of the optic disc they are referred to as NV of the disc (NVD), while, when they arise further than one disc diameter away, they are called NV elsewhere (NVE). Unlike normal or collateral retinal vessels, neovascular vessels result in leakage of fluorescein into the vitreous.

Neovascular vessels are often adherent to the posterior hyaloid. Vitreous and preretinal hemorrhages will occur as a patient undergoes a vitreoretinal separation pulling on the friable NV. The new vessels, initially naked, usually progress through a stage of further proliferation with connective tissue formation. As PDR progresses, the new vessels will undergo proliferation, more prominent fibrosis, and contraction. This process generally pulls on the neovascular-posterior hyaloid complex producing vitreo-retinal traction which can create tractional and/or rhegmatogenous retinal detachments (RD).

CLINICAL TRIALS & INDICATIONS FOR RETINAL PHOTOCOAGULATION TREATMENT

The Diabetic Retinopathy Study (DRS) was a multicentric, randomized, prospective study designed to determine whether panretinal laser photocoagulation treatment (PRP) in patients with PDR prevented severe visual loss (visual acuity < 5/200). According to its results, patients are considered **to have high-risk PDR if they present three or four of the risk factors listed in Table 1**. *Once patient has high-risk PDR, there is 25% risk that severe visual loss will develop within 2 years and a 45% risk in 3 years.* Further, **DRS demonstrated that the risk of severe visual loss is reduced by approximately 50% following PRP in eyes with high-risk PDR.**

Table 1. DRS – PDR RISK FACTORS

| |
|---|
| 1. PRESENCE of NV |
| 2. LOCATION of NV on or within one disc diameter of the optic disc (NVD) |
| 3. SEVERITY of NV ($\geq 1/3$ disc diameters if NVD or $\geq 1/2$ disc diameters if NVE) |
| 4. Vitreous or preretinal HEMORRHAGE |

For eyes with NPDR or PDR without high-risk characteristics the DRS recommended regular follow-up and prompt PRP if high risk characteristics develop. To assess the potential benefit of earlier PRP, the Early Treatment Diabetic Retinopathy Study (ETDRS) was designed. The results of the study led to a revised recommendation, lowering the threshold for PRP, in older patients with type II diabetes to very severe NPDR (Table 2) or early PDR without high risk characteristics. In younger patients with type I diabetes, the ETDRS recommendation is that PRP be deferred until DRS high-risk develop.

Table 2. Staging NPDR in SEVERE and VERY SEVERE according to ETDRS.

| STAGE | Clinical findings |
|--------------------|--|
| SEVERE | <p>At least ONE of the 3 following findings (known as «4-2-1 rule»)</p> <ul style="list-style-type: none"> • Dot/blot hemorrhages and/or microaneurysms in all FOUR quadrants • Venous beading in at least TWO quadrants • Intraretinal microvascular abnormalities (IRMAs) in at least ONE quadrant |
| VERY SEVERE | At least TWO of the 3 findings of the «4-2-1 rule» |

PANRETINAL PHOTOCOAGULATION

The currently recommended PRP treatment is a total of 1200 to 2000 burns 500µm in diameter through a Goldmann lens or the same number of 200µm burns if delivered through Mainster or Volk quadraspheric or PRP superquad 160 lenses. Burns would be placed about one burn width apart. The burns should be intense enough to whiten the overlying retina, which usually requires a power of 200-600mW and

duration of 0.1-0.2s. Most ophthalmologists use the argon blue-green or green laser, but a large clinical trial has shown that krypton red or dye yellow are equally effective. The treatment is usually divided over two to four sessions separated by 1-2 weeks.

The number of the burns necessary to achieve a good result has not been established. Some retina specialists feel that there is no upper limit to the total number of burns and that treatment should be continued until regression occurs. Topical anesthesia is usually adequate, although retrobulbar or peribulbar anesthesia may be needed, especially for re-treatments, or for treatments with longer wavelengths, or for indirect ophthalmoscope delivery.

Intraoperative and postoperative complications of PRP treatment include the following:

- 1. Macular edema:** Especially after a heavy treatment session or in eyes with perifoveal capillary non-perfusion. Recovery may occur within weeks, but sometimes visual loss may be permanent. In consequence, it is recommended that macular edema, if present, be treated at least two weeks before PRP is initiated.
- 2. Peripheral visual loss and decreased dark adaptation:** Especially after heavy confluent burns.
- 3. Choroidal detachment, exudative RD, choiroidal hemorrhage, retinal tears and rhegmatogenous RD,** as well as **progression of tractional RD.** (especially after extensive treatment).
- 4. Vitreous hemorrhage** as a result of rupture of NV during treatment.
- 5. Accidental foveal burn.**
- 6. Choroidal neovascularization** (even from peripheral burns).
- 7. Mydriasis and paresis of accommodation.**

CURRENT INDICATIONS OF VITRECTOMY IN PATIENTS WITH PDR

Presently vitrectomy is used in patients with PDR for three basic purposes:

- (1) removal of media opacities to allow PRP,
- (2) Repair of complicated RDs, or
- (3) treatment of severe NV nonresponsive to PRP (Table 3).

Table 3. INDICATIONS OF VITRECTOMY IN DR

| |
|---|
| <p>1. CLEARING MEDIA OPACITIES:</p> <ul style="list-style-type: none">a. Persistent vitreous hemorrhage (<i>1 month in type I and 3-6 months in type II diabetics</i>)b. Dense premacular subhyaloid hemorrhagec. Dense asteroid hyalosis that does not allow visualization of the fundus |
| <p>2. COMPLICATED RDs:</p> <ul style="list-style-type: none">a. Traction RD involving or threatening maculab. Combined traction & rhegmatogenous RDc. Severe equatorial fibrovascular proliferation |
| <p>3. UNCONTROLLED PDR IN SPITE OF FULL PRP</p> |
| <p>4. CHRONIC MACULAR EDEMA with taut attached posterior vitreous and/or preretinal fibrosis</p> |
| <p>5. GHOST CELL GLAUCOMA</p> |

References

1. Diabetic Retinopathy Study Research Group. *Ophthalmology* 88:583-600,1981.
2. Diabetic Retinopathy Study Research Group. *Int Ophthalmol Clin* 27:239-53,1987.
3. Diabetic Retinopathy Vitrectomy Study Research Group. *Arch Ophthalmol* 103:1644-52,1995.
4. Early Treatment Diabetic Retinopathy Study Research Group. *Arch Ophthalmol* 103:1796-806,1985.
5. Early Treatment Diabetic Retinopathy Study Research Group. *Int Ophthalmol Clin* 27:254-64,1987.

6. Early Treatment Diabetic Retinopathy Study Research Group. *Ophthalmology* 98(Suppl):766-85,1991.
7. Helbig H. In Jousseaume A, Gardner TW, Kirchhof B, Ryan SI (eds): *Retinal vascular diseases*. Springer, Berlin, pp 330-41, 2007.
8. Lee CM. In Spaide RF (ed): *Diseases of the retina and vitreous*. WB Saunders, Philadelphia, pp 129-43, 1999.
9. Soliman W, Larsen M. In Jousseaume A, Gardner TW, Kirchhof B, Ryan SI (eds): *Retinal vascular diseases*. Springer, Berlin, pp 342-52, 2007.
10. Sun JK, Miller JW, Aiello LP. In Blodi B (ed): *Retina and vitreous: In Albert & Jakobiec's: Principles and practice of Ophthalmology*. 3rd Ed., Elsevier, Philadelphia, pp 1807-27, 2008.

IOANNIS D. LADAS, M.D.

Associate Professor of Ophthalmology

Head of the Medical Retina Department

A' Eye Clinic of Athens University Medical School

Introduction

Retinal Vein Occlusion (RVO) is the second in incidence form of retinal vascular disease causing vision loss.¹ Branch RVO (BRVO) may result from compression of a branch retinal vein by an adjacent retinal artery, typically at a common abnormal arteriovenous crossing point. Central RVO (CRVO) typically arises when the central retinal vein is occluded posterior to or within the lamina cribrosa.^{1,2} Retinal hemorrhage and macula edema (ME) may complicate either form of RVO, resulting in partial or complete vision loss. Neovascularization of the iris (INV), anterior chamber angle (ANV), and retina (neovascularization on the disc or elsewhere – NVD or NVE respectively) in CRVO and BRVO may be a further complication.^{1,2}

CRVO and BRVO differ with respect to age of onset, pathophysiology, underlying systemic associations, clinical evaluation and therapy. CRVO can be divided further into ischemic and non-ischemic entities. This distinction among types of CRVO, although somewhat arbitrary, is important because most of patients with the ischemic variety develop INV and finally conclude to neovascular glaucoma.³

Risk factors and Systemic associations (Table 1)

CRVO most commonly occurs in individuals over 50 years old.³ Concurrent systemic vascular diseases are risk factors for CRVO. Diabetes mellitus (DM), systemic arterial hypertension (SAH), carotid insufficiency, dyslipidemia, renal dysfunction and atherosclerotic cardiovascular disease are the most frequently associated underlying medical diseases, although their direct relationship to pathogenesis remains speculative.^{4,5} The Eye Disease Case-Control Study found an increased risk of any type of CRVO in those with SAH and DM.⁶ Persons with nonperfused CRVO had a greater risk compared to persons with perfused one, implicating systolic and diastolic hypertension as a risk factor. According to large population studies DM was more prevalent in individuals with nonperfused CRVO than controls.^{4,5,7} An increased risk in cardiovascular disease is present in persons with CRVO, although in population-based studies mortality rates were not found increased too.⁷

Hematological abnormalities, particularly conditions that predispose to a hypercoagulable state, have been identified in persons with CRVO. Individuals less than 60 years old may have a greater association with systemic hypercoagulable states

Table 1: Systemic associations and Risk factors for CRVO

| Systemic vascular diseases | Hematological alterations | Inflammatory /autoimmune vasculitis | Infectious vasculitis | Ocular diseases | Medications | Other |
|--|--|-------------------------------------|-----------------------|------------------------------|---------------------|------------------------|
| Diabetes Mellitus | Dysproteinemias (multiple myeloma, cryoglobulinemia) | Systemic Lupus Erythematosus | HIV | Open Angle Glaucoma | Oral Contraceptives | After retrolubar block |
| Systemic Arterial Hypertension | Blood Dyscrasias (polycythemia vera, lymphoma, leukaemia, sickle cell disease) | | Syphilis | Acute Angle-closure Glaucoma | Diuretics | Dehydration |
| Carotid Insufficiency | Elevated plasma Homocysteine | | Herpes Zoster | Ischemic Optic Neuropathy | Hepatitis B vaccine | Pregnancy |
| Atherosclerotic Cardiovascular Disease | Factor XII Deficiency | | Sarcoidosis | Pseudotumor Cerebri | | |
| | Antiphospholipid Antibody Syndrome | | | Tilted Optic Nerve Heads | | |
| | Activated protein C resistance | | | Optic Nerve Head Drusen | | |
| | Protein C Deficiency | | | Optic Disc Traction Syndrome | | |
| | Factor V Leiden | | | Thyroid Ophthalmopathy | | |
| | Abnormal Fibrinogen levels | | | Orbital Fracture | | |
| | Low serum Folate levels | | | | | |
| | Protein S Deficiency | | | | | |
| | Anemia | | | | | |

and inflammatory conditions, compared to older persons with higher incidence of systemic vascular disease risk factors.^{3,4} Viscosity is mainly dependent on the hematocrit (the greater the number the of erythrocytes, the larger they aggregate) and plasma fibrinogen (required for aggregation to occur).⁸ Hyperviscosity syndromes include blood dyscrasias such as polycythemia vera, lymphoma, leukaemia, sickle cell disease or trait and paraproteinemias or dysproteinemias which in turn include multiple myeloma and cryoglobulinemia.⁸

Studies have demonstrated an increased incidence of coagulation cascade abnormalities, including protein C deficiency, protein S deficiency, activated protein C resistance (APC resistance), presence of factor V Leiden, presence of antiphospholipid antibodies (APA), and abnormal fibrinogen levels.³ The coagulation cascade results in the production of thrombin, which converts circulating fibrinogen to fibrin. The coagulation sequence is held in check and inhibited by specific anticoagulants including protein C, protein S, and antithrombin III.⁸ Protein C is serine proteinase whose activated form is a potent inhibitor of coagulation factors V and VIII.⁹ Factors V and VIII are a part of the coagulation cascade leading conversion of fibrinogen to fibrin. Protein S and phospholipids are co-factors in the inactivation of factors V and VIII by activated protein C.⁹ An absolute deficiency of protein C or S is relative rare.⁸

APC resistance was subsequently shown to be a risk factor for venous thrombosis.¹⁰ More than 90% of patients with APC resistance have been shown to have a single point mutation in factor V gene.¹⁰ This mutation hinders the degradation of factor V normally occurring through protein C.^{8,10} APA consists of a heterogeneous group of immunoglobulins, mainly anticardiolipins antibodies (ACA) and lupus anticoagulants (LA). Circulating APA leads to a hypercoagulable state and recurrent thrombosis through thrombocyte activation and inhibition of the natural anticoagulant pathways by binding of membrane phospholipids.⁸

An elevated level of the amino acid, homocysteine is generally accepted to be a risk factor for systemic vascular disease.¹¹ Homocysteine appears to have a deleterious effect on vascular endothelium and may induce increased platelet aggregation and thrombosis. Levels of homocysteine may be increased by dietary habits, prescription medicines, or enzymatic mutations affecting homocysteine metabolism.¹² Scientists investigated the prevalence of genetic mutation in the enzyme methylentetrahydrofolate reductase (MTHFR) whose impaired activity may lead to hyperhomocysteinemia.¹³ The prevalence of this mutation was significant higher in patients with RVO compared with incidence of MTHFR in a control population. In published studies, an association with elevated plasma homocysteine and low serum folate levels, but not serum vitamin B12 and the

thermolabile MTHFR genotype, was observed in eyes with RVO. Anemia, factor XII deficiency and dehydration have also been reported with CRVO. ¹⁴

Other risk factors responsible for CRVO are vasculitis of syphilis and sarcoidosis and an autoimmune disease such as systemic lupus erythematosus (SLE). ¹⁴ Oral contraceptive use in women may be associated with both thromboembolic disease and CRVO. Complete normal medical and laboratory evaluation results are found in about one fourth of patients. ¹⁵ A significant inverse association with CRVO, representing decreasing risk, occurs with alcohol consumption, education, physical activity, and, in women with exogenous estrogen use.³

Open angle glaucoma is a relatively common finding in patients who have CRVO. Patients with a history of glaucoma are about five times more likely to have CRVO than those who do not, because of structural alterations of the lamina cribrosa induced by the elevated intraocular pressure. Acute angle-closure glaucoma may also precipitate in CRVO. ³

Other ocular conditions causing mechanical pressure on the optic nerve head and lamina cribrosa, including ischemic optic neuropathy, tilted optic nerve head, optic nerve head drusen, optic disc traction syndrome and pseudotumor cerebri, ¹⁶ have also been associated with CRVO. External compression of the eye-globe and optic nerve from thyroid-related ophthalmopathy or mass lesion and head trauma with orbital fracture might also result in CRVO. ^{7,14}

Pathogenesis

The pathogenesis of CRVO is multifactor. The precise pathogenesis of CRVO remains obscure. The clinical picture of CRVO may be explained by the occlusion of the main trunk of the central retinal vein, although the pathophysiology of CRVO is yet not clearly understood. Histopathologic studies of eyes with CRVO demonstrated a thrombus in the central retinal vein occluding its lumen of the central retinal vein at, or just proximal (posterior) to, the lamina cribrosa. ¹⁷ This finding suggests that the anatomic variations at the level of the lamina cribrosa may be responsible for the development of a CRVO. Similar histopathologic studies in eyes with CRVO revealed the formation of a fresh or recanalized thrombus at or just posterior to the lamina cribrosa. Within the thrombi, a mild lymphocytic infiltration with prominent endothelial cells was found. Loss of inner retinal layers consistent with inner retinal ischemia was also a common finding. ¹⁷ Histopathological studies showed that in acute CRVO cases, a thrombus at the level of the lamina cribrosa was adherent to a portion of the vein wall devoid of an endothelial lining. Subsequently, there was observed endothelial cell proliferation within the vein and

secondary inflammatory cell infiltrates. Finally, recanalization of the thrombus was demonstrated 1-5 years after the occlusion.^{7,17}

Thrombosis of the central retinal vein is an end-stage phenomenon according to an alternative theory and is induced by a variety of primary lesions, such as compressive or inflammatory optic nerve or orbital problems, structural abnormalities in the lamina cribrosa, or hemodynamic changes.³

Arteriosclerosis of the neighbouring central retinal artery, which is associated with the above-mentioned systemic disorders, causes turbulent venous flow and then venous endothelial and intima media damage and it is often implicated in CRVO too.³ Within the retrolaminar portion of the optic nerve, the central retinal artery and vein are aligned parallel to each other in a common tissue sheath. The central retinal artery and vein are naturally compressed as they cross through the rigid and sieve-like openings in the lamina cribrosa, but typically give off branching collateral vessels just before piercing the lamina. These vessels may be subject to compression from mechanical stretching of the lamina due to increases in intraocular pressure, causing a posterior shift or bowing of the lamina with subsequent impingement on the central retinal vein.⁷ Furthermore, local factors can predispose to CRVO, including compression by an atherosclerotic central retinal artery or primary occlusion of the central retinal vein from inflammation.

Glaucoma has been also associated with CRVO. It has been hypothesized that glaucoma causes stretching and compression of the lamina cribrosa, which results in vessels abnormalities, increased resistance to flow and, ultimately, thrombosis.¹⁷

Alterations in blood flow, hyperviscosity, and vessel wall abnormalities may also produce CRVO by enabling a thrombus of the central retinal vein to form.³ Endothelial cell proliferation has been also suggested and implicated in CRVO. Retinal venous circulation represents a relatively high-resistance, low-flow system and therefore it is particularly sensitive to hematological factors.³ Hemodynamic alterations may produce stagnant blood flow and subsequent thrombus formation in the central retinal vein, including diminished blood flow, increased blood viscosity, and an altered lumen wall (also known as Virchow's triad).⁷ Studies indicate that an elevated hematocrit level, elevated homocysteine level, elevated fibrinogen level, increased blood viscosity, the presence of a lupus anticoagulant or another antiphospholipid antibody, and a deficiency in activated protein C along with an elevated erythrocyte sedimentation rate and antithrombin III levels may be associated with retinal venous disease. Whether these hematological factors alone can initiate a CRVO or whether their role is to function as co-factors remains unknown.^{18, 19}

Concurrent retinal artery insufficiency or occlusion may play role in an ischemic CRVO. Experimentally, occlusion of both the retrolaminar central retinal artery and central retinal vein, posterior to the lamina cribrosa and before collateral vessels branch from the main trunk, was required to produce the clinical appearance of ischemic CRVO.²⁰ Non-ischemic CVO is hypothesized, to be due to occlusion of the central retinal vein proximal to the branching of the collateral vessels, providing alternative routes venous blood flow into the central retinal vein within the optic nerve.²⁰

The development of macular edema (ME) followed by CRVO is based on the breakdown of blood-retinal barrier (BRB) and secretion into the vitreous of vasopermeability factors produced in the retina. Vascular occlusion induces the expression of vascular endothelial growth factor (VEGF) and interleukin-6 (IL-6), resulting in BRB breakdown and increased vascular permeability.²¹ ME is closely associated with retinal hypoxia, and the degree of hypoxia in macula center corresponds to the decrease in visual acuity (VA).⁸

INV and ANV are modulated by growth factors released from the ischemic retina and such appropriate inner retinal ischemic lesions have been found. VEGF has been implicated to participate in the development of neovascular complications from CRVO. In a study with enucleated eyes suffering from CRVO and neovascular glaucoma, intraretinal VEGF production from areas of ischemic retina was already demonstrated. VEGF aqueous levels increase prior to the development of INV and increase with the regression of INV after panretinal laser photocoagulation (PRP).^{22,23}

Clinical evaluation (Table 2)

General medical evaluation, which includes both medical history and physical examination including blood pressure evaluation, may be performed.³ An ocular history will determine the onset of the retinal occlusion, although individuals may not have noted the vision loss if the fellow eye has maintained good visual acuity.⁷ A history of systemic diseases, such as SAH, DM, and heart disease, and a personal or family history of thrombosis or hypercoagulable state should be also determined.⁷

Complete ophthalmic examination should be performed on both eyes and should include visual acuity, papillary reaction, and intraocular pressure. Undilated slit lamp examination is performed to detect INV and/or ANV.⁷ Abnormal iris stromal vessels may be confused for INV. However, comparison with the fellow eye may help to differentiate abnormal iris vessels. Undilated gonioscopy examination is essential to determine the presence of ANV or the evidence of angle closure from peripheral anterior synechiae, as ANV may be present even if INV did not coexist.²⁴

Ophthalmoscopic examination and fluorescein angiography will help to differentiate CRVO from other retinal occlusive diseases. ⁷

Table 2: Medical and Ophthalmic work-up for CRVO

| | |
|----|---|
| 1 | Complete medical history – Ocular history |
| 2 | Physical examination – (blood pressure evaluation) |
| 3 | Complete ophthalmic examination |
| 4 | Gonioscopy |
| 5 | Ophthalmoscopic examination – Fluorescein angiography |
| 6 | Complete blood count |
| 7 | Prothrombin time |
| 8 | Partial thromboplastin time |
| 9 | Erythrocyte sedimentation rate |
| 10 | Glucose tolerance test |
| 11 | Lipid profile |
| 12 | Serum protein electrophoresis |
| 13 | Chemistry profile |
| 14 | Syphilis serology |
| 15 | Antiphospholipids antibodies – Antinuclear antibodies |
| 16 | Protein C, Protein S and Homocysteine plasma level |

A systemic work-up is indicated in persons younger than 60 years old because these patients are more likely to have predisposing conditions resulting in CRVO, while it is not indicated in those older than 60 years with known systemic risk factors. A limited systemic work up may be considered in those with a prior occlusion in the fellow eye, prior systemic thrombotic disease, family thrombosis history, or other symptoms suggestive of a hematologic or rheumatologic condition. ^{7, 25}

Laboratory evaluation may include a complete blood count, prothrombin time, partial thromboplastin time, erythrocyte sedimentation rate, glucose tolerance test, lipid profile, serum protein electrophoresis, chemistry profile, and syphilis serology. Additional testing, based on the above findings, may be necessary. ³ If a history of a systemic clotting diathesis also exists, further hematological tests such as antiphospholipid antibodies (lupus anticoagulant level and anticardiolipin antibody), other antinuclear antibodies level, protein S and protein C levels and

fasting plasma homocysteine levels should be considered.³ An elevated plasma homocysteine level may uncover a suitable etiology of CRVO, which may also influence cardiovascular health.²⁶ Individuals with bilateral, simultaneous CRVO should have a detailed evaluation for a hypercoagulable condition, as these persons may be at a greater future risk for non-ocular thrombotic complications.⁷

Ocular manifestations

Ischemic and non-ischemic CRVO, have similar clinical findings, that are dilated tortuous retinal veins and retinal hemorrhages in all four quadrants. The distinction between the two types of CRVO is based on the area of nonperfusion on fluorescein angiography and is very important, because it assists the prediction of the future risk of ocular neovascularization, identification of patients with poor visual prognosis, determination of the likelihood of spontaneous visual improvement, and decision on the follow-up intervals.³ Most investigators believe that both types of CRVO represent varying severity of the same underlying disease continuum, while others suggest that these are two distinct clinical entities with different pathogenesis. The ischemic variety is associated with concurrent, severe retinal arterial disease, while non-ischemic entity results from a thrombosis located behind the lamina cribrosa.³

Another variety is hemi-vein occlusion, a distinct clinical entity presenting as occlusion of only one trunk of the central retinal vein in the area of the anterior part of the optic nerve. Its pathogenesis is closely related to CRVO.⁸ Some mild CRVO in patients younger than 50 years are classified as papillophlebitis or optic disc vasculitis, which both suggest a benign course. An inflammatory optic neuritis or vasculitis is hypothesized to be the causative agent.³

Conclusions

CRVO typically arises when the central retinal vein is occluded posterior to or within the lamina cribrosa.^{1,2} The pathogenesis of CRVO is multifactor, although its precise pathogenesis remains obscure. CRVO may be explained by the occlusion of the main trunk of the central retinal vein by a thrombus in the central retinal vein occluding its lumen at, or just posterior to, the lamina cribrosa.¹⁷ Anatomic variations at the level of the lamina cribrosa may be responsible for the formation of retinal thrombus. Arteriosclerosis of the neighbouring central retinal artery, which is associated with several systemic disorders such as DM, SAH, carotid insufficiency, dyslipidemia, renal dysfunction and atherosclerotic cardiovascular disease, causes turbulent venous flow and venous endothelial damage and is often implicated too.³ Hemodynamic alterations may produce stagnant blood flow

and subsequent thrombus formation in the central retinal vein, including diminished blood flow, increased blood viscosity, and an altered lumen wall (Virchow's triad).⁷ Elevated hematocrit, homocysteine and fibrinogen level, increased blood viscosity, the presence of a lupus anticoagulant or another antiphospholipid antibody, presence of factor V Leiden, and deficiency in activated protein C along with an elevated erythrocyte sedimentation rate and antithrombin III levels may be associated with retinal venous disease, although whether they possess a direct role or if they act as co-factors remains speculative.^{18, 19}

References

1. O' Mahoney P, Wong D, Ray J. Retinal vein occlusion and traditional risk factors for atherosclerosis. *Arch Ophthalmol* 2008; 126:692-9.
2. Hayreh S. Prevalent misconceptions about acute retinal vascular occlusive disorders. *Prog Retin Eye Res* 2005; 24:493-519.
3. Morley M, Heier J. Venous Obstructive Disease of the Retina. In: Yanoff M, Duker J, Eds. *Ophthalmology* Mosby, 2009; 597-605
4. Hayreh S, Zimmerman B, McCarthy M, et al. Systemic diseases associated with various types of retinal vein occlusion. *Am J Ophthalmol*. 2001; 131:61-77
5. Cheung N, Klein R, Wang J et al. Traditional and novel cardiovascular risk factors for retinal vein occlusion: The multiethnic study of atherosclerosis. *IOVS* 2008; 49:4297-302
6. The Eye Disease Case-Control Study Group. Risk factors for central retinal vein occlusion. *Arch Ophthalmol* 1996; 114: 545-554.
7. Mruthyunjaya P, Fekrat S. Central Retinal Vein Occlusion. In: Ryan SJ, Schachat AP, Eds. *Retina* Mosby, St Louis, Missouri 2006; 3:1339-48.
8. Rehak J, Rehak M. Branch retinal vein occlusion: pathogenesis, visual prognosis, and treatment modalities. *Curr Eye Res* 2008; 33: 111-31.
9. Clouse L, Comp P. The regulation of hemostasis: The protein C system. *N. Eng J Med*. 1986; 314:1298-304.

10. Bertina R, Koeleman B, Koster T et al. Mutation in blood coagulation factor V associated with resistance to activated protein C. *Nature*. 1994; 369:64-7
11. Clarke R, Daly L, Robinson K. Hyperhomocysteinemia: An independent risk factor for vascular disease. *N Engl J Med*. 1991; 324:1149-55
12. Welch G, Loscalzo J. Homocysteine and atherothrombosis. *N Engl J Med*. 1998; 338:1142-50
13. Loewenstein A, Goldstein M, Winder A et al. Retinal vein occlusion associated with methylenetetrahydrofolate reductase mutation. *Ophthalmology*. 1999; 106:1817-20
14. Gutman F. Evaluation of a patient with central retinal vein occlusion. *Ophthalmology*. 1983; 90:481-3
15. Quinlan P, Elman M, Bhatt A, et al. The natural course of central retinal vein occlusion *Am J Ophthalmol* 1990; 110: 118-23
16. Rumelt S, Karatsas M, Pikkell J et al. Optic disc traction syndrome associated with central retinal vein occlusion. *Arch Ophthalmol* 2003; 121:1093-7.
17. Green W, Chan C, Hutchins G et al. Central retinal vein occlusions: a prospective histopathologic study of 29 eyes in 28 cases. *Retina* 1981; 1:27-55
18. Dhote R, Bachmeyer C, Orellou M et al. Central retinal vein thrombosis associated with resistance to activated protein C. *Am J Ophthalmol*. 1995; 120:388-9
19. Vine A. Hyperhomocysteinemia: a new risk factor for central retinal vein occlusion. *Trans Am Ophthalmol Soc*. 2000; 98: 453-503
20. Hayreh S Central retinal vein occlusion. *Ophthalmol Clin North Am*. 1998; 11:559-90.
21. Noma H, Minamoto A, Funatsu H et al. Intravitreal levels of vascular endothelial growth factor and interleukin-6 are correlated with macular edema in branch retinal vein occlusion. *Graefes Arch Clin Exp Ophthalmol*. 2006; 244:309-15
22. Pe'er J, Folberg R, Itin A et al. Vascular endothelial growth factor upregulation in human central retinal vein occlusion. *Ophthalmology* 1998; 105: 412-6

23. Boyd S, Zachary I, Chakravarthy U et al. Correlation of increased vascular endothelial growth factor with neovascularization and permeability in ischemic central vein occlusion. Arch Ophthalmol 2002; 120: 1644-50.
24. Browning D, Scott A, Peterson C et al. The risk of missing angle neovascularization by omitting screening gonioscopy in acute retinal vein occlusion Ophthalmology 1998; 105: 776-84.
25. Lahey J, Tunc M, Kearney J et al. Laboratory evaluation of hypercoagulable states in patients with central retinal vein occlusion who are less than 56 years of age. Ophthalmology 2002; 86:774-6.
26. Cahil M, Stinnett S, Fekrat S. Meta-analysis of plasma homocysteine, serum folate, serum vitamin B, and thermolabile MTHFR genotype as risk factors for retinal vascular occlusive disease. Am J Ophthalmol 2003; 136: 1136-50.

***Periklis Brazitikos, Anna Praidou, Sofia Androudi
University Eye Clinic, Thessaloniki, Greece***

Central retinal vein occlusion (CRVO) is an important cause of visual acuity loss in elderly population. Even though CRVO is a well-known retinal vascular disorder, its pathogenesis and management remains still controversial.

The Central Vein Occlusion Study has demonstrated that panretinal photocoagulation is effective in determining the regression of ocular neovascularisations secondary to ischemic CRVO, but it is not helpful for the treatment of macular edema. More recently, the SCORE Study has shown that the intravitreal injection of triamcinolone acetonide is superior to observation for treating vision loss associated with macular edema secondary to CRVO, and that the 1-mg dose has a safety profile superior to that of the 4-mg dose. Interesting results have been provided also by the Posurdex Study, which has indicated that intravitreal injection of dexamethasone is beneficial in reducing macular edema on OCT, and in improving visual acuity.

Another approach is based on the intravitreal administration of anti-VEGF drugs. Several case series have recently demonstrated good functional results through the repeated injections of both ranibizumab, and bevacizumab.

We can be now sure that we will be able to face the complications related to CRVO with greater hope in the near future.

Francesco Bandello
Department Ophthalmology
University Vita-Salute
Scientific Institute San Raffaele, Milano, Italy

Retinopathy of prematurity (ROP) is a disease that occurs in premature infants and affects the blood vessels of the developing retina. In term infants, the retina is fully developed and ROP can not occur.

ROP is mild and undergoes spontaneous regression with no visual sequelae in the majority of affected infants. However, it may progress to advanced ROP which can lead to severe visual impairment and even complete blindness due to retinal detachment. Recent advances in neonatology have increased the survival rate of very low birth weight infants which has led to an increased incidence of ROP.

1. INCIDENCE

Prospective studies have provided new information regarding the current incidence of ROP.

In the Multicenter Trial of Cryotherapy for Retinopathy of Prematurity (CRYO – ROP) which included infants with birth weights less than 1251g, overall 65,8% of the infants developed some degree of ROP: 81.6% of infants with birth weight less than 1000g and 90% of infants weighing below 750g.

In the CRYO –ROP study severe ROP occurred in 6% of infants weighing less than 1251g and if untreated 48% developed retinal detachment or other adverse structural outcomes not compatible with useful vision.

2. PATHOGENESIS

In infants, retinal vascular development begins at 16 weeks gestation with mesenchyme, the blood vessel precursor, growing from the disc to reach the ora serrata nasally at 8 months and temporally shortly after birth.

We now know that this growth of immature retinal vessels into the peripheral avascular retina is stimulated by vascular endothelial growth factor (VEGF). The amount of oxygen in the retinal tissue determines the amount of VEGF production. High tissue oxygen levels down - regulate VEGF production and stop vessel growth. If the infant's immature retina is exposed to high levels of supplementary oxygen, which the infant needs to survive, the resulting VEGF cessation will cause vasoconstriction, arrest of new vessel growth and eventually vaso-obliteration. This is phase I of ROP (hyperoxia-vaso-cessation). Over time, usually several weeks, the vessel loss that occurs in phase I along with systemic factors and increasing retinal metabolic demands cause a shift to a relative retina hypoxia. The hypoxia

stimulates the release of VEGF and other angiogenic factors leading to neovascularization. This is phase II ROP (hypoxia – neovascularization).

If the area of avascular retina is relatively small, physiologic VEGF levels are produced and normal vascularization of the avascular retina takes place. However, if the avascular retina is large, the levels of VEGF produced are also large, leading to neovascularization with arterial venous shunts at the border between the vascularized and avascular retina.

In addition to VEGF, other factors, some of them non oxygen-regulated such as insulin – like growth factor 1 (IGF -1) play important roles in the development of ROP.

3. ROP CLASSIFICATION

In 1984 a precise international classification was introduced.

This classification not only defines each stage of the disease but also takes under consideration its location and extent.

LOCATION

Zone I. The innermost inner zone extends from the optic disc to twice the disc-macula distance in all directions from the disc.

Zone II. Extends from the outer border of Zone I to the ora serrata nasally and to approximately the equator on the temporal side.

Zone III. Residual crescent anterior to Zone II.

STAGING THE DISEASE

Stage 1: Demarcation Line.

This is a fine thin line which demarcates the vascular from the avascular areas. This line, which is usually white, has no height and no thickness. There is recognizable abnormal branching or arcading of vessels leading up to it.

Stage 2: Neovascular Ridge

The line of stage I now has height and width and is called neovascular ridge. Its colour may change from white to pink and the new vessels seen posterior to it may appear more branched.

Stage 3: Ridge with Extraretinal Fibrovascular Proliferation

This fibrovascular tissue which runs with the posterior aspect of the ridge, can contract and cause retinal detachment.

Stage 4: Subtotal Retinal Detachment.

The retina is pulled anteriorly into the vitreous by the fibrovascular ridge.

Stage 4A: the fovea is not involved.

Stage 4B: the fovea is involved.

Stage 5: Total retinal detachment.

Plus Disease is defined as arteriolar tortuosity and venous engorgement of the posterior pole. The presence of a «plus disease» is an ominous sign.

4. TREATMENT

The majority of infants with ROP do not need treatment.

The CRYO – ROP study has shown that only 6% of infants with a birth weight less than 1251 g will be at risk of developing retinal detachment or other unfavorable outcomes.

The CRYO – ROP study also demonstrated the efficacy of peripheral retinal cryotherapy in reducing unfavorable outcomes in those at risk infants. Theories regarding the mechanism of action of cryotherapy have included the belief that ablation of ischemic retina reduces the formation of VEGF and other vasoformative substances and therefore the stimulus to neovascularization.

In the CRYO – ROP study the unfavorable structural outcomes were reduced from 48% in the untreated group to 27% in the treated group.

Subsequently laser photocoagulation has largely replaced cryotherapy as a treatment of choice for ROP. Laser has been shown in studies to be equally or more effective than cryotherapy, less inflammatory, easier to apply to posterior disease, and perhaps less likely to cause long term problems.

Most recently the Early Treatment for Retinopathy of Prematurity Randomized Trial redefined the indications for treatment of severe ROP.

Peripheral retinal ablation is now considered for any eye with:

- Zone I, any stage ROP with «plus disease».
- Zone I, stage 3 ROP with or without «plus disease».
- Zone II, stage 2 or 3 ROP with «plus disease».

Bibliography

1. The Committee for the Classification of Retinopathy of Prematurity. An international classification of retinopathy of prematurity. Arch Ophthalmol. 1984;102:1130-1134.
2. Cryotherapy for Retinopathy of Prematurity Cooperative Group. Multicenter Trial of Cryotherapy for Retinopathy of Prematurity. Three-month outcome. Arch Ophthalmol. 1990;108:195-204
3. Ng EY, Connolly BP et al. A comparison of laser photocoagulation with Cryotherapy for threshold retinopathy of prematurity at 10 years. Part 1. Visualfunction and structural outcome. Ophthalmology. 2002;109:928-935
4. ET-ROP Cooperative Group. Revised indications for the treatment of retinopathy of prematurity: results of the early treatment for ROP randomized trial. Arch Ophthalmol. 2003;121:1684-1694
5. American Academy of Pediatrics, Section on Ophthalmology, American Academy of Ophthalmology, American Association for Pediatric Ophthalmology and Strabismus. Screening examination of premature infants for retinopathy of premature infants for retinopathy of prematurity. Pediatrics. 2006;117(2):572-576
6. Smith L. Through the eyes of a child: Understanding retinopathy through ROP. The Friedenwald Lecture. Invest Ophthalmol Vis Sci. 2008;49:5177-5182

Georgia A. Chrousos, MD, Greece

Purpose: To present on the basis of recent literature current knowledge concerning to the pathogenesis and treatment of macular edema

Definition: Macular edema is an abnormal thickening of the macula associated with the accumulation of excess fluid in the extracellular space of the neurosensory retina.

- I. Macular edema- pathophysiologic mechanisms
 1. Increased vascular permeability
 - Inflammatory and vasopermeability factors
 - Leukocyte stasis
 - Loss of endothelial cells and pericytes
 - Congenital vascular incompetence (Coats disease)
 2. Increased blood flow
 - Increased intraluminal pressure
 - Vasodilatation
 - Increased blood volume
 3. Dysfunction of RPE barrier /pump
 4. Tractional stress
 - Anteroposterior vitreous traction (perifoveal vitreous detachment)
 - Epiretinal membrane
 5. Drug reactions
 6. Intraretinal fluid migration from optic nerve head abnormalities
- II. Macular edema – causes
 1. Inflammatory disorders
 - Intraocular surgery (Irvine-Gass syndrome)
 - Laser procedures
 - Uveitic syndromes
 2. Retinal vascular disease
 - Diabetic retinopathy
 - Radiation retinopathy
 - Retinal vein occlusion
 - Hypertensive retinopathy
 - Retinal arterial microaneurysm
 - Macular teleangiectasis (type 1)
 - Coats disease

- Idiopathic retinal vasculitis, aneurysms, neuroretinitis(IRVAN)
- 3. Choroidal vascular disease
 - Choroidal neovascularisation
- 4. Drug reactions
 - Prostaglandin analogs
 - Epinephrine
 - Nicotinic acid
 - Docetaxel, paclitaxel
 - Tamoxifen
 - Thiazolidinediones(glitazones)
- 5. Inherited retinal dystrophies
 - Retinitis pigmentosa
 - Autosomal dominant cystoid macular edema
- 6. Tractional maculopathies
 - Vitreomacular traction syndrome
 - Epiretinal membrane
 - Myopic traction maculopathy
- 7. Retinal detachment
 - Exudative
 - Rhegmatogenous
- 8. Intraocular tumors
 - Choroidal cavernous hemangioma
 - Retinal capillary angioma
 - Choroidal melanoma
- 9. Optic nerve head abnormalities
 - Cavitory disc anomalies (pit ,coloboma)
 - Diabetic papillopathy
 - Hypertensive papillopathy
 - Neuroretinitis
- 10. Idiopathic

III. Macular edema – treatment

1. Inflammatory disorders
 - Intraocular surgery- in eyes with high risk of developing CME (diabetic retinopathy, uveitis)- consider intravitreal triamcinolone injection at the time of surgery
 - laser procedures- the development of new or worsened macular edema – complication of panretinal photocoagulation(PRP) in diabetic retinopathy- focal laser photocoagulation prior to or concurrent with PRP, dividing of PRP into multiple sessions, consider intravitreal injection of an anti – VEGF agent or triamcinolone before or at the time of PRP

- pseudophakic and aphakic CME- – topical corticosteroid and nonsteroidal anti-inflammatory agents; uveitic CME- corticosteroid posterior or sub-Tenon injection, intravitreal or systemic delivery; severe uveitis with CME- consider steroid-sparing immunosuppressive drugs;
 - chronic noninfectious posterior uveitis- intraocular steroid sustained –delivery device(0.59 mg fluocinolone acetonide); uveitis with CME resistant to medical therapy– an intravitreal anti-VEGF therapy (bevacizumab); chronic CME with vitreous adhesions to anterior segment structures following complicated cataract surgery- vitrectomy
2. Retinal vascular disease
- Diabetic retinopathy- DME- focal or focal/grid laser photocoagulation; diffuse DME- medical control of hyperglycemia, systemic hypertension, hyperlipidemia; tractional DME- vitrectomy with peeling of posterior hyaloid; nontractional diffuse DME- repeated injections of intravitreal triamcinolone acetonide or sustained –release devices (triamcinolone, fluocinolone, dexamethasone), anti-VEGF agents (pegaptanib, ranibizumab, bevacizumab)
 - Radiation retinopathy- ME- focal laser photocoagulation, laser ablation of any irradiated extramacular target zone, intravitreal VEGF inhibition
 - Retinal vein occlusion- ME- in BRVO - grid laser treatment, intravitreal triamcinolone injection , sustained-release dexamethasone implant, intravitreal anti-VEGF agents(pegaptanib, ranibizumab, bevacizumab), laser-induced chorioretinal anastomosis, intravitreal tissue plasminogen activator(tPA) injection , arteriovenous sheathotomy, radial optic neurotomy, vitrectomy.
 - Retinal arterial macroaneurysm, retinal teleangiectasis, IRVAN syndrome- ME- laser photocoagulation
3. Choroidal neovascularization- ME- intravitreal anti-VEGF treatment(ranibizumab, bevacizumab)
4. Drug reactions- CME after topical prostaglandin analogs(latanoprost), epinephrine -discontinuing the drug; CME after systemic exposure: nicotinic acid(hypercholesterolemia treatment), docetaxel, paclitaxel (oncologic agents), tamoxifen (anti-estrogen drug), pioglitazone, rosiglitazone(diabetes mellitus treatment)- stopping the drug.
5. Retinal dystrophies- CME in retinitis pigmentosa- oral or topical dorzolamide, intravitreal injection of triamcinolone acetonide in cases unresponsive to acetazolamide
6. Tractional maculopathies- CME- in vitreomacular traction syndrome, ERM, high myopia- vitrectomy with peeling of any tractional components
7. Retinal detachment- ME- scleral buckling or vitrectomy; CME in eyes with longstanding RD can persist after RD repair

8. Intraocular tumors- CME in choroidal hemangioma, retinal capillary hemangioma- laser photocoagulation, photodynamic therapy, VEGF inhibition
9. Optic nerve head abnormalities- (optic pit, optic nerve coloboma, morning glory disc anomaly)- ME- laser, vitrectomy, gas tamponade.

Conclusion

Macular edema occurs in a large number of pathologic conditions and has a medical and socioeconomic importance. Laser photocoagulation remains the treatment of choice for macular edema with nondiffuse pattern of vasculare leakage. In macular edema with diffuse pattern of vasculare leakage, different pharmacologic agents can reduce edema and improve visual function. Vitrectomy is often an effective treatment in macular edema associated with tractional maculopathies. The long term-efficacy and safety of new drugs and surgical procedures of the macular edema treatment should be established in large, randomized clinical trials.

References

1. Johnson MW. Etiology and treatment of macular edema. Am J Ophthalmol 2009; 147: 11-21.
2. 2Basic and Clinical Science Course. Section 12. Retina and vitreous. 2009-2010.
3. Saxena S. Focus on macular diseases. Jaypee Brothers Medical Publishers Ltd, New Dehli, India 2007.
4. Catier A et al. Characterization of macular edema from various etiologies by optical coherence tomography. Am J Ophthalmol 2005; 140:200-206.
5. Rothova A. Inflammatory cystoid macular edema. Curr Opin Ophthalmol 2007; 18:487-492.
6. Bhagat N et al. Diabetic macular edema: pathogenesis and treatment. Surv Ophthalmol 2009; 54:1-32.

7. Alm A et al. Side effects associated with prostaglandin analog therapy. *Surv Ophthalmol* 2008; 53:S93- S105.
8. Heckenlively et al. Association of antiretinal antibodies and cystoid macular edema in patients with retinitis pigmentosa. *Am J Ophthalmol* 1999; 127:565-573.
9. Johnson MW. Tractional cystoid macular edema: A subtle variant of the vitreomacular traction syndrome. *Am J Ophthalmol* 2005; 140:184-192.
10. Theodossiadis PG et al. Optical coherence tomography findings in the macula after treatment of rhegmatogenous retinal detachments with spare macula preoperatively. *Retina* 2003; 23:69-75.
11. Porrini G et al. Photodynamic therapy of circumscribed choroidal hemangioma. *Ophthalmology* 2003; 110:674-680.
12. Brodsky MC. Congenital optic disc anomalies. *Surv Ophthalmol* 1994; 39:89-112.

Wojciech Lubinski, Poland

17

Macular hole

Murat Oncel, Turkey

Text not received

Noninfectious retinopathy and HIV retinitis

Noninfectious retinopathy (non infectious retinal microvasculopathy) is the most common ocular manifestation of HIV/AIDS. Fifty to 70% of patients with AIDS have this condition.

Symptoms: Usually asymptomatic.

Signs: Cotton-wool spots (due to multiple nerve fiber layer infarcts), scattered intraretinal hemorrhages, microaneurysms. An ischemic maculopathy may occur with significant visual loss in 3% of patients.

CWS are not specific and are the same of those seen in diabetes mellitus. They consist of fluffy patches in the posterior pole, often located along the vessels.

Histopathology: swollen nerve fibers which result from disrupted axonal transport caused by ischemia. The etiology of this ischemia is probably multifactorial, including HIV infection of the endothelium of the retinal microvasculature, and deposition of circulating immunocomplexes.

HIV retinopathy can occur at any stage of the disease, but its frequency increases with the degree of immunodeficiency.

Isolated perivascular sheathing has been described in the absence of opportunistic retinal infections; etiology of this perivasculitis is unclear (mainly in African patients – children).

HIV has been isolated from the human retina and its antigen has been detected in retinal endothelial cells by immunohistochemistry. It is thought that such HIV endothelial infection and/or rheologic abnormalities such as increased leukocyte activation and rigidity may play a role in the development of cotton wool spots (CWS) and other vascular alterations.

CWS in AIDS: Although not directly vision threatening, these are considered to be a prelude to more serious ocular infections such as ARN (Acute Retinal Necrosis) or PORN (Progressive Outer Retinal Necrosis).

Treatment in cases of HIV retinopathy: antiretroviral agents; zidovudine and lamivudine, efavirenz and lopinavir + ritonavir.

HIV also may cause a peripheral multifocal retinitis with associated low-grade vitritis and retinal vasculitis. Patients must be evaluated for syphilis which may cause a similar clinical picture.

Unlike CMV, the lesions are stationary or progress very slowly and are not associated with retinal hemorrhage. Patient CD4+ count is usually > 120 cells/ μ l.

Large vessel occlusions are extremely unusual and they have been reported in association with viral retinitis, infiltrative lymphomatous optic neuropathy and as isolated abnormalities (AIDS-related hyperviscosity). An unusual frosted branch vasculitis has been associated with CMV retinitis in AIDS.

Work-up: HIV retinopathy is a marker of low CD4 + counts. Look for concomitant opportunistic infectious (i.e. Cytomegalovirus Retinitis). Rule out the other causes for unexplained cotton wool spots.

Cotton wool spots: Whitening in the superficial retinal nerve fiber layer (RNFL). The presence of a single cotton wool spot (CWS) in a patient without diabetes mellitus, acute hypertension or a central retinal vein occlusion (CRVO)/ branch retinal vein occlusion (BRVO) merits a work-up for an underlying systemic condition.

Dx. - Retinal whitening secondary to neuroretinitis such as that seen in toxoplasmosis, HSV, VZV and CMV (these entities typically have vitritis and retinal hemorrhages associated with them).

- Myelinated nerve fiber layer. (Usually peripapillary).

Other underlying causes of CWS:

Retinal emboli, collagen vascular disease (SLE, most common, Wegener's granulomatosis, polyarteritis nodosa, scleroderma), giant cell arteritis, infections (toxoplasmosis, Lyme, leptospirosis, subacute bacterial endocarditis, Rocky Mountain spotted fever, onchocerciasis), hypercoagulable state, radiation retinopathy, Interferon therapy, Purtscher and pseudo-Purtscher retinopathy, malignancy (metastatic carcinoma, leukemia, lymphoma), others (migraine, papillitis, sickle cell anemia etc.).

Laboratory investigations are essential to establish the diagnosis of HIV infection: demonstration of virus-specific antibodies by ELISA and Western blot, viral anti-

gen by enzyme immunoassay, direct isolation of HIV from the blood by culture, detection of HIV nucleic acid by PCR, or viral P24 antigen detection.

Posterior segment involvement by opportunistic infectious agents

Other infectious agents that can affect the posterior segment of the eye in patients with AIDS include CMV, HZV, *Toxoplasma gondii*, *Mycobacterium Tuberculosis*, *Cryptococcus neoformans*, *Pneumocystis carinis*, *Histoplasma capsulatum*, *Candida* spp.

Visual morbidity occurs particularly in cases of retinitis caused by CMV, HZV or *Toxoplasma gondii*.

CMV retinitis: yellow white retinal lesions with marked retinal opacification, hard exudates and intraretinal hemorrhages.

Diagnosis: Characteristic clinical appearance, PCR of aqueous humor, quantitative CMV PCR for blood (to assess systemic infection)

In the USA, 5 medications are currently approved for treatment of CMV retinitis:

- 1) Oral or intravenous ganciclovir,
- 2) Oral valganciclovir,
- 3) Intravenous foscarnet,
- 4) Ganciclovir via intraocular device,
- 5) Intravenous cidofovir.

Progressive outer retinal necrosis (PORN): PORN is usually caused by infection of outer retina and RPE, rare infection occurring mainly by HZV (or HSV), exclusively in AIDS patients. Differential diagnosis includes CMV retinitis and ARN. Intravitreal ganciclovir and/or foscarnet, also intravenous ganciclovir and/or foscarnet more effective than acyclovir.

Toxoplasma retinochoroiditis: In general, the size of the retinochoroidal lesion is larger in patients with AIDS. Solitary, multifocal and miliary patterns of retinitis. Preexisting scars are rarely seen in patients with AIDS. Dx: ARN or syphilitic retinitis (difficult to distinguish in AIDS patients). Anti-toxoplasmic therapy required, because the condition inevitably progress if left untreated.

Syphilitic chorioretinitis: 1) Uveitis, 2) Optic neuritis, 3) Non necrotizing retinitis (patients may present a dense vitritis).

Intravenous Penicillin G: main treatment. A classic manifestation of Syphilis in patients with AIDS is unilateral or bilateral pale yellow placoid retinal lesions that preferentially involve the macula (syphilitic posterior placoid chorioretinitis).

The effectiveness of HAART (Highly Active Anti-Retroviral Therapy) in restoring immune function in patients with AIDS has led to changes of the incidence, natural history, management and sequelae of HIV-associated retinopathies, especially CMV retinitis (decrease of incidence and severity).

In summary HIV-associated retinitis is characterized mainly by:

1. HIV retinopathy/retinitis
2. CMV retinitis
3. Necrotizing Herpetic Retinitis (ARN and PORN)
4. Toxoplasmosis
5. Syphilis
6. Immune recovery uveitis (IRU) diagnosed in 16-63% of HAART responders

Recommended literature

1. Tamara R. Vrabec. Posterior segment manifestation of HIV/AIDS. *Surv. Ophthalmol* 49: 131-157, 2004.
2. Goldberg DE, Smithen LM, Angelilli A. and Freeman WR. HIV-associated retinopathy in the HAART era. *Retina* 25: 633-649, 2005.

***Chris D. Kalogeropoulos, MD. PhD, FEBO
Assoc. Professor of Ophthalmology, University of Ioannina
Dept. of Ocular Inflammation Service***

Notes

Age related macular degeneration is the leading cause of blindness and visual disability and is responsible for 8.7% of all legal blindness worldwide.

The clinical hallmark and usually the first clinical finding of age-related macular degeneration is the presence of drusen. AMD can be classified into two broad clinical categories depending on whether there is a presence of abnormal neovascularization: neovascular (synonymous with exudative or wet) and dry AMD. A second classification is used depending on the extent of visual impairment; late AMD, which includes neovascular AMD and an advanced dry form called geographic atrophy and early AMD that includes all other forms. Early (dry) AMD is more prevalent than neovascular AMD in the UK and USA. However, patients with neovascular AMD account for 75% of cases of severe visual impairment secondary to AMD.

Several risk factors for the development and progression of age-related macular degeneration have been established, including advanced age, white race, heredity, a history of smoking, complement factor H, obesity, high dietary intake of vegetable fat and low dietary intake of antioxidants and zinc.

Large soft drusen are associated with a 6–7-fold increased risk of progression to advanced AMD. Large numbers of small hard drusen are also associated with progression to geographic atrophy. Once advanced age-related macular degeneration develops in one eye, there is a substantial chance (43%) of its development in the other eye within 5 years. The risk of legal blindness in both eyes for a person with unilateral visual loss from neovascular age-related macular degeneration may be approximately 12% over a period of 5 years. Although most people with advanced age-related macular degeneration do not become completely blind, visual loss often markedly reduces the quality of life and is associated with disability and clinical depression in up to one third of patients, even if only one eye is affected.

Diagnosis is put with the combination of history and clinical examination. Specific ophthalmic imaging techniques such as intravenous fluorescein angiography or indocyanine green angiography can augment clinical examination by identifying and characterizing choroidal neovascular lesions. Optical coherence tomography is noninvasive and can help elucidate retinal abnormalities by creating a cross-sectional image of the retina with the use of reflecting light rays. Since symptoms of age-related macular degeneration vary, each eye should be examined carefully

(with the other eye covered) by measuring visual acuity and by checking for subtle distortions on an Amsler grid, a square arrangement of vertical and horizontal lines that helps to assess a person's central visual field. Scotomas and visual distortions may be manifested as perceived breaks, waviness, or missing portions of the lines of the grid. Many patients are unaware of these subtle changes in vision, so periodic examinations by vitreoretinal specialists are of paramount importance to help detect neovascular age-related macular degeneration, since early identification and treatment can lead to better visual outcomes.

The current management includes anti-oxidant supplementation as well as lifestyle and dietary modifications for the dry disease. For the wet disease intravitreal antiangiogenic therapy is currently the primary therapy and has revolutionized the treatment offering stabilization or partial restore of the vision in big proportion of the patients. Ocular photodynamic therapy and thermal laser that used to be the treatment of choice since some years ago, are less popular today. Although big advances have happened during the last few years, age-related macular degeneration remains a blinding disease with no effective cure. In the future, approaches that involve the combination of agents or even the use of novel genetic treatments are expected to bring new alternatives that will help restore vision of patients with AMD.

Review papers

1. Jager RD, Mieler WF, Miller JW: Age related macular degeneration. N Eng J Med 2008;358:2606-17
2. Cook HL, Patel PJ, TufailA: Age-related macular degeneration: diagnosis and management. Brit Med Bul 2008; 85:127-149
3. Zhang N, Peng H: Emerging pharmacologic therapies for wet age-related macular degeneration. Ophthalmologica 2009;223:401-410
4. Ding X, Patel M, Chan CC: Molecular pathology of age-related macular degeneration. Prog Retin Eye Res. 2009; 28(1):1-18

Miltiadis K Tsilimbaris, MD, Greece

The main toxic retinopathy is the retinopathy induced by hydroxychloroquine (HCQ) and chloroquine (CQ) long term therapy. The second type includes all those induced by vigabatrin (VGB) long term therapy. These two retinopathies are difficult to avoid and each of them requires a special screening. The HCQ/CQ retinopathy is very rare but can result in blindness. The number of patients undergoing this therapy increases regularly and their cumulative dose received for each of them is also increasing and is reaching a more dangerous level. Although the VGB therapy more frequently induces retinal toxicity, the numbers of patients using it is very low, but the diseases for which this therapy is given are very severe and the screening very difficult. There are many others toxics that affect the retina such as methanol, quinine, tamoxifen, desferoxamin, retinoids, canthaxanthin, and iron originating from a metallic foreign body. This text will only be about HCQ/CQ retinal toxicity.

HCQ and CQ have been prescribed since the fifties for a large number of chronic auto-immune diseases such as rheumatoid arthritis, systemic lupus erythematosus, Gougerot-Sjögren syndrome, scleroderma etc., but the retinal toxicity is very rare. This retinopathy is bilateral, irreversible, without any treatment, and can induce definitive blindness. Since the first description of this toxicity ⁽¹⁾, all the authors agree that ophthalmological screening of patients under long term HCQ/CQ therapy is a necessity. The number of international publications on this subject is always very high and just for 2009 there were 8 ⁽²⁻⁹⁾ and another at beginning of 2010 ⁽¹⁰⁾. It appears that since 2000, the multifocal electroretinogram (mf ERG) testing seems to be the most sensitive method for detecting early changes due to HCQ/CQ retinal toxicity ^(4, 5, 11-18).

To better understand the actual ophthalmological screening of these patients, it is useful to define the two stages of toxicity identified for a patient undergoing HCQ/HQ long term treatment.

- « retinal toxicity » with clinical lesions directly viewed by ophthalmoscopy and or at the retinal angiography or with auto-fluorescence with the typical bull's eye maculopathy. This lesion leads to a severe visual loss acuity and to blindness
- « pre-clinical retinal toxicity » without any clinical signs, a normal fundus ophthalmoscopy, normal auto-fluorescence and normal angiography but

abnormal signs in the central visual fields and or abnormal mf ERG. At this stage, the toxicity can be reversed if the HCQ /CQ daily dosage is diminished or stopped. But if the treatment is continued, this stage goes to an irreversible toxicity.

It is why the screening is necessary to detect very early changes at the preclinical stage when the toxicity is still reversible.

For HCQ (Plaquenil®), each pill contains 200 mg of HCQ and the maximum daily dosage recommended to avoid retinal toxicity is 6.5 mg per kg lean body mass per day^(19,20) (which corresponds to 2 pills a day for a patient of 60 kg and 1m60).

For CQ (Nivaquine®), each pill contains 100 mg of CQ and the maximum daily dosage recommended to avoid retinal toxicity is 3 mg per kg lean body mass per day⁽¹⁹⁾ (which corresponds to 1 pill a day for a patient of 60 kg and 1m60).

In France today, for example, out of 60 million people, about 30 000 patients are undergoing HCQ or CQ long term therapy, more than 95 % of this group are undergoing Plaquenil® and less than 5 % are undergoing Nivaquine®⁽²¹⁾. The price of Plaquenil® is very low (0.18 euro one pill) compared with the others treatments and the side effects except the risk of retinal toxicity are small. It is the first choice therapy in these chronic inflammatory and/or auto-immunes diseases.

To determine the best screening ophthalmological protocol, it seems logical to understand the physiopathology of this very particular retinal toxicity and it would also be useful to know the exact pharmacology of these molecules.

1. The physiopathology of this retinal toxicity is not yet completely understood and the reason of an Bull's eye maculopathy with an annular scotoma around the 8 to 10 degrees of the central visual field which preserves at least at the beginning the foveola and the peripheral retina remains mysterious. It is well known that CQ/HCQ has a special affinity for melanin and that these molecules induce an alteration of the lysosomes particularly those located in the retinal pigmented epithelium and in the photoreceptors. The degenerative process begins in the ganglion cells but photoreceptors are the more damaged⁽²²⁾. Studies with OCT⁽²³⁾ have showed distinctive discontinuity of the perifoveal photoreceptor inner segment/outer segment junction and thinning of the outer nuclear layer were seen with the SD OCT in patients with mild retinal toxic effects. Moreover, retinal fundus auto-fluorescence (FAF) in patients under long term HCQ/CQ therapy detected early changes⁽¹⁶⁾ in the pigmented epithelium beginning with a fine pericentral ring of increase FAF. In

more advanced cases, the ring appeared broaden before just mottled and later on general loss of pigment epithelium was indicated by an absence of FAF. Results of FAF imaging correspond to retinal epithelium lipofuscin characteristics ⁽¹⁶⁾. For Kellner et al. ⁽¹⁶⁾, an increased FAF indicates accumulation of lipofuscin due to, for example, abnormal metabolism with increased phagocytosis of photoreceptor outer segments or an inherited or acquired defect of phagocytosis processes of the retinal pigment epithelial cells. Absence of FAF indicates photoreceptor or pigment epithelial cell loss. Korah et al. ⁽²⁴⁾ in 2008 has published a case of a patient with a CQ induced retinopathy where the optical coherence tomography (OCT) revealed anatomical evidence of loss of ganglion cell layers, causing marked thinning of the macula and parafoveal region. Turgut et al. ⁽³⁾ in 2008 also used OCT to show in an other case of HCQ retinal toxicity the photoreceptor loss, retina pigment epithelium (RPE) irregularities, and a cyst-like hypo reflective space over RPE layer on the nasal perifoveal region in one eye of this patient.

The question that then remains is why the region between 8 to 10 central degrees is the most sensitive to the retinal toxicity. The answer could be that there is an anatomo-physiological difference between the foveolar cones and the pericentral cones because the first detected change is a functional loss of these pericentral cones ⁽¹⁶⁾.

2. The pharmacology of HCQ/CQ is complex because the inter-individual variability of its intestinal absorption is very high (about 75 %), which explains why the HCQ blood level shows also a great inter-individual variability ⁽²⁵⁾. Fifty per cent of the absorbed HCQ is fixed on the blood proteins, mainly on albumin and on a α 1 glycoprotein. Synthesis of these proteins is genetically determined and explains why a certain number of patients can reach a cumulative dose of 4 kg (which is more twice the risk cumulative dose) of HCQ (after more than 20 years of a uninterrupted treatment of 400 mg per day) without any preclinical signs of toxicity and other patients develop a true retinal toxicity before 5 years of treatment ⁽²⁶⁾. The HCQ distribution volume is very significant; it describes the accumulation in the cells containing melanin and in the lysosomes. These different aspects have motivated the study of N. Costedoat-Chalumeau et al.'s study ⁽²⁴⁾ confirmed this large HCQ blood level inter-individual variability but they have also shown that the blood HCQ level is correlated neither to the weight nor to the lean body mass index

Taking into account the knowledge available, the current screening ophthalmological protocol proposed is the following:

1. Informing the patient: the prescribing physician has to inform his patient of the visual risks and of the necessity of regular ophthalmological follow-ups. This information must be clearly noted in the patient's file. The prescribing physician has to inform his patient that the aim of this follow-up is to avoid, as much as possible, the irreversible retinal toxicity. This follow-up consists of:
 1. Before initiating HCQ/CQ, or at least during the first 6 months of this treatment, a baseline examination with:
 1. a complete clinical ophthalmological exam with a very careful examination of the macula to detect any maculopathy existing previously to HCQ/CQ treatment.
 2. a central visual field (10 or 20 central degrees) examination and
 3. a mf ERG testing, if available
 2. During the treatment in a patient without any risk factor annually (and more often in patient with one or more risk factors)
 1. a complete clinical ophthalmological examination
 2. a comparative central visual field and
 3. a comparative mf ERG if available and strongly recommended after 5 years of treatment
 4. SD OCT recommended after 7 years of treatment with auto-fluorescence imaging

The frequency of follow-ups is determined by the existence of risk factors. A patient without any risk factor should be checked once a year. If there is one or more risk factors, the patient must be seen more often (twice a year for instance). There are 6 known risk factors:

- a high cumulative dose, higher than 1.8 kg (corresponding to an uninterrupted treatment of 2 pills per day over 12 years) ;
- a high daily dose, (larger than 6.5 mg HCQ per kg lean body weight per day or 3 mg CQ per kg lean body weight per day);
- ophthalmological diseases, particularly retinal problems
- renal and/or liver deficiencies
- elderly patients
- CQ treatment instead of HCQ

But we must stress that retinal toxicity could appear without any risk factors ^(16,26, 27).

The patient must be told that if he feels any new visual problem between two tests, for instance if he feels that reading becomes difficult, he must visit his ophthalmologist.

As for the electrophysiological test, it should be mentioned that it can objectively and quantitatively evaluate the retinal function and it can detect functional changes when the anatomical exams are still normal. The latest international publications have shown that the mf ERG is the most effective test for detecting early retinal changes but this test is not yet available everywhere, so comparative visual field tests must to be done at least once a year in all patients undergoing long term HCQ/CQ therapy. The follow-up should always be performed in the same centre to allow precise comparison of the results of each patient during the period of his treatment.

If by comparison of successive results a preclinical alteration continues, it must be asked whether the HCQ/CQ treatment should be diminished or to stopped all together. The pathology for which HCQ/CQ is prescribed is a main factor. Indeed, if it is for rheumatoid arthritis, for instance, there are a number of therapies now to treat this disease and HCQ/CQ could be relatively easily stopped but if the patient suffers from an erythematous Lupus, the strategy is completely different because it has been shown by several randomizes studies ^(25, 28) that HCQ/CQ therapy could diminish the number and the severity of the crisis so it is crucial to continue the treatment as long as possible. Lupus is a severe pathology, which can comprise the vital prognostic by inducing renal, cardiac or neurologic severe alterations; in these cases, it is better to maintain HCQ/CQ at lower doses with more frequent ophthalmological follow-ups. So, we emphasize that the decision as to whether or not to stop this medication should be made by the prescribing physician only after all the risks and benefits have been evaluated.

In case of a clinical intoxication, the treatment must be stopped immediately. The retinopathy could continue despite the interruption of the treatment, and if the treatment is not stopped the patient could become blind.

In France when a clinical intoxication is detected, it must be declared at a special departmental centre (centre de Pharmacovigilance).

In conclusion, in spite of the real constraint of the ophthalmological follow-up in patients undergoing long term HCQ/CQ therapy, the ratio benefit/risk is still much more in favour of this treatment for patients with chronic inflammatory and/or autoimmune diseases. We have to follow-up all the patients under this treatment at least once a year with a complete clinical ophthalmological examination, a central visual field and if available a mf ERG. As ophthalmologists, it is our responsibility to convince our prescribing colleagues of the risk of an irreversible retinal toxicity without any treatment and so of the necessity of a serious regular ophthalmological follow-up. The future will bring us a better knowledge of HCQ/CQ pharmacology, the discovery of the exact mechanism of the retinal toxicity, and a better determination for patients who have a high risk level and so follow-up more particularly these ones.

Finally, we have also to mention that in part because of the new means (mf ERG, SD-OCT, etc...), Professor M. Marmor of Stanford University (USA) was mandated by the American Academy of Ophthalmology to write new recommendations on screening for HCQ/CQ retinopathy but, in April 2010, they are not yet published but they should be available in the next few months.

References

1. Hobbs H.E., Sorsby A., Freedman A. Retinopathy following chloroquine therapy Lancet, 1959 : 2:478-80
2. Ingster-Moati I., C. Orssaud Protocole de surveillance ophtalmologique des patients traités par anti-paludéens de synthèse ou par vigabatrin au long cours J.Fr. d'Ophthalmologie, 2009,32,81-8
3. Turgut B, Turkcuoglu P, Serdar Koca S, Aydemir O. Detection of the regression on hydroxychloroquine retinopathy in optical coherence tomography. Clin Rheumatol. 2009 28 (5) :607-9.
4. Nebbioso M, Grenga R, Karavitis P. Early Detection of Macular Changes with Multifocal ERG in Patients on Antimalarial Drug Therapy. J Ocul Pharmacol Ther. 2009 25 (3) :249-58
5. Lyons JS, Severns ML. Using multifocal ERG ring ratios to detect and follow Plaquenil retinal toxicity: a review: Review of mf ERG ring ratios in Plaquenil toxicity. Doc Ophthalmol. 2009;118(1):29-36
6. Anderson C, Pahk P, Blaha GR, Spindel GP, Alster Y, Rafaeli O, Marx JL. Preferential Hyperacuity Perimetry to detect hydroxychloroquine retinal toxicity. Retina. 2009;29(8):1188-92.
7. Iuta JP, Rütther K. [Retinal damage by (hydroxy)chloroquine intake: published evidence for an efficient ophthalmological follow-up] Klin Monbl Augenheilkd. 2009;226(11):891-6
8. Chiffolleau A, Guillet A, Zanlonghi X, Jolliet P [Antimalarial's retinopathy remains a current threat], Presse Med. 2009;38(4):662-3

9. Stepien KE, Han DP, Schell J, Godara P, Rha J, Carroll J. Spectral-domain optical coherence tomography and adaptive optics may detect hydroxychloroquine retinal toxicity before symptomatic vision loss. *Trans Am Ophthalmol Soc.* 2009;107:28-33.
10. Pasadhika S, Fishman GA. Effects of chronic exposure to hydroxychloroquine or chloroquine on inner retinal structures. *Eye (Lond).* 2010;24(2):340-6
11. Kellner U, Kraus H, Foerster MH Multifocal ERG in chloroquine retinopathy: regional variance of retinal dysfunction. *Graefes Arch Clin Exp Ophthalmol* 2000;238(1): 94-7
12. Gilbert ME, Savino PJ Missing the Bull's Eye *Surv Ophthalmol*, 2007;52: 440-2
13. Moschos MN, Moschos MM, Apostolopoulos M, Mallias JA, Bouros C, Theodossiadis GP Assessing hydroxychloroquine toxicity by the multifocal ERG. *Doc Ophthalmol*, 2004;108:47-53
14. Maturi RK, Yu M, Weleber RG Multifocal electroretinographic evaluation of long-term hydroxychloroquine users. *Arch Ophthalmol*, 2004;122(7):973-81
15. Lai TYY, Chan WM, Li H., Lai RYK, Lam DSC Multifocal electroretinographic changes in patients receiving hydroxychloroquine therapy *Am J Ophthalmol*,2005;140,5 : 794-807
16. Kellner U., Renner AB, Tillack H Fundus Autofluorescence and mfERG for early detection of retinal alterations in patients using chloroquine/hydroxychloroquine *IOVS*,2006;47,8: 3531-8
17. Lyons JS, Severns ML Detection of early hydroxychloroquine retinal toxicity by ring ratio analysis of multifocal electroretinography *Am J Ophthalmol*, 2007;143(5):801-9
18. Chang WH, Katz BJ, Warner JE, Vitale AT, Creel D, Digre KB. A novel method for screening the multifocal electroretinogram in patients using hydroxychloroquine. *Retina.* 2008 ;28(10):1478-86
19. Bernstein, H. N. Ocular safety of hydroxychloroquine. *Ann Ophthalmol* 1991 23(8): 292-6.
20. Pautler SE Hydroxychloroquine dosages should be calculated using lean body mass. *Arch Ophthalmol* 2007;125(9):1303-4

21. Ingster-Moati I., Bui Quoc E., Crochet M., Orssaud C., Dufier JL, Roche O. Intoxication rétinienne sévère aux anti-paludéens de synthèse. J Fr Ophthalmol,2006;29,6: 642-50
22. Mahon GJ, Anderson HR, Gardiner TA, McFarlane S, Archer DB, Stitt AW Chloroquine causes lysosomal dysfunction in neural retina and RPE: implications for retinopathy Curr Eye Res 2004;28(4):277-84
23. Rodriguez-Padilla JA, Hedges TR, Monson B, Srinivasan V, Wojtkowski M, Reichel E, Duker JS, Schuman JS, Fujimoto JG High-Speed Ultra-high-resolution optical coherence tomography findings in hydroxychloroquine retinopathy Arch Ophthalmol, 2007;125:775-80
24. Korah S, Kuriakose T. Optical coherence tomography in a patient with chloroquine-induced maculopathy. Indian J Ophthalmol. 2008;56(6):511-3.
25. Costedoat-Chalumeau N, Amoura Z, Hulot JS, Lechat P, Piette JC Faut-il doser l'hydroxychloroquine chez les patients lupiques ? La Revue de Médecine Interne, 2006;27 :655-7
26. Bienfang DC Screening for hydroxychloroquine toxicity. Arch Ophthalmol,2007;125(11):1585
27. Maturi, R. K., J. C. Folk, B. Nichols, T.T. Oetting, R.H. Kardon. Hydroxychloroquine retinopathy. Arch Ophthalmol 1999; 117(9): 1262-3
28. The Canadian Hydroxychloroquine Study Group A randomized study of the effect of withdrawing hydroxychloroquine sulfate in systemic lupus erythematosus.. N Engl J Med. 1991;324(3):150-4.

Isabelle INGSTER-MOATI (MD,PhD)

1. University Paris 7 Diderot, Faculty of Medecine

2. Department of Ophthalmology, Hôpital Necker Assistance Publique-Hôpitaux de Paris,

3. INSERM U 669

Address: Department of Ophthalmology, Hôpital Necker 151 rue de Sèvres, 75015 Paris France

Email: isabelle.ingster-moati@nck.aphp.fr

Retinitis pigmentosa (RP) belongs to the group of pigmentary retinopathies, a generic name that covers all retinal dystrophies presented with a loss of photoreceptors and retinal pigment deposits. RP is a retinal degenerative disease characterized by pigment deposits predominant in the peripheral retina and by a relative sparing of the central retina. In most of the cases of RP, there is a primary degeneration of the photoreceptor rods, with secondary degeneration of cones. This sequence of photoreceptor involvement explains why patients initially present with night blindness, and only in the later life would suffer visual impairment in diurnal conditions.

Retinitis pigmentosa (RP) has a prevalence of about 1 in 4000. An estimated 1.5 million people are affected around the world. The highest frequency of occurrence of RP is among the Navajo Indians; 1:1878.

The main symptoms and signs of retinitis pigmentosa include night blindness, prolonged dark adaptation and difficulty with mid peripheral visual field in adolescence. As the condition progresses, they develop a tendency to blue blindness, lose far peripheral field, and eventually lose central vision as well. Patients can have a normal fundus appearance in the early stages. In more advanced stages, signs include attenuated retinal vessels, intraretinal pigment, and waxy pallor of the optic discs. The intraretinal pigment is distributed circumferentially around the mid periphery in the zone where rods normally are at maximum concentration.

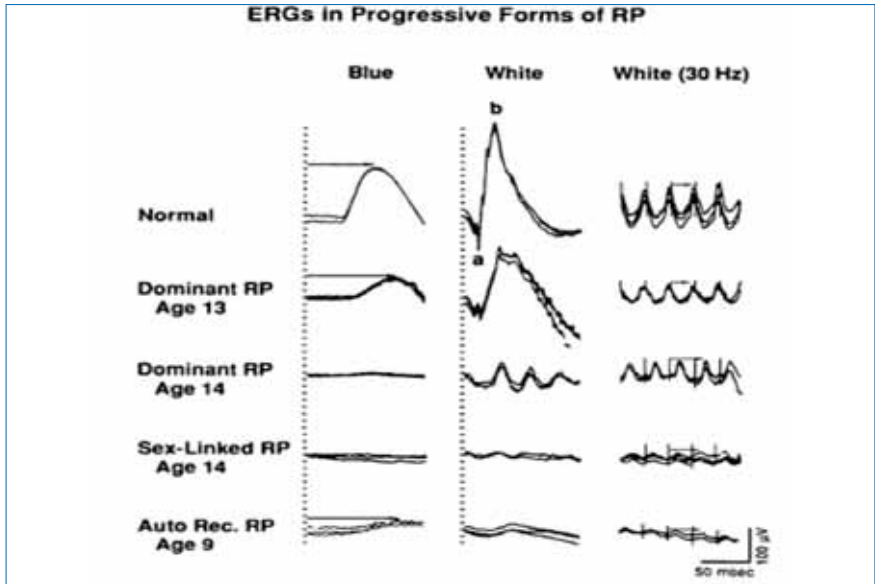
Diagnostic criteria

| Functional signs | Visual field | Fundus | Electroretinogram |
|--|--|--|--|
| Night blindness (nyctalopia) is the earliest symptom | Patchy losses of peripheral vision evolving to | Pigmentary deposits resembling bone spicules, initially in peripheral retina | Dramatic diminution in a- and b-wave's amplitudes – prolonged implicit times |
| Photophobia appears later | Ring shape scotoma, and eventually | Attenuation of the retinal vessels | Scotopic system (rods) predominates over photopic (cones) system |
| The visual acuity is preserved in early and mid stages | Tunnel vision | Waxy pallor of the optic disc | Unrecordable ERG in later stages |
| | | Various degrees of retinal atrophy | |

A tool now central to the diagnosis and classification of RP is the **electroretinogram** (ERG). In this procedure, photoreceptor cells are either dark adapted (scotopic ERG) or adapted to a specific level of light (photopic ERG), and then stimulated with a brief flash of light. In typical RP, the rod-cone disease manifests initially as alterations of the scotopic ERG and shows a proportional loss of the photoreceptor cell and post-photoreceptor components of the ERG.

Localization of the lesions. There are regional or sectorial forms in which only one or two quadrants are affected (RHO, PRPF31 mutations). The lesions may also be localized as a ring around the macula (pericentral), the optic disc (papillary) or predominantly along retinal veins (paravenous). In some cases, there is paraarteriolar retinal pigment epithelium preservation (CRB1 mutations). Finally, there are rare cases of unilateral RP for which a local cause (trauma) should be actively searched.

Retinitis pigmentosa presents great clinical as well as genetic heterogeneity.



ERG responses from a normal subject and from four patients (ages 13, 14, 14, and 9) with retinitis pigmentosa.

Mode of inheritance

Autosomal dominant forms are usually the mildest forms, with some cases starting after the age of 50, although severe disease can also appear.

Autosomal recessive forms start typically during the first decade, although some mild forms can be encountered.

X-linked forms also start early and are frequently associated with myopia.

Non-mendelian inheritance patterns, such as *digenic inheritance* and maternal (*mitochondrial*) inheritance, have been reported.

Simplex RP; cases with no family history (15-63%).

Syndromic RP

Many syndromes associate with various types of pigmentary retinopathies.

Usher syndrome is the most frequent syndromic form in which typical RP is associated with neurosensory deafness. Bardet-Biedl syndrome, Refsum syndromes, Batten disease, Kearns-Sayre syndrome, Abetalipoproteinemia (Bassen Kornzweig disease) are some other syndromes .

Complications

The most frequent complications are cataracts (posterior subcapsular) and macular edema. Phacoemulsification with implantation of intraocular lens and aceta-

zolamide sodium at a daily dose of 500 mg or less is required.

Treatment options

Vitamine A palmitate in high doses (15000 IU/day) has been shown to slow the rate of retinal degeneration but not to have any beneficial effect on functional vision (visual acuity, visual field). The safety of high dose vitamine A has also been questioned. Future treatment options may include gene therapy, the use of neurotrophic factors, retinal cell transplantation and use of neuroprosthetic devices.

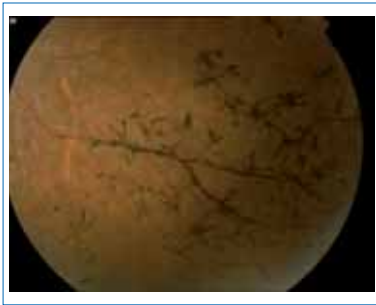

Fig 1: Paravenous pigment deposits in an RP patient fundus

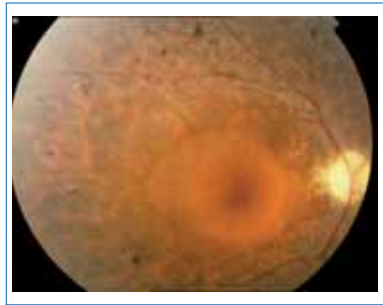


Fig 2: RP patient preserving relatively normal macular region

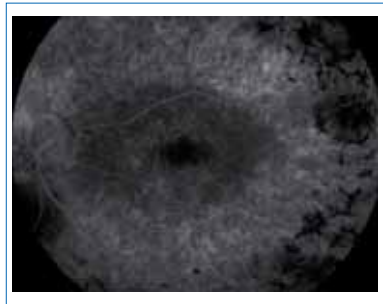
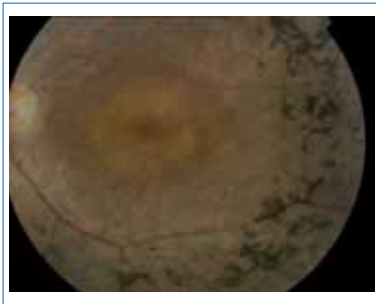


Fig 3,4: Fundus photo and fluorescein angiogram of a patient with typical RP

References

1. Berson EL, Retinis pigmentosa The Friedenwall Lecture 1659, Investigative Ophthalmology & Visual Science, April 1993, Vol.34, No.5
2. Orphanet Journal of Rare Diseases 2006, 1:40
3. Ronald E. Carr, John R. Heckenlively. Hereditary pigmentary degenerations of the Retina. In William Tasman MD; Edward A Jaeger MD Duane's clinical ophthalmology (1993) Vol 3, chap. 24.
4. Carlo Rivolta, Dror Sharon, Margaret M. DeAngelis and Thaddeus P. Dryja Retinitis pigmentosa and allied diseases: numerous diseases, genes, and inheritance patterns Human Molecular Genetics, 2002, Vol. 11, No. 10
5. Hartong DT, Berson EL, Dryja TP. Retinitis pigmentosa. Lancet. 2006 Nov 18;368(9549):1795-809.
6. Weleber RG, Gregory-Evans K (2006) .Retinitis pigmentosa and allied disorders. In Ryan, SJ (ed), Retina. Elsevier Mosby, pp 395-498.
7. Phelan JK, Bok D, A brief review of retinitis pigmentosa and the identified retinitis pigmentosa genes. Mol Vis. 2000 Jul 8;6:116-24.
8. Koenekoop RK, Lopez I, den Hollander AI, Allikmets R, Cremers FP. Genetic testing for retinal dystrophies and dysfunctions: benefits, dilemmas and solutions. Clin. Experiment Ophthalmol 2007 Jul;35(5):473-85.
9. Shintani K, Shechtman DL, Gurwood AS. Review and update: current treatment trends for patients with retinitis pigmentosa.

STEFANIOTOU MARIA

Ass. Prof. of Ophthalmology

University Eye Clinic of Ioannina, Greece

Stargardt disease (STGD), also known as **Fundus Flavimaculatus (FFM)**, a presumed primary dystrophy of the retinal pigment epithelium is by far the most common form of inherited juvenile-onset macular dystrophy, causing progressive vision loss usually to the point of legal blindness. In addition to the macular change, the autosomal recessively (approximately 90%) inherited retinal disorder is characterised by subretinal deposition of lipofuscin-like material of the peripheral retina.

Precise estimation of prevalence is not available. Based on the frequently cited incidence of one in 10 000, the disease belongs to the group of „*orphan (or rare) disorders*”.

History

The first description of the disease - characterised by bilateral atrophic appearing foveal lesions and decrease in central acuity- was given by Karl Stargardt in 1909. (Initial investigators preferred the term „Stargardt’s macular dystrophy”, later on Stargardt Disease – STGD - has been used.) As a variant of Stargardt’s macular dystrophy, *fundus flavimaculatus* was described by Franceschetti and Francois in 1965. The term was/is used for patients with yellow-white flecks throughout the fundus (with or without an atrophic foveal lesion).

Since the initial descriptions by Stargardt and Franceschetti, there has still been controversy in the literature as to whether STGD and FFM represent different clinical entities. There is currently no agreement on a clinical classification of this macular dystrophy; some authors have favored the concept of a single disorder, and others have tried to separate them based on clinical findings (e.g. electroretinograms, Fishman in 1976; Lois et al. in 2001).

Clinical course characterised by examination of

Visual acuity, Fundi and Colour vision

STGD typically begins in the first or second decade of life with variably decreased visual acuity. Both eyes are in general symmetrically affected, in boys and girls aequally. Usually there is a rapid decline in acuity during the teenage-years with final acuity of 20/200 to 20/400 by adulthood.

Initially, only subtle pigmentary mottling within the fovea may be apparent. Even with only minimal ophthalmoscopic changes, visual acuity may decrease to levels of 20/30 to 20/50. Later on foveal changes turn to atrophic, may have a beaten

metal (bronze) appearance and are associated with a ring or more extensive garland of yellow-white fundus flecks within the posterior pole and, to a lesser extent, the midperipheral retina. The fleck-like lesions may be round, linear or pisciform (fishtail-like). Although the central acuity is severely reduced, peripheral vision remains usually normal throughout life. The retinal damage often leads to an increase in sensitivity to light (photophobia) and delay of dark adaptation is also typical. Colour vision defect may be found mostly in advanced stages of the disease.

Electrophysiological examinations

While the *full-field ERG* is useful for discriminating the more localized pathology of STGD from widespread forms of retinal degenerations (e.g. CRD), it is of little value in the early detection of the disease and for following patients in longitudinal studies.

Responses are usually within the normal range in children with STGD. The cone- (30 Hz flicker) ERG typically lies toward the lower limit of normal, and the cone b-wave implicit time is usually longer than mean normal but still within the normal range. Older patients with extensive macular degeneration may show subnormal cone and rod amplitudes but the magnitude of loss is roughly predictable from the extent of macular degeneration.

An important characteristic of STGD is that cone b-wave implicit time remains borderline normal despite advanced disease. This is an important prognostic indicator, since patients who retaining normal or near normal b-wave implicit times are likely to retain useful peripheral function throughout life.

It is imperative, however, to allow at least 45 minutes for dark adaptation to appreciate fully the optimal potential for rod ERG amplitudes, since patients with STGD can take longer than normal to obtain maximally dark-adapted condition.

In evaluating the possible retinal basis for reduced acuity, it is necessary to obtain *multifocal ERG* which is capable for simultaneous geographic mapping of retinal function throughout the macula (but monitoring of „fixation” /fundus position/ is important while testing).

Pattern ERG (with usual and larger stimulus field) has also been examined.

Electrooculograms may be in the normal range or slightly affected in STGD.

Perimetry – Microperimetry may also be informative (but there are difficulties by fixation!)

Dark adaptation (DA):

After 30 minutes of dark adaptation following a photobleach, thresholds for normal subjects return to their prebleach values, while thresholds for the majority of patients with STGD (and CRD) remain elevated. Interestingly, delayed dark adaptation has also been reported in AMD.

Fluorescein angiography (FA) and fundus autofluorescence

A histopathologic report by Eagle (1980) demonstrated the presence of a lipofuscin-like material within all retinal pigment epithelial cells in a patient with fundus flavimaculatus.

The fundus flecks corresponded to retinal pigment epithelial cells that had undergone hypertrophy as a consequence of particularly extensive accumulation of the lipofuscin-like material that may block the choroidal fluorescence and explain the „dark choroid” reported by Fish et al (1981) in patients with Stargard’s macular dystrophy. Based on this phenomenon fundus autofluorescence is generally accepted as the most effective method for ascertaining STGD, in particular of the extent of the condition.

Scanning laser ophthalmoscopy (SLO)

The method is useful in detecting/measuring the amount of macular pigment, which is a predicting factor for visual acuity.

Optical coherence tomography (OCT)

OCT images correlate well with histologic cross sections of the retina in animal experiments. Both parameters of OCT, *foveal thickness(FT)* and *total macular volume (TMV)* are of diagnostic value in STGD and correspond with visual function.

Ultrahigh-resolution (UHR) – OCT is able to visualize and quantify trasverse photoreceptor loss, in particular focal loss and, make a more exact comparison to visual acuity.

Molecular genetic background and biochemical processes:

Mutations in the ABCA4 gene (expressed in rod and cone photoreceptors, mapped to the chromosome 1p13 – p21 interval) were identified as the cause of ***autosomal recessively inherited STGD***.

The protein encoded by the ABCA4 gene is called rim protein (RmP), because it was initially described in frog rod outer segment rims. RmP is a new member of the ATP-binding cassette (ABC) transporter superfamily.

RmP proved to be implicated in the transport of retinoid compaunds across the outer segment disc membrane following the photoactivation of rhodopsin. With missing or defective RmP, these materials accumulate within the intradiskal space with the consequences of delay in dark adaptation.

Variations of the gene lead to the increased accumulation of lipofuscin, comprised of a toxic component, the lipofuscin fluorophore, known as A2E, which can work as an initiator of blue-light induced apoptosis of RPE cells, causing secondary photoreceptor death.

Mutations in the ABCR4 gene are responsible for a variety of autosomal reces-

sively inherited degenerative retinal disorders (STGD, CRD, RP) and have also been suggested to predispose individuals to AMD.

Rare dominant forms of juvenile macular dystrophy with phenotypic similarity to STGD have been found to be related to mutations in ELOVL4, a gene that is believed to be involved in the long-chain fatty acid metabolism.

Therapeutical approaches

There is currently no effective treatment available for STGD – FFM.

After early-time diagnosis, low vision aids and implementation of an appropriate learning and working environment are important to help maintain the best possible level of function.

Current and future treatment options:

- Light protective glasses, Vitamins (but vitamin A supplementation only with care!)
- Drugs (in preclinical studies) inhibited the accumulation of lipofuscin in RPE
- Accurate genetic testing in each patient is important for the future gene-therapy
- Embryonic stem-cell implantation (forecasted to 2011-2012)
- Electric devices, artificial retinal microchips

References

1. Stargardt K: Über familiäre, progressive Degeneration in der Maculagegend des Auges. Albrecht von Graefes Arch Klin Exp Ophthalmol. 1909; 71:534-550.
2. Franceschetti A, Francois J: Fundus flavimaculatus. Arch Ophthalmol. 1965; 25:505-530.
3. Fishman G A: The electroretinogram in retinal disease, in Electrophysiologic Testing, ed. by Fishman GA and Sokol S, American Academy of Ophthalmology 1990 (pp. 44-46)
4. Allikmets R, Shing N et al.: A photoreceptor cell-specific ATP-binding transporter gene (ABCR) is mutated in recessive Stargardt macular dystrophy. Nat Genet. 1997; 15:236-246.

5. Molday LL, Rabin AR, Molday RS: ABCR expression in foveal cone photoreceptors and its role in Stargardt macular dystrophy. Nat Genet. 2000; 25:257-258.
6. Lois N, Holder G E et al.: Phenotypic subtypes of Stargardt Macular Dystrophy – Fundus Flavimaculatus. Arch Ophthalmol. 2001; 119:359-369.
7. Birch D: Stargardt Disease in Principles and Practice of Clinical Electrophysiology of Vision (second edition) ed. by John Heckenlively and Geoffrey B. Arden, The MIT Press 2006 (pp. 727-733)

Agnes Farkas MD., Ph.D.
Department of Ophthalmology (Maria str.)
Semmelweis University Budapest, Hungary

Pathophysiology

The term 'hypotony maculopathy' was first used by Don Gass in 1972 to describe loss of central vision occurring as a result of low intraocular pressure. Gass proposed that hypotony could cause the scleral wall to collapse inward, resulting in redundancy of the choroid and retina, leading to characteristic chorioretinal folds. The characteristic pattern of radial folds around the fovea probably occurs because the perifoveal retina is very thick whereas the foveal retina is much thinner. Defining hypotony maculopathy by a particular IOP threshold is often unhelpful as different eyes respond very differently to the same low levels of pressure. As an example, myopic eyes have a higher risk of hypotony maculopathy, probably as a result of reduced scleral rigidity, and young age and male sex are additional risk factors. In contrast, patients with low central corneal thickness have a lower risk of hypotony maculopathy.

Causes of hypotony maculopathy

Ocular trauma and glaucoma surgery are the two leading causes of hypotony maculopathy. There are a number of published reports that suggest that the rate is much higher when antiproliferative agents, particularly mitomycin C (MMC), are used at the time of glaucoma surgery. Rasheed (1999) compared the outcome of trabeculectomy with MMC in eyes with no previous ocular surgery to standard trabeculectomy without MMC. After a mean follow-up of 18 months, hypotony maculopathy developed in 3/25 eyes (12%) of the MMC group, and never in the no mitomycin C group. Tsai et al (2003) reported a hypotony rate of 20% when MMC was used in trabeculectomies performed on patients with juvenile primary open angle glaucoma compared to 0% when MMC was not used. It has been suggested that MMC may have a direct toxic effect on the ciliary body, resulting in reduced aqueous humour production. Hypotony is also more common following uveitic glaucoma surgery as aqueous production is often greatly reduced in these patients.

Avoiding hypotony maculopathy

Although hypotony has been associated with MMC use in the literature, in our experience the risk can be greatly reduced by relatively simple modifications to surgical technique. The most important tips are:

1. Treat a large area with MMC. Most thin, cystic blebs said to be associated with MMC use are probably due to treatment of too small an area with MMC leading to an aggressive scarring response in the penumbra of the treated region thus restricting aqueous flow and forcing the bleb to thin under pressure.
2. Avoid dissecting the scleral flap too close to the limbus. Anterior aqueous flow increases the risk of leak and hypotony
3. Ensure watertight closure of the conjunctiva at the limbus. This is essential to reduce the risk of hypotony in our experience.
4. Suture the scleral flap relatively tightly using releasable or adjustable sutures that can be manipulated in the early post-operative period.
5. Use an anterior chamber infusion during surgery so that the expected aqueous flow through the trabeculectomy at the desired intraocular pressure (controlled by the height of the infusion bottle) can be controlled.
6. Make sure uveitis is adequately controlled prior to glaucoma surgery and afterwards. We use intravenous methylprednisolone 2-3 hours pre-operatively which helps to prevent ciliary shutdown and subsequent hypotony in the post operative period.

Treating hypotony maculopathy

Successful treatment of hypotony maculopathy requires the cause to be identified and reversed before hypotony becomes persistent with the risk of permanent visual loss. It should be established whether the cause is leakage, over-drainage, poor aqueous production or a combination. This distinction may be obvious (eg wound leak) or less so (eg hypotony after uveitic glaucoma surgery may involve both relative over-drainage and reduced aqueous production). For early post-surgical hypotony we find that injection of viscoelastic into the anterior chamber can be both diagnostic and therapeutic. Diagnostically, an increasing pressure over the first few hours after viscoelastic injection proves good aqueous production. Conversely, if a pressure rise is not sustained despite good viscoelastic fill of the anterior chamber then it is likely, particularly in uveitic glaucoma, that aqueous production is poor and high dose systemic steroids can be helpful to increase aqueous production. Restricting aqueous flow temporarily by injecting viscoelastic to the anterior chamber can allow some helpful healing in cases of over-drainage. If hypotony persists due to over-drainage despite several injections of viscoelastic then sub-conjunctival injection of autologous blood and/or Palmberg bleb com-

pression sutures may be used. Palmberg (1996) suggested using 9–0 nylon sutures to limit the bleb in cases of over-filtration and we have found that combining this technique with sub-conjunctival autologous blood injection outside the bleb can increase the effectiveness of the technique. If this approach is not successful then re-suturing of the trabeculectomy flap is likely to be required, although this carries a high risk of subsequent trabeculectomy failure due to scarring.

Selected reading

1. Gass JD (1972): Hypotony maculopathy. In: Bellows JG Contemporary ophthalmology. Honoring Sir Stewart Duke-Elder. Baltimore: Williams & Wilkins 343–366.
2. Gass JD (1987): Folds of the choroid and retina. In: Gass JD (ed.) Stereoscopic atlas of macular diseases, 3rd edn. St. Louis: Mosby Company 221–234.
3. Haynes WL & Alward WL (1999): Combination of autologous blood injection and bleb compression sutures to treat hypotony maculopathy. J Glaucoma 8: 384–387.
4. Harizman N, Ben-Cnaan R, Goldenfeld M, Levkovitch-Verbin H & Melamed S (2005): Donor scleral patch for treating hypotony due to leaking and/or over-filtering blebs. J Glaucoma 14: 492–496.
5. Palmberg P & Zacchei A (1996): Compression sutures – a new treatment for leaking or painful filtering blebs. Invest Ophthalmol Vis Sci 37 (Suppl.): 444.
6. Tsai JC, Chang HW, Kao CN, Lai IC & Teng MC (2003): Trabeculectomy with mitomycin C versus trabeculectomy alone for juvenile primary open-angle glaucoma. Ophthalmologica 217: 2

***Keith Martin MA MD MRCP FRCOphth
Senior Lecturer and Consultant in Ophthalmology,
University of Cambridge, UK***

Abstract-Summary

Leber's Congenital Amaurosis (LCA) is a disease that was first described in 1869 by the German Ophthalmologist Theodor Karl Gustav von Leber (1840 -1917). It is rare (~1/80,000) inherited disease that presents at birth or in the first few months of life. It is characterized by severe vision loss or blindness, nystagmus, poor or absent pupillary responses, photophobia, hyperopia and eye poking or rubbing. The fundus appearance can exhibit significant variability and may appear normal early on but later it can acquire pigmentary changes reminiscent of retinitis pigmentosa. The Electroretinogram (ERG) is severely subnormal or non-existent. The disease is most often transmitted as autosomal recessive but instances of autosomal dominant exist. There have been at least 12 different genes associated with this disease. The two most well known genes are retinal guanylate cyclase (*GUCY2D*) and retinal pigment epitheliumspecific protein of 65kDa size (*RPE65*). Currently the only available treatment is supportive, although there is great excitement about new gene therapy treatments in the horizon. The recent Phase I/II human trial of Gene transfer in six patients with *RPE65* mutation reported no serious adverse effects and some minimal improvement in visual function supporting the need for further clinical trials on gene therapy.

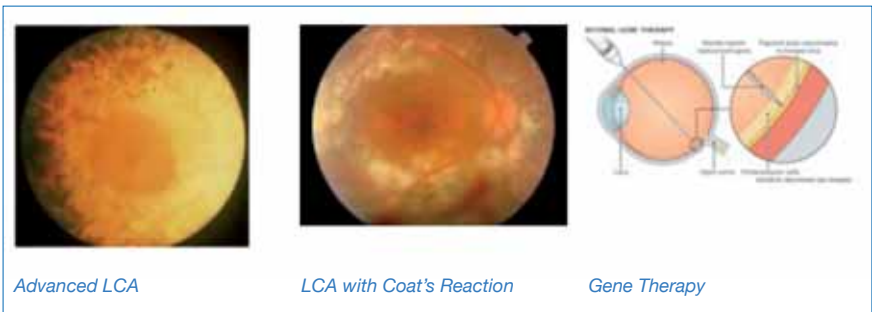
**Description and clinical features**

The German ophthalmologist Theodore Leber described this condition first in 1869 as a pigmentary retinopathy with congenital amaurosis and 2 years later he recognized the familial nature of this condition. It is thought to be transmitted as autosomal recessive condition most of the time, although cases of autosomal dominant transmission are known. Although rare (1/80,000) it is considered the most common genetic cause of congenital vision impairment in infants and

children. It consists 5% of all retinal dystrophies and 20% of children that attend school for the blind. The disease becomes evident at birth or shortly thereafter. The visual impairment is usually severe. Up to a third of the patients may have no light perception. Occasionally in the early stages a paradoxical visual improvement may be noted, likely due to maturation and development of the central visual pathways. Nystagmus and photophobia is usually present and the pupillary reaction is significantly reduced or absent. There is a characteristic oculo-digital sign (Franceschetti sign) with eye poking, pressing and rubbing. It is thought that this action is done so that the baby may experience some pressure related phosphenes. Some people believe that this behavior may predispose the child to the keratinous that is seen with this disease and to occasional enophthalmos from atrophy of the orbital fat. On clinical examination early on the retina may appear normal, however with time pigmentary changes may appear in the form of bone spicule or marbled fundus. Occasionally pseudo "macular colobomas" may be seen as a result of chorioretinal degeneration. The ERG is characteristically flat or severely diminished. Rarely developmental delay and mental retardation may be present. Carriers for this disease are usually asymptomatic, although some heterozygotes for the GUCY2D mutation may have mild dysfunction of the cone ERG signal but without any apparent vision interference.

Genetics

The disease is genotypical heterogeneous with at least 12 genes (GUCY2D LCA1), RPE65 (LCA2), SPATA7 (LCA3), AIPL1 (LCA4), LCA5 (LCA5), RPGRIP1 (LCA6), CRX (LCA7), CRB1 (LCA8), CEP290 (LCA10), IMPDH1 (LCA11), RD3 (LCA12), and RDH12 (LCA13) known to be associated with LCA. Together all these genes account for about 40-50% of all LCA. The two most well known are retinal guanylate cyclase (GUCY2D) and retinal pigment epithelium-specific protein of 65kDa size (RPE65). Each one of these two genes account for about 5-10% of LCA cases. Besides genetic heterogeneity of LCA, genetically related (allelic) disorders exists. That means that different mutations within each of the LCA-associated genes are known to cause other retinal dystrophies such as retinitis pigmentosa and cone-rod dystrophy.



Treatment

Currently there is no effective treatment for LCA. However there is significant excitement about gene therapy. Laboratory work in the naturally occurring Briard dog model of LCA that results from mutation in RPE65 has been encouraging enough that investigators proceeded with human testing. In the past few years two studies were published with the early phase I/II results in six humans subjects with LCA and RPE65 mutations. In both studies the gene for RPE65 was administered to patients with advanced diseases using an adeno-associated virus (AAV) vector into the subretinal space. They used AAV because it is considered to be non-infectious. No significant inflammation or other adverse events were observed in these two studies, although follow up was limited to less than a year. Some minimal improvement of various visual function tests were observed, although the studies were designed mainly as safety monitoring studies. The preliminary results from these investigations suggest that at least for the short term, the procedure of AAV gene transfer appears safe. The data suggest potential efficacy for this approach. All agree that more studies in the future are needed.

References

1. Leber. Über Retinitis pigmentosa und angeborene Amaurose. Graefe's Archive for Clinical and Experimental Ophthalmology (1869) vol. 15 (3) pp. 1-25
2. Bainbridge et al. Effect of gene therapy on visual function in Leber's congenital amaurosis. The New England Journal of Medicine (2008) vol. 358 (21) pp. 2231-9
3. Maguire et al. Safety and efficacy of gene transfer for Leber's congenital amaurosis. The New England Journal of Medicine (2008) vol. 358 (21) pp. 2240-8

4. Miller. Preliminary results of gene therapy for retinal degeneration. The New England Journal of Medicine (2008) vol. 358 (21) pp. 2282-4
5. Marlhens et al. Mutations in RPE65 cause Leber's congenital amaurosis. Nat Genet (1997) vol. 17 (2) pp. 139-41
6. Perrault et al. Retinal-specific guanylate cyclase gene mutations in Leber's congenital amaurosis. Nat Genet (1996) vol. 14 (4) pp. 461-4
7. Drack et al. From the laboratory to the clinic: molecular genetic testing in pediatric ophthalmology. American Journal of Ophthalmology (2010) vol. 149 (1) pp. 10-17
8. Lh riteau et al. Regulation of Retinal Function but Nonrescue of Vision in RPE65-deficient Dogs Treated With Doxycycline-regulatable AAV Vectors. Molecular therapy : the journal of the American Society of Gene Therapy (2010) pp.
9. Leber Congenital Amaurosis -- GeneReviews -- NCBI Bookshelf

Sotiris Gartaganis, Greece
Demetrios Vavvas, Greece
Department of Ophthalmology
School of Medicine,
University of Patras
26504 Patras, Greece
Tel: +302610999286
Fax: +302610993994

I. Introduction

Hereditary retinal degenerations are among the most common reasons for blindness, yet there is still no established therapy available. Remaining at the level of basic research for a long period, first steps have been made in recent years to take scientific results into clinical applications and first trials in humans. Anyhow, more preclinical research is still needed in most forms of retinal degeneration. Due to the variety of retinal degenerative diseases, each type is likely to need its own type of treatment. Depending on the state of the diseased retina, different therapeutical approaches are explored if the photoreceptor isn't capable of fulfilling its physiological function, conversion of light into an electrical signal. Living cells, either in the case of absence of ability to produce all needed proteins, or at an earlier stage of the cell degeneration in progressive degenerative diseases, are targets of therapies that enhance their function or prolong their life. Suitable approaches would be gene therapy and pharmaceutical therapies (neuroprotective therapies, visual cell modifiers or nutritional approaches) respectively. By contrast, if all photoreceptors are degenerated, possible treatment has to replace these cells (transplantation of mature photoreceptor cells or stem cells) or their function (optical photoswitches, prosthetic devices). Hence, the appropriate strategy has to be chosen depending on the type of the disease as well as their stage.

II. Treatment Strategies

A. Gene therapy

Mutated genes account for dysfunctional or missing proteins; therefore an obvious approach is to replace the defective gene with a normal copy of this gene. Once synthesis of the protein works, the function of the photoreceptor cell is restored - provided that the photoreceptor cell itself is alive. Replacement of genes in recessive disorders (loss of function) is more promising, as the removal of "toxic genes" in dominant diseases would be more complex. Of all organs, the eye is one of the most favourable for gene therapy. It has a small volume, so the required amount of vectors is relatively small, the transfection remains local and it is often affected by hereditary diseases. In animal models, gene therapy showed good results even in far progressed degenerations. Gene therapy was not only able to stop or slow down the degeneration, it also enhanced visual function. Animal models with mutations in RPE65, an isomerise in the visual cycle, or lebercillin gene are treated with gene therapy, showing positive ef-

fects over a long time period. First trials in humans started 2 years ago in patients with a mutation in RPE65 gene, which showed some restored visual function. Other gene therapy trials in humans are planned in Stargardt's disease, Usher syndrome, Retinosischisis and some forms of RP, since studies in animal models showed good results.

B. Pharmaceutical therapies

Neurotrophic factors

To prevent cell death of the photoreceptors, neurotrophic factors can be used to prolong their life. Examples would be CNTF (ciliary neurotrophic factor) or RdCVF (rod derived cone viability factor). To achieve a rescue effect, a sufficient amount over a longer period is needed. Cells producing neurotrophic factors are encapsulated in a semi-permeable material, letting the factors permeate while protecting the cells. The capsule is then implanted into the eye where the factors can reach the photoreceptors. Currently, Neurotech is running trials with CNTF in RP patients.

Visual Cell Modifiers

Visual cell modifiers intend to achieve replenishment of retinal, which is not synthesized properly by photoreceptors in some retinal diseases. A big advantage compared to other therapies is that the application is oral and therefore no injection or surgery is needed. Clinical trials are running in patients with some types of LCA. Preliminary results look promising.

Nutrition / antioxidant therapy

Despite the controversy regarding vitamin A therapy, nutrition has to be considered in prevention and slowing down retinal degenerations. Like visual cell modifiers, oral application is a beneficial noninvasive possibility for such treatments. Results in animal models of RP showed a reduction of the progression, a clinical trial is currently running in Spain.

C. Cell transplantation

Transplantation of adult photoreceptors

If photoreceptors are completely degenerated and gone, they have to be replaced. However, transplantation of adult photoreceptors of a donor eye showed that these cells although staying alive, do not sufficiently integrate into the host retina and therefore visual function shows no improvement. Animal studies showed only poor success, as did a trial in humans, where safety was reported good, but no validated study with significant improvement in visual function was reported so far. Further research with modified compounds or application regimens may turn out to be beneficial as reported in single cases.

Stem cell transplantation

A more promising strategy is to use stem cells instead of adult cells, capable of differentiating into several different cell types after implantation, e.g. retina cells like photoreceptors. Albeit this could work in theory, there is much basic work to be done before it will be possible to selectively force them to differentiate into the desired cell types. First success is reported by a company being able to produce retinal pigment epithelium cells from embryonic stem cells. However successful application in humans may be decades away.

D. Optical photoswitches

Another approach is to exploit other remaining cells in the retina to replace the function of the degenerated photoreceptors, i.e. to convert light stimuli into electrical signals. This is achieved by insertion of a photosensitive protein (i.e. photoswitch). This way, e.g. ganglion cells or bipolar cells, which remain alive e.g. in retinitis pigmentosa, can be made directly responsive to light and produce electrical signals. By principle, the achievable resolution would be limited, but basic light reception could be possible. Photosensitive proteins may be derived from several animal or plant cells, an example would be the protein “channel rhodopsin” from *Chlamydomonas* (a one celled algae). At the moment, this is still in an early stage of development and many issues have to be solved.

E. Electronic prosthetics

The visual pathway consists of 4 consecutively arranged neurons, and each one is a potential target for electronic prosthetics. While direct stimulation of the cortex (4th neuron) or the optic nerve (3rd neuron) have the advantage in completely bypassing the eye, they are at a very early stage of development and far from delivering satisfying results. More promising at the moment are prosthetics directly connected to the retina (1st and 2nd neuron). There are two different types, epiretinal and subretinal implants. Like the first two mentioned methods, epiretinal implants need a signal from an external camera. The captured image is processed and the signal is transferred to the implant (by wire or wireless), which stimulates the connected nerve cells or nerve fibers. Contrary, replacing only the photoreceptors with a subretinal implant is the simplest approach with the highest spatial resolution at the moment, as tested in the current clinical pilot trials. Exploiting the signal processing network of the remaining inner retina, almost no signal processing and no external camera is needed. The downside however is, that the inner retinal layers have to be intact for such subretinal implants, fortunately this is the case in many retinal degenerative diseases. Several trials are running at the moment with epiretinal and subretinal implants, showing good results regarding both

function (the best results of our group in Tübingen led to a visual acuity of about 20/1000 with capability of spelling words after many years of blindness) and bio-compatibility.

III. Conclusion

Fully effective restoration of visual function or prevention of functional losses in progressive hereditary retinal dystrophies is still future, but we are getting closer. More basic work has to be done for some of the approaches, like stem cell transplantation or photoswitches. Trials will show, if certain neurotrophic factor will prove effective for a larger group of heterogeneous retinal dystrophies, or if a mixture of several factors may be needed to achieve a significant effect. In cell culture, a combination of factors have proven to be very effective and several strategies are quite close to clinical application. Gene therapy looks promising as it shows restoration of visual function and long term positive effects, an will be tested in younger patients and more types of retinal degenerations. And, of course, electronic prosthetic implants show exciting results. In some completely blind patients, who were able to achieve reading ability. Long term biocompatibility trials are running, and general availability of some of the approaches can be expected within the next few years.

Acknowledgement:

Special thanks are due to Dr. Gerald Chader and Dr. Christoph Kernstock for discussion and preparation of this survey

Eberhart Zrenner
Center for Ophthalmology
University of Tuebingen, Germany

After 25 years from introduction by Hilton and Grizzard 1986 ⁽¹⁾ in the United States and Dominguez in Spain 1985 ⁽²⁾, pneumatic retinopexy (PR) has become an important surgical technique in the modern era of retinal surgical procedures for the repair of primary rhegmatogenous retinal detachments depending on the location and number of breaks, lattice degeneration, lens status and the patient's ability to cooperate. Basic surgical steps of this minimally invasive and low cost surgery for sealing the break and flattening a retinal detachment include: retinopexy of retinal breaks with cryotherapy or laser, intraocular gas injection before or after retinopexy, and maintenance of proper head posture by the patient for the required time period after surgery. With experience and better understanding of the proper retinal disease and basic principles of the procedure, the technique has evolved into a staged operation with many different variations of surgeons approaches providing the extension of indications.

From many excellent review articles and chapters which have been written on pneumatic retinopexy and personal experience, we find this technique as surgeons primary choice, much more popular as office-based procedure in the U.S. than in Europe. At least 60% of primary detachments in the United States appear to be managed in this fashion ⁽³⁾.

The purpose of this course is to outline the simplicity of the technique for urgent office-based pneumatic retinopexy, and provide an approach to variety of surgeon techniques and discuss importance of preoperative clinical examination and post-operative follow-up, selection of patients and advantage and disadvantage for extending indications.

Strategy and Principal Techniques

Prior to any surgical procedures, the surgeon must carefully identify all retinal breaks caused by the retinal detachment and devise the precise strategy for treatment: choice of gas, injection technique and manoeuvre to prevent subretinal fluid extension to the attached retina, paracentesis, retinopexy, ect. Small peripheral retinal breaks and clauded media are more appropriate for kryopexy oposite to laser application for treating postequatorial retinal breaks.

The optimal outcome for repairing the retinal detachment depends on three cardinal steps: 1) induction of retinopexy around all retinal breaks with cryopexy or laser; 2)

intraocular gas injection; and 3) consistent post operative head positioning for appropriate gas tamponade to achieve closure of the retinal breaks. The order in which these steps should be performed is up to the surgeon, considering the preoperative fundus findings and overall state of the patient. Before the surgery, it is crucial to make sure the patient understands the basic principles of the procedure and is willing to maintain a specific head position for five or more days for efficacy of pneumatic retinopexy. The patient is instructed to limit the physical activity including reading and watching television until the gas is absorbed, 7-10 days after the application.

Pneumatic retinopexy as one outpatient procedure is performed under topical anesthesia in sterile conditions in an examination office or in an operating room, using visual control by operating microscope or by binocular indirect ophthalmoscope. The proper preoperative disinfection of the eye, as well as postoperative application of, antibiotic corticosteroid and miotics is important to prevent endophthalmitis which occurs in less than 1% after pneumatic retinopexy ⁽⁴⁾.

The procedure may be performed as one or two step technique. First cryo and then the gas injection in the same act (one step) or gas injection first, followed by cryo or laser after a certain period of time (two steps). [The choice between these varieties of pneumatic retinopexy procedure is often based on the fundus findings and visibility of retinal breaks ^{\(5\)}.](#)

In my experience as the first step, 0.3-0.5 ml of gas, most commonly sulfur hexafluoride (SF₆), is administered using a 27 or 30-gauge needle and is injected through pars plana, superior surgical 12 o'clock position or temporal approach. Optionally, anterior chamber paracentesis is performed to prevent or to reduce the intraocular pressure. Intraocular pressure immediately after surgery may be slightly elevated (21-25 mmHg), it normalizes after subretinal liquid resorption and requires postoperative IOP control. Intraocular gas bubble of applied SF₆, for an emetropic eye doubles in size in 36 hours and covers 60 degrees of the retina surface and remains in the eye for 4-5 days, until it is completely absorbed after 7-10 days. On the second day, in flat retina, laser or cryo are applied to seal the break. [It could be a subject for discussion which procedure would be better for the best outcome, one or two step technique. Apply cryo to the detached retina before the gas injection in one step technique, or to the already flattened retina in two step procedure when the cryo might be less excessive.](#)

Recently, Tornambe ⁽⁶⁾, as one of the most experienced in pneumatic retinopexy, has evolved his technique in not extensive RD, introducing scatter photocoagulation as the first step. Laser is applied to attached retina between the posterior insertion of the vitreous base and the ora serrata, leaving a 1-clock-hour margin

between the border of the detached retina and the laser spots (laser indirect ophthalmoscope), to avoid potential new breaks. Cryopexy is then applied to detached retinal breaks if they are not highly elevated. 1 to 3 days after the gas injection, scatter laser photocoagulation is completed around 360° of the peripheral retina which improves the single-operation success rate by 5 to 10% which then approaches 97%.

Indications and Contraindications

Indications for pneumatic retinopexy are single or multiple superior retinal breaks (above the 4-9 o'clock line). Favorable conditions include phakic eyes, recent RD, no PVR. Negative prognostic factors include large retinal detachment, pseudophakia, hazy vitreous or lens and extensive lattice degeneration in myopic eyes. Uncomplicated pseudophakia is not a contraindication if the view is adequate ^(7,8).

Contraindications concerning the eye are inferior located breaks, break larger than one clock-hour, multiple breaks extending more than 3 clock-hours, significant traction on the retinal tears, glaucoma - risk of deterioration of VF, cloudy media - poor identification of the breaks, chronic primary RD. Pneumatic retinopexy is also contraindicated if patient is unable to maintain adequate position and will not follow instructions.

Advantages and Disadvantages

Advantages of PR compared to scleral buckling include shorter time of surgery, less inflammation, topical/local anaesthesia, office based surgery, better visual acuity and low cost. Complications described after scleral buckling such as anisomyopia (-2D), band intrusion/extrusion and ischemia are avoided. In terms of disadvantages, gas bubble may pull on the vitreous or retina what may result in bleeding and new tears also the subretinal fluid may shift to the macular area.

Results

The personal experience is concordant with published reports of success rate of pneumatic retinopexy in primary retinal detachment, shows updated average surgical outcomes with the single-operation of 74.4%, and final operation successes of 96.1% after additional treatment.

Cases of retinal detachment which I treated with PR presented the final anatomic and functional success rate of 85% just after single operation, and 95% with additional surgery. Final visual acuity was significantly better after PR than after scleral buckling procedure ^(9,10).

Conclusion





Pneumatic retinopexy has become an efficiently important low cost surgical procedure for indicated retinal detachment. Patient selection and proper surgical technique are both important for outcome. Careful examination of retina is crucial for decision whether to perform PR. Surgeons have to be able to follow up the patient postoperatively and if necessary be prepared to operate within few days if the procedure fails. Reoperation after failed PR do not reduce final visual acuity.

Literature

1. Dominguez DA. Cirugia precoz y ambulatoria del desprendimiento de retina. Arch Soc Esp Ottalmol. 1985;48:47-54.
2. Hilton GF, Grizzard WS. Pneumatic retinopexy. A two-step outpatient operation without conjunctival incision. Ophthalmology. 1986;93(5):626-641
3. D'Amico D J, Changing Surgica Approaches for Retinal Detachment. Retina Today .2006;12-14
4. Wirostko, W J. ; Han, D P. ; Perkins, S L. Complications of pneumatic retinopexy Cur Opin Ophthalmol 2000;11(3) : 195-200.
5. Conti S M,Kertes P J. An Approach to Pneumatic Retinopexy, Techniques in Ophthalmology: September 2007 - Volume 5 - Issue 3 - pp 107-120
6. Tornambe PE. Pneumatic retinopexy: the evolution of case selection and surgical technique. A twelve-year study of 302 eyes. Trans Am Ophthalmol Soc. 1997;95:551-578.
7. Tornambe PE, Hilton GF, The Pneumatic Retinopexy Study Group. Pneumatic retinopexy. A two-year follow-up study of the multicenter clinical trial comparing pneumatic retinopexy with scleral buckling. Ophthalmology. 1991;98:1115-1123.
8. Boker T, Schmitt C, Mougharbel M. Results and prognostic factors in pneumatic retinopexy. Ger J Ophthalmol. 1994;3(2):73-78.

9. Ambler JS, Meyers SM, Zegarra H, et al. Reoperations and visual results after failed pneumatic retinopexy. *Ophthalmology*. 1990;97:786-790.
10. Chan K C, Lin S G., Nuthi A. S.D. , Salib D M. Pneumatic Retinopexy for the Repair of Retinal Detachments: A Comprehensive Review (1986--2007) . *Surv Ophthalm* 2008; 53 (5): 443-478

Slobodanka Latinović MD,PhD
University Department of Ophthalmology,
Faculty of Medicine Novi Sad Serbia




LMU KLINIKUM
DER UNIVERSITÄT ERLANGEN
Erkrankung: Internistische Augenheilkunde
Direktor: Prof. Dr. Andreas Krieger

Pars plana vitrectomy for retinal detachment

C. Haritoglou

Indications

- Traction or media opacities
- Vitreous hemorrhage or opacities
- Tractive retinal detachment (PDR.....)
- Pronounced cataract formation: combined procedure
- Intraocular foreign body



Relative Indications

Pseudophakia

Unclear hole situation

Retinal breaks located centrally to the equator

Multiple breaks with variable location

Large tears, giant tears

Contraindications for buckle surgery (thin sclera, strabismus surgery, glaucoma surgery...)



Trend towards p-ppV for retinal detachment

Table 1 Operative type and demographic distribution of accepted patients undergoing surgery for primary rhegmatogenous retinal detachment in Tübingen (1997-2007, n=3241)

| Variable | Total, n (% of the cohort) | SR, n (% of SR total) | PPV, n (% of PPV total) | PPV plus SR, n (% of the total) |
|--------------------------------|-------------------------------|--------------------------|----------------------------|------------------------------------|
| Year | | | | |
| 1997 | 204 (6.3) | 131 (62.7) | 73 (35.6) | 43 (21.4) |
| 1998 | 274 (8.5) | 137 (49.7) | 137 (49.7) | 137 (49.7) |
| 1999 | 205 (6.3) | 107 (52.2) | 98 (47.8) | 70 (34.1) |
| 2000 | 249 (7.7) | 154 (61.9) | 95 (38.1) | 79 (31.7) |
| 2001 | 303 (9.3) | 134 (44.2) | 169 (55.8) | 132 (43.6) |
| 2002 | 306 (9.4) | 139 (45.4) | 167 (54.6) | 132 (43.1) |
| 2003 | 347 (10.7) | 132 (38.0) | 215 (62.0) | 86 (24.8) |
| 2004 | 329 (10.1) | 139 (42.2) | 190 (57.8) | 93 (28.3) |
| 2005 | 323 (9.9) | 171 (52.9) | 152 (47.1) | 82 (25.4) |
| Gender | | | | |
| Male | 1470 (45.3) | 502 (34.2) | 973 (65.8) | 374 (25.4) |
| Female | 1771 (54.7) | 974 (55.0) | 797 (45.0) | 324 (18.3) |
| Covered from ESCN (178) | 189 (5.5) | 138 (71.7) | 51 (26.3) | 69 (36.6) |
| Operated from day before (152) | 152 (4.7) | 62 (40.8) | 90 (59.2) | 74 (48.7) |

PPV = pars plana vitrectomy; SR = scleral buckling; PPV+SR = exchange rate to SR via UAE w/STDS

Ho et al., Eye 2008

Anatomic success




Figure 2 The rate of readmission within 180 days from the primary operation (SB: primary scleral buckling; PPV (no SB): primary pars plana vitrectomy without SB; PPV + SB: primary PPV combined with SB; Total: total cases).

Ho et al., Eye 2008

Why?

ppV: many indications

Technical developments (Endoillumination, viewing systems, PFCL, endodrainage, 23 g)

High intraoperative reattachment rate (Makula-off)

Low intraoperative complication rate (iatrogenic breaks, Lens-touch)

High primary success even in complex cases

Lower PVR rate (?)

p-ppv vs scleral buckling

Table 4 Comparative studies for retinal re-attachment surgery (prospective)

| Study | Number of cases | | Comment |
|----------------------------|------------------|-----|---|
| | Scleral buckling | PPV | |
| Tewari et al., 2003 [38] | 20 | 0 | Randomized, no vitreous breaks, equivalent SOGR (70% scleral buckling, 90% scleral buckling/PPV, $P=0.72$), equivalent visual results (median 20/120 scleral buckling, 20/200 scleral buckling/PPV, $P=0.4$) |
| Ahmedieh et al., 2005 [40] | 126 | 99 | Randomized, pseudophakic/phakic, equivalent SOGR (88% scleral buckling, 69% PPV, $P=0.24$), equal visual results (mean 20/182 scleral buckling, 20/182 PPV) |
| Stangos et al., 2004 [41] | 0 | 45 | Nonrandomized, pseudophakic, equivalent SOGR (89% PPV, 92% scleral buckling/PPV, no P value reported), equivalent visual results (improvement at least three lines in 69% PPV, 69% scleral buckling/PPV, no P value reported) |
| Sharma et al., 2006 [42] | 25 | 26 | Randomized, pseudophakic, equivalent SOGR (76% scleral buckling, 84% PPV, $P=0.48$), better visual outcome with PPV (20/105 scleral buckling, 20/71 PPV, $P=0.036$) |
| Diazikos et al., 2006 [43] | 75 | 75 | Randomized, pseudophakic, higher SOGR for PPV (83% scleral buckling, 94% PPV, $P=0.027$), equivalent visual results (20/50 scleral buckling, 20/43 PPV, $P=0.28$) |

PPV, pars plana vitrectomy; SOGR, single-operation success rate.

SPR – Study (416 phakic und 265 pseudophakic patients / 1 year fu)

Scleral Buckling versus Primary Vitrectomy in Rhegmatogenous Retinal Detachment

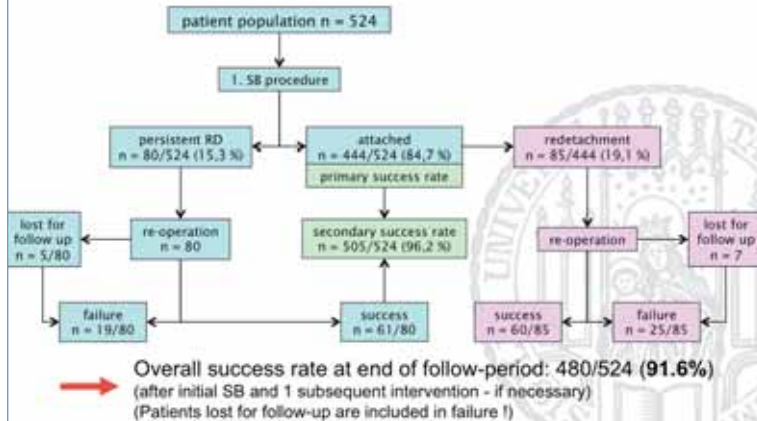
A Prospective Randomized Multicenter Clinical Study

Hans-Joachim Striemer, MD¹, Karl Ulrich Steyer-Jochims, MD², Mathias Bruch, MD³, Claude Wilm, MD⁴,
Raf-Dirac Villegas, MD⁵, Michael St. Francis, MD⁶ for the Scleral Buckling versus Primary Vitrectomy in
Rhegmatogenous Retinal Detachment Study Group¹

Scleral buckling in phakic eyes

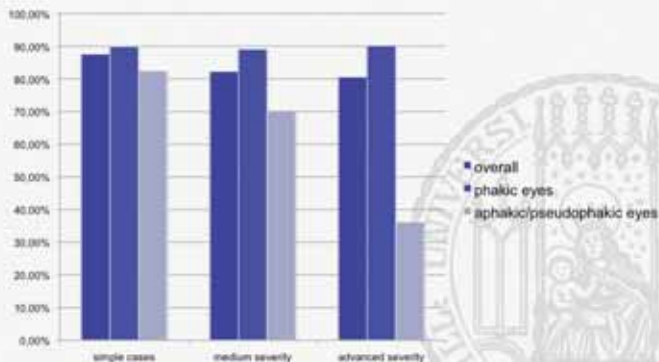
p-ppv in pseudophakic eyes

SB for RRD – analysis of 524 cases overall results:



SB for RRD – analysis of 524 cases

Summary of results:



SB for RRD – analysis of 524 cases

Discussion:

- Overall primary success rate is within reported range and independent from the learning curve of these surgeons
- Main factor influencing success rate is the status of the lens:
- success rate in phakic eyes
~ 90% irrespective of "severity"
- success rate in aphakic /pseudophakic eyes drops markedly with "severity"

SB for RRD – analysis of 524 cases

Discussion:

- the overall primary reattachment rate of the SPR-study is 63,6% in the phakic trial and is 53,4% in the pseudophakic/aphakic trial
- taking a similar cohort out of this series, the primary reattachment rate is 89,1% for phakic eyes and is 70,3 % for pseudophakic/aphakic eyes

SB for RRD – analysis of 524 cases

Conclusion:

- SB may still be considered the "gold standard" for simple and medium severe cases of RRD especially for phakic eyes and simple cases in pseudophakic eyes until a superiority of primary vitrectomy for these cases has been proven

SB for RRD – analysis of 524 cases

Conclusion:

- Appropriate training of scleral buckling surgery for RRD is still necessary and justified in view of the favorable results especially in phakic patients
- It appears worthwhile to save a clear lens by avoiding a primary vitrectomy in cases without primary PVR or "advanced" severity

SB for RRD – analysis of 524 cases

Conclusion:

- limitations of a retrospective study do apply for this cohort
- the strength of this analysis is the large number of patients and the defined training of surgeons as compared to multicenter studies including surgeons with differing experience

Current recommendation

Factors that need to be considered

Form, size and number of break

Lens status

Compliance of patient

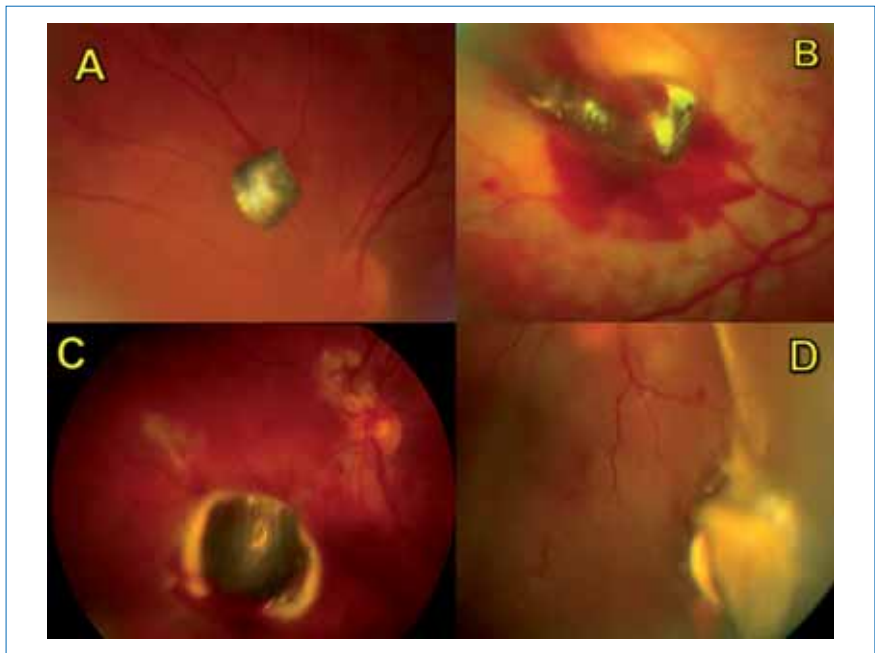Surgical experience



Individual decision !

A very important and challenging topic in ophthalmic traumatology is the management of intraocular foreign bodies (IOFBs). Studies have reported that an intraocular body may be present in 14% to 45% of cases of penetrating injuries of the globe¹.

Pars-plana vitrectomy is the recommended procedure for the removal of the IOFBs². Continued improvement in ocular microsurgery has enabled vitreoretinal surgeons to treat previously devastating injuries providing functional vision in many patients. There have been studies that have evaluated different preoperative, operative and postoperative variables for the visual prognostic value in cases with IOFBs.



A,B,C,D.: Four different cases of penetratic trauma with a metallic intraocular foreign body.

Diagnosis

It is very important for the clinical ophthalmologist to follow some rules in every case of an eye injury³. An IOFB must be ruled out when a penetrating or perforating

injury is even suspected. After visual acuity examination and clinical examination is completed (Slit lamp and indirect ophthalmoscopy, if this is possible), an x-ray must be performed even though, there is no strong history supporting the existence of an IOFB. A CT scan must follow as a routine to rule out the existence of an IOFB. Ultrasonography must be avoided when an eye globe is open ^{2,3}.

MRI could be performed only when there is a strong suspicion of an IOFB existence, and the x ray and the CT scan have excluded the presence of a metallic IOFB ³.

Material of the IOFBs

Metallic and organic IOFBs must be removed from the eye, while plastic or glass IOFBs are considered to be inactive, well tolerated, and can be left in place.

Iron or ferrous IOFBs, if they are not removed, oxidize in the eye and release ferric ions through the intraocular tissues, causing **siderosis** ^{2,3,4}, a very serious condition. The iron molecules are stored intracellularly causing damage to the cell membranes and inactivate useful cell enzymes. This condition leads to a progressive reduction of the electroretinogram values and finally blindness ².

Chalcosis ^{2,3,4} is associated with retained copper foreign bodies, which are extremely reactive, making this condition devastating and vision threatening. Acute chalcosis is caused by solid copper, while chronic chalcosis is caused by intraocular bodies made of copper alloyed with another metal, situation that is less urgent, but still very serious. Both conditions demand prompt removal of the IOFBs ².

Surgical procedure

Vitrectomy is the procedure of choice ^{2,3,4}. Endomagnet for magnetic IOFBs, or special forceps for not magnetic ones are being used for their removal.

Timing of removal

There is a lot of controversy on this issue. There are two broad schools regarding the timing of the removal of the IOFB ⁵. The early school claim that vitrectomy and removal of the IOFB at the day of presentation, or primary repair and vitrectomy as a second procedure for the removal of the IOFB within 3 days reduces the risk of endophthalmitis and proliferative vitreoretinopathy (PVR) ⁶. The late school points out that the second procedure is better to take place within 7-15 days after the primary repair, when the posterior vitreous detachment of the usually young patient's eye will often occur spontaneously making vitrectomy easier and safer, without

the intraoperative risk of causing retinal breaks, retinal detachment, choroidal and vitreous hemorrhage ^{7,8}.

Complications

The complications are the same with the complications of all the trauma cases, plus the intraoperative complications of the removal of the IOFB, or the complications of retained IOFBs, such as inflammation, endophthalmitis, siderosis or chalcosis.

Incidence of endophthalmitis

The existence of an IOFB in a trauma case increases the risk of endophthalmitis to 7%-15%. When the IOFB is organic the risk of endophthalmitis rises up to 25%-30%.

Visual prognosis

The postoperative visual prognosis depends on the preoperative visual acuity, the existence of retinal detachment, endophthalmitis or other complications ^{1,7,9}. The postoperative visual acuity in 50% of the cases can be 20/40 or better, in 30% of the cases is less than 20/200, while 20% of the cases have visual acuity of hand motions or worse ^{1,3,7}.

References

1. Vivek B.W. Mubarak A.A. Lukman T. et al. Vitrectomy for posterior segment intraocular foreign bodies. Visual results and prognostic factors. *Retina* 2003; 23:654-660.
2. Peyman G.A., Schulman J.A., (1986) Trauma, Penetrating Ocular Injuries in: Peyman G.A., Schulman J.A., *Intravitreal Surgery. Principles and Practice* Appleton-Century-Crofts Norwalk Connecticut, 260-278.
3. Paul Sternberg (1994) Trauma principles and Techniques of Treatment in: Ryan S. J., *Retina, Volume 3: Glaser B.M., Surgical Retina 2nd Edition* , The Moby Co St Louis, 148:2351-2378
4. Federman J.L., Gouras P. et al (1994) Trauma, in: Podos S., Yanoff M., *Textbook of Ophthalmology, Retina and Vitreous, The Mosby Co, London, Vol 9, 15:6-11.*

5. Aylward GW, Vitreous management in penetrating trauma: primary repair and secondary intervention, *Eye* 2008;22:1366-1369.
6. Jonas JB, Budde WM., Early versus late removal of retained intraocular foreign bodies, *Retina* 1999;19:193-197.
7. Colyer M.H., Weber E.D., Weichel E.D. et al. Delayed intraocular foreign body removal without endophthalmitis during operations Iraqi freedom and enduring freedom. *Ophthalmology* 2007;114:1439-1447.
8. Ferrari T.M., Cardascia, N, Di Gesù I. et al., Early versus late removal of retained intraocular foreign bodies (Correspondence), *Retina* 2001; 21:1, 92.
9. Jonas JB, Knorr HL, Budde WM., Prognostic factors in ocular injuries caused by intraocular or retrobulbar foreign bodies. *Ophthalmology* 200;107:823-828.

Chryssanthi Koutsandrea, MD, Greece.

Epiretinal membrane (ERM) is the result of fibroglial proliferation on the surface of the retina ⁽¹⁻³⁾. It may occur as a primary idiopathic disorder of the posterior pole independently of specific disease processes other than posterior vitreous detachment ⁽⁴⁻⁷⁾ or it can be associated with a variety of ocular diseases ^(8,9). The prevalence of idiopathic epiretinal membrane (IERM) ranges from 7.1% to 10.3% in the age group from 60 to 80 years old ⁽¹⁰⁾. Idiopathic epiretinal membrane, when it happens, affects one or both eyes of subjects over 50 years of age and both sexes are equally affected. Some reports showed a higher prevalence of IERM in female subjects but this did not reach statistical significance ⁽¹¹⁾. The IERM may have a translucent or semitranslucent fibroglial appearance or may be thick and opaque (macular pucker) with visual dysfunction varying from mild to severe ⁽¹²⁾. Eyes with thin IERM commonly maintain 20/50 visual acuity, while in cases with macular pucker the visual acuity is usually significantly affected and approaches the level of 20/200 ^(7,13).

The diagnosis of IERM or ERM has been mainly based on clinical appearance, biomicroscopy, fundus photography, fluorescein angiography ^(4,7,13) and optical coherence tomography (OCT). So far optical coherence tomography (OCT) has been used to describe the characteristics of the IERM ⁽¹⁴⁾ or to study the structure and function of the macula before and after surgical intervention for the removal of the epiretinal macular membrane ⁽¹⁵⁻¹⁷⁾.

OCT is a noninvasive, noncontact imaging instrument, which is capable of producing high resolution cross sectional images of the retina ⁽¹⁸⁻²⁰⁾. The technique contributed to the study of many retinal disorders and it has been extensively used in the quantitative assessment of macular edema ⁽²¹⁻²⁴⁾.

The clinical characteristics of the IEMM vary according to the degree of the membrane. D. Gass has proposed a classification scheme for epiretinal membranes.

Translucent membranes unassociated with retinal distortion are grade 0 (cellophane maculopathy). Membranes that cause irregular wrinkling of the inner retina are grade 1 (crinkled cellophane maculopathy). Opaque membranes that cause obscuration of the underlying vessels and marked full-thickness retinal distortion are grade 2 (macular pucker).

An asymptomatic patient may have a glinting, irregular light reflex caused by a subtle epiretinal membrane. These “cellophane membranes” usually do not have a distinct edge.

If the translucent membrane is more apparent, it can appear to cover the entire macula and even extend anteriorly beyond the vascular arcades.

However, the membrane can extend beyond the area of retinal striae.

In more severe and visually debilitating epiretinal membranes, vascular tortuosity can occur. If the membrane is centered distal to the macula, foveal ectopia can occur that causes complaints of diplopia.

Occasionally, the epiretinal membrane lifts the sensory fovea off the retinal pigment epithelium in a subtle, shallow, tabletop manner. Cystoid macular edema may be present. Studies have shown an especially high incidence (75 to 93%) of posterior vitreous detachment in cases where epiretinal membrane is present.

Evolution of IEMM in cases which were not operated have shown an increase of 10.4% in the central foveolar point, ranging from a mean $311+84.3$ (+SD) μm at baseline to a mean $343.1+95.1$ (+SD) μm at the final examination as recent studies have shown ⁽²⁵⁾. The measurements in this study were mainly based on the increase of the foveal thickness in the 1mm diameter central area, which is considered to be potentially more reliable ⁽²⁷⁾.

In non operated cases OCT examination added some new information, which is related to the morphologic macular changes such as abolition of the foveal pit changing pattern of the preexisting macular edema and intraretinal cystic spaces.

During the follow-up period automatic separation of the IERM from the retinal surface rarely can occur. It is considered that the presence and increase of macular edema during follow-up is an important factor in deciding whether to operate on a patient with IERM (39). Surgery has been advocated for IERM cases with VA 20/60 or worse ⁽⁴⁰⁻⁴⁵⁾ or with VA 20/50 or better ⁽⁴⁶⁾.

References

1. Michels RG. A clinical and histopathologic study of epiretinal membranes affecting the macula and removed by vitreous surgery. *Trans Am Ophthalmol Soc* 1982; 80:580-656
3. Trese MT, Chandler DB, Machemer R. Macular pucker. I. Prognostic criteria. *Graefes Arch Clin Exp Ophthalmol* 1983; 221: 12-5
4. Fine SL. Idiopathic preretinal macular fibrosis. *Int Ophthalmol Clin* 1977; 17: 183-9
7. Wise GN. Clinical features of idiopathic preretinal macular fibrosis. Schoenberg Lecture. *Am J Ophthalmol* 1975; 79: 349-7
8. Appiah AP, Hirose T. Secondary causes of premacular fibrosis. *Ophthalmology* 1989; 96:389-92
9. Theodossiadis GP, Kokolakis SN. Macular pigment deposits in rhegmatogenous retinal detachment. *Br J Ophthalmol* 1979; 63: 498-506
10. Mitchell P, Smith W, Chey T, et al. Pprevalence and associations of epiretinal membranes. The Blue Mountains Eye Study, Australia. *Ophthalmology* 1997; 104: 1033-40
11. Frasser-Bell S, Guzowski M, Rochtchina E et al. Five year cumulative incidence and progression of epiretinal membranes: the Blue Mountains Eye Study. *Ophthalmology* 2003; 110: 34-40
12. Gass JDM. Macular dysfunction caused by epiretinal membrane contraction. In: Gass JDM, ed *Stereoscopic Atlas of Macular Diseases, Diagnosis and Treatment* (4 th ed.) St Louis Mosby, 1987; 938-45
13. Wiznia RA. Natural history of idiopathic preretinal macular fibrosis. *Am Ophthalmol* 1982; 14: 876-8
14. Wilkins JR, Puliafito CA, Hee MR, et al. Characterization of epiretinal membranes using optical coherence tomography. *Ophthalmology* 1996; 103: 2142-51

15. Azzolini C, Patelli F, Codenotti M, et al. Optical coherence tomography in idiopathic epiretinal macular membrane surgery. *Eur J Ophthalmol* 1999; 9: 206-11.
16. Hillenkamp J, Saikia P, Gora F, et al. Macular function and morphology after peeling of idiopathic epiretinal membrane with and without the assistance of indocyanine green. *Br J Ophthalmol* 2005; 89: 437-43
17. Niwa T, Terasaki H, Kondo M, et al. Function and morphology of macula before and after removal of idiopathic epiretinal membrane. *Invest Ophthalmol Vis Sci* 2003; 44: 1652-6
18. Baumann M, Gentile RC, Liebmann JM, Ritch R. Reproducibility of retinal thickness measurements in normal eyes using optical coherence tomography. *Ophthalmic Surg Lasers* 1998; 29: 280-5
19. Chauman DS, Marshall J. The interpretation of optical coherence tomography images of the retina. *Invest Ophthalmol Vis Sci* 1999; 40: 2332-42
20. Puliafito CA, Hee MR, Lin CP, et al. Imaging of macular diseases with optical coherence tomography. *Ophthalmology* 1995; 102: 217-29.
21. Hee MR, Puliafito CA, Wong C, et al. Quantitative assessment of macular edema with optical coherence tomography. *Arch Ophthalmol* 1995; 113: 1019-29
22. Hee MR, Puliafito CA, Duker JS, et al. Tomography of diabetic macular edema with optical coherence tomography. *Ophthalmology* 1998; 105: 360-70
23. Massin P, Duguid G, Erginay A, et al. Optical coherence tomography for evaluating diabetic macular edema before and after vitrectomy. *Am J Ophthalmol* 2003; 135: 160-77.
24. Shaudig UH, Glaefke C, Scholz F, Richard G. Optical coherence tomography for retinal thickness measurement in diabetic patients without clinically significant macular edema. *Ophthalmic Surg Lasers* 2000; 31: 182-6
25. Theodossiadis P.G, Grigoropoulos V. G, et al. Evolution of idiopathic epiretinal membrane studied by optical coherence tomography. *European Journal Ophthalmology* 2008; 18: 980-988
27. Chan A, Duker JS. A standardized method for reporting changes in macular

- thickening using optical coherence tomography. Arch Ophthalmol 2005; 123: 939-43
39. Do DV, Cho M, Nguyen QD, et al. Impact of optical coherence tomography on surgical decision making for epiretinal membranes and vitreomacular traction. Retina 2007; 27: 552-6
 40. Crafoord S, Jemt M, Carlsson JO, et al. Long-term results of macular pucker surgery. Acta Ophthalmol Scand 1997; 75: 85-8
 41. Grewing R, Mester U. Results of surgery for epiretinal membranes and their recurrences. Br J Ophthalmol 1996; 80: 323-6
 42. McDonald HR, Verre WP, Aaberg TM. Surgical management of idiopathic epiretinal membranes. Ophthalmology 1986; 93: 978-83
 43. Michels RG. Vitreous surgery for macular pucker. Am J Ophthalmol 1981; 92:628-39
 44. Pesin SR, Olk RJ, Grand MG, et al. Vitrectomy for premacular fibroplasias. Prognostic factors, long-term follow-up, and time course of visual improvement. Ophthalmology 1991; 98: 1109-14
 45. Poliner LS, Olk RJ, Grand MG, et al. Surgical management of premacular fibroplasias. Arch Ophthalmol 1988; 106: 761-4
 46. Thompson JT. Epiretinal membrane removal in eyes with good visual acities. Retina 2005; 25: 875-82.

Associate Professor
P. G. Theodossiadis
2nd Department of Ophthalmology
University of Athens

ABSTRACT

Various techniques of retinography, fluorescein and ICG angiography, OCT, and ultrasound examination are used for the diagnosis and the monitoring of intraocular tumors.

1. Imaging of the fundus**Adult ocular oncology:**

Standard 60° retinography

Panoramic fundus photography (transillumination technique and laser scanning imaging)

Pediatric ocular oncology: Ret-Cam

2. Autofluorescence

Imaging technique, indications and contribution to differential diagnosis

3. Fluorescein angiography

Standard technique (30° to 60°) and panoramic (150° fluorescein angiography)

Semiology and contribution to differential diagnosis

4. ICG

Standard technique (30° to 60°) and panoramic (150°)

Semiology and contribution to differential diagnosis

5. OCT

Examination of the tumor surface and examination of the macula

Semiology and contribution to differential diagnosis

6. Ultrasonography**Posterior segment ultrasonography:**

A-Mode ultrasonography

10 and 20 MHz B-Mode ultrasonography

Examination of the anterior segment:

20 MHz immersion ultrasonography and 50 MHz ultrasound biomicroscopy (UBM)

L. Zografos, MD

Jules-Gonin Eye Hospital

European Association for Vision and Eye Research

EVER 2010
Crete Oct 6-9
www.ever.be

Join EVER!



EBO 2011
will take place in
Le Palais des Congrès,
Paris, on 6-7 May 2011

Application period
will commence from
1 October 2010 until
31 January 2011

For all further information log on to www.ebo-online.org



EUPO 2011

June 3-4, 2011

www.eupo.eu

GENEVA - Switzerland

Joint Congress of

SOE
AAO

4-7 June 2011

Geneva
Switzerland

For further information:

www.soe2011.org



European Society
of Ophthalmology



AMERICAN ACADEMY
OF OPHTHALMOLOGY
For the Eye Community

RETINA

Programme

Friday, October 1, 2010

15:00 Registration

Saturday, October 2, 2010

09:05 Introduction

09:15 **First morning session**

10:55 *Break*

11:30 **Second morning session**

13:10 *Lunch*

14:30 **First afternoon session**

16:10 *Break*

16:40 **Second afternoon session**

18:20 *End*

20:00 EUPO Party

Sunday, October 3, 2010

09:00 **First Morning session**

11:10 **Second morning session**

12:50 *End of session*

13:10 *Lunch*

Course Venue: Eugenides Foundation - 387, Sygrou Avenue P. Faliro - Athens, Greece